Markers of Intrauterine Stress:
Meconium and Nucleated Red Blood Cells

Theonia K Boyd, MD
Texas Children's Hospital
Baylor College of Medicine
Houston, TX

Disclosures

I do not have any relevant disclosures.

This presentation and/or comments will provide a balanced, non-promotional, and evidence-based approach to all diagnostic, therapeutic and/or research related content.

Cultural Linguistic Competency (CLC) & Implicit Bias (IB)

STATE LAW:

The California legislature has passed Assembly Bill (AB) 1195, which states that as of July 1, 2006, all Category 1 CME activities that relate to patient care must include a cultural diversity/linguistics component. It has also passed AB 241, which states that as of January 1, 2022, all continuing education courses for a physician and surgeon **must** contain curriculum that includes specified instruction in the understanding of implicit bias in medical treatment.

The cultural and linguistic competency (CLC) and implicit bias (IB) definitions reiterate how patients' diverse backgrounds may impact their access to care.

The following CLC & IB components will be addressed in this presentation:

- The lecture will address different diagnostic approaches across different and culturally diverse patient population
- The lecture will address how the new classification can be applied to the populations in resource poor regions

Hermann Hospital, site of future Texas Medical Center, ca. 1925

Texas Medical Center:

- 2.1 mi^2
- 61 institutions
- 4 medical schools
- ~10M pt visits/yr

Placental Evaluation

Markers of intrauterine stress

- Released in response to the onset of stress
- Lag time between onset and release
  - NRBCs = ~ 1 hour
    - Quick release mediated by adrenal hormones
    - More prolonged release/production mediated by erythropoietin
  - Meconium = hours
    - Greater specificity not elucidated

Timing of intrauterine stress

- When stress began
- How long it lasted before delivery/demise
- Indirect assessment of stress severity

Placental Evaluation

Mechanisms of intrauterine stress

- Hypoxia (placental > uterine > fetal)
- Infection (ascending > hematogenous)
  - Hypoxia is a more robust stimulus than infection
- Metabolic (maternal > fetal)
- ~~Mechanical~~

Caveats:

- Meconium is not always passed
- NRBCs may not be present in acute catastrophic hypoxic events
- Cannot be used to time injury!

Timing of Intrauterine Stress: Placental Markers

Nucleated red blood cells

- Number reflects both duration and intensity
- Postnatal decline roughly mirrors antenatal onset
- Relative vs. absolute nrbcs



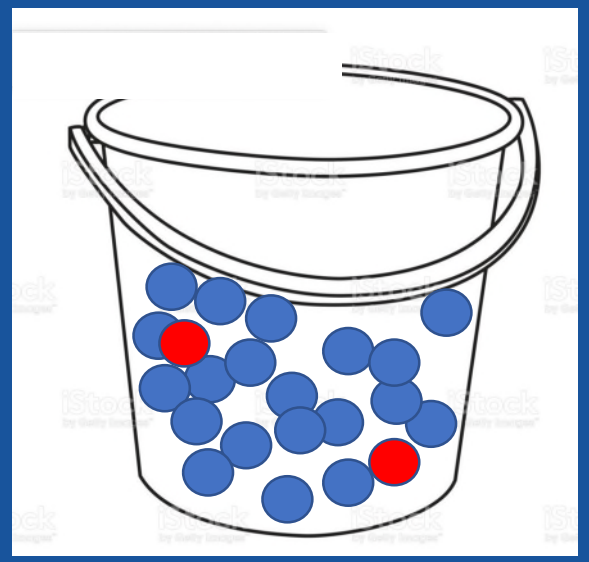

Red balls = nrbcs
White balls = wbcs

Relative ratio
red:blue per bucket 1:10

Absolute difference
between buckets 1:2

NRBCs

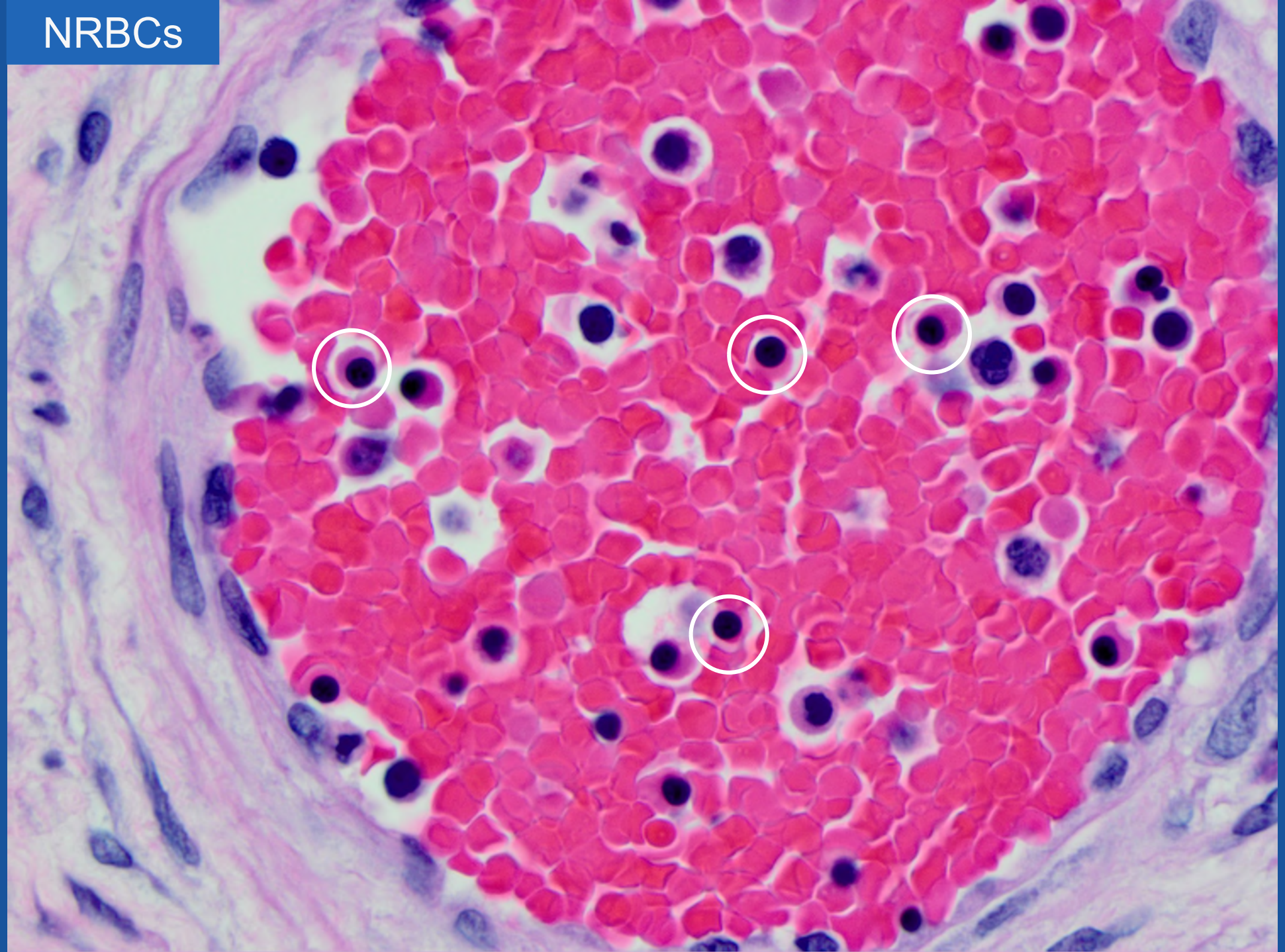

NRBCs with “left shift”

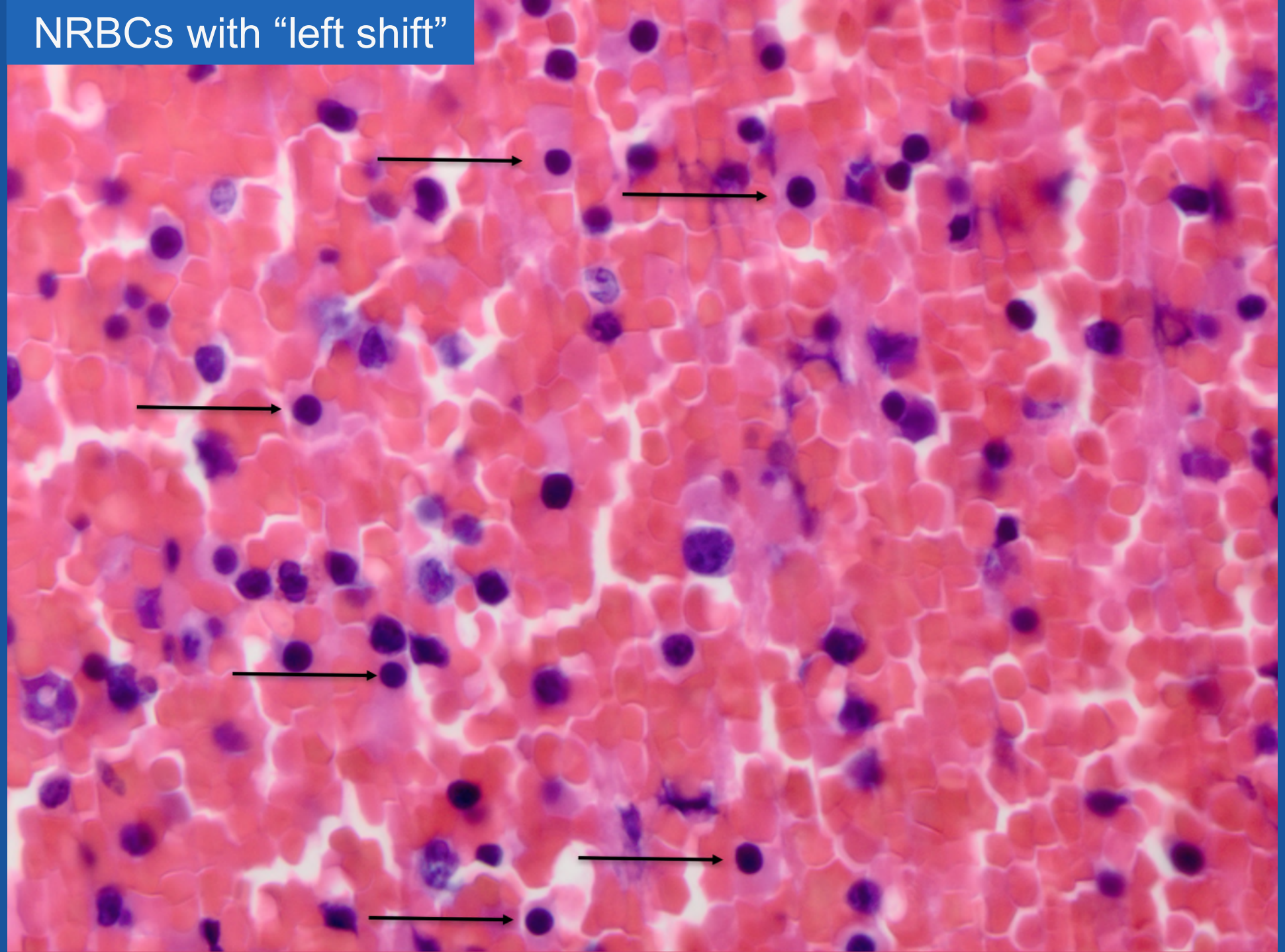

Timing of Intrauterine Stress: Placental Markers

Meconium

Gross:

Color reflects duration between discharge and delivery

Microscopic:

Depth reflects duration between discharge and delivery

Density reflects thickness, a surrogate for intensity

"Two factor authentication" that brown pigment = meconium

- Clinical history
- Gross placenta discoloration
- Particulate meconium

Fresh meconium

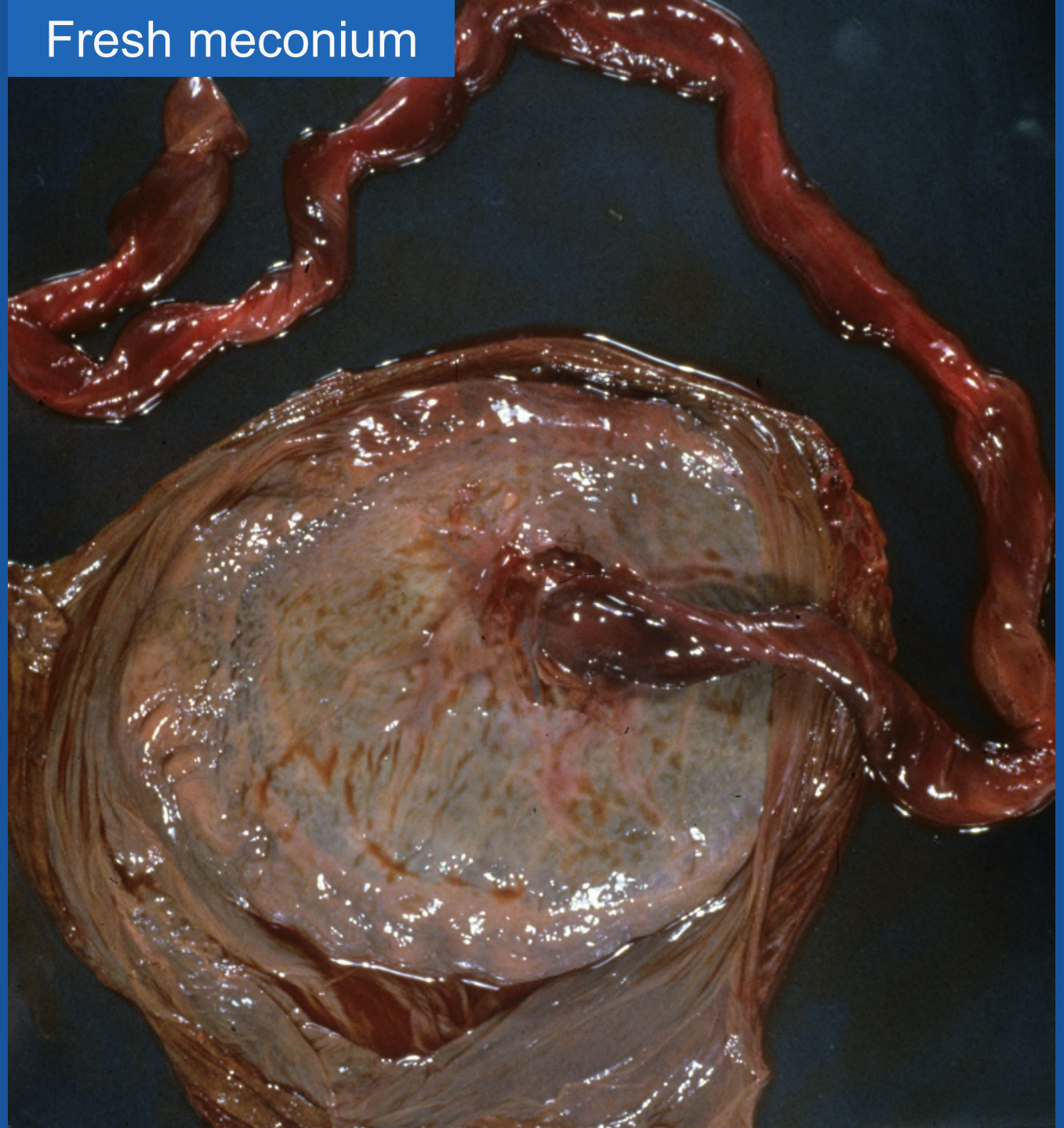

Older meconium

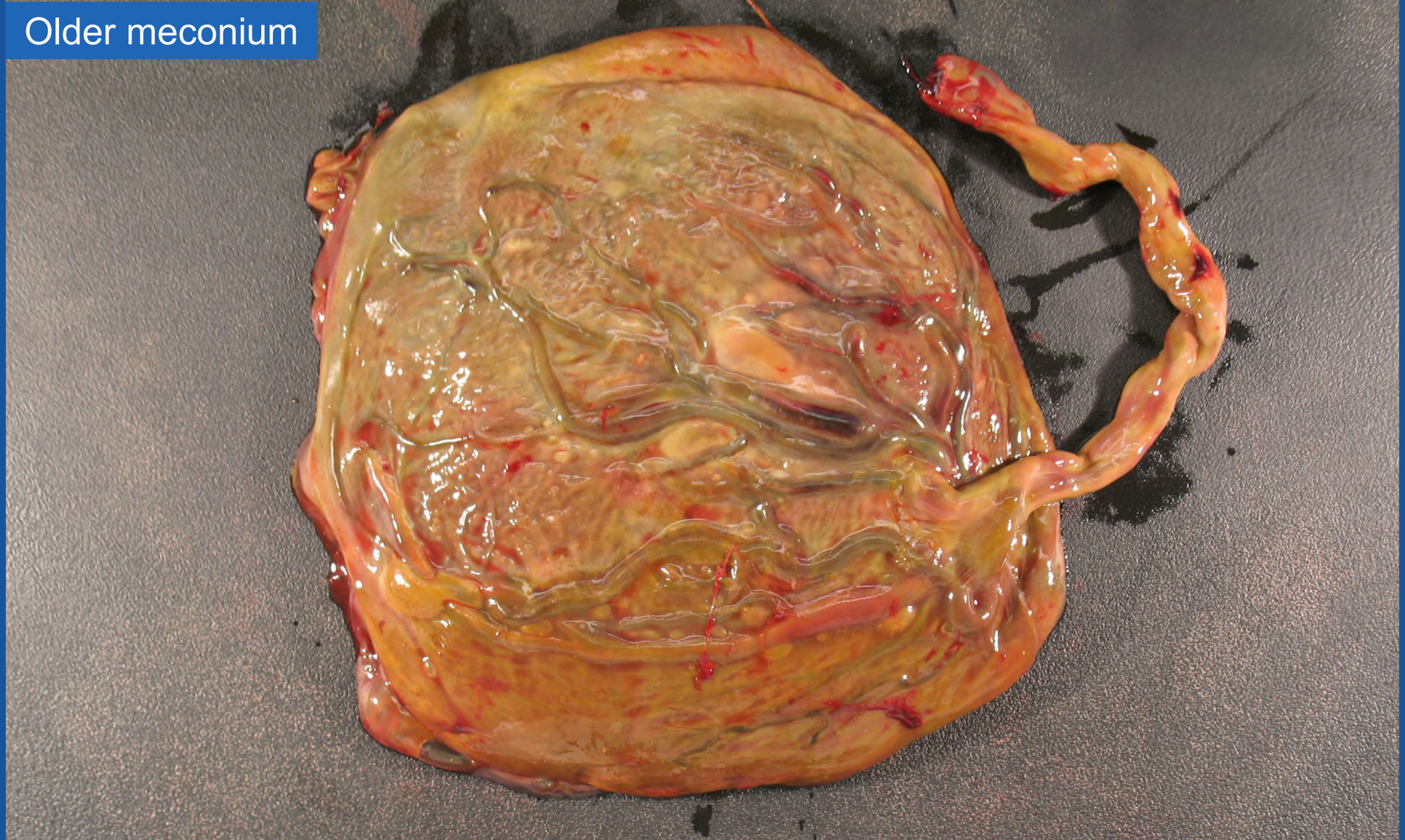

Particulate meconium

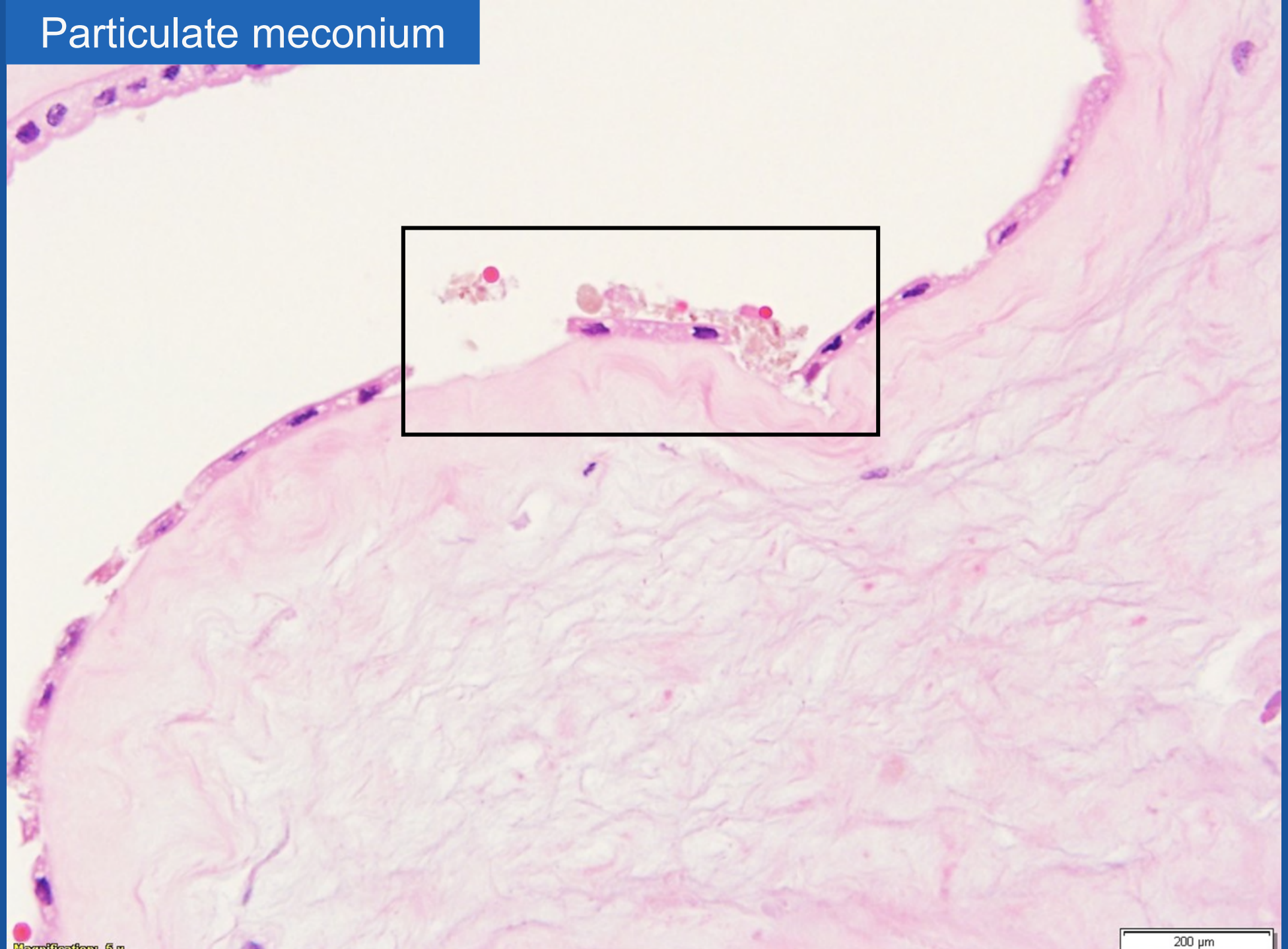

Admixed particulate meconium

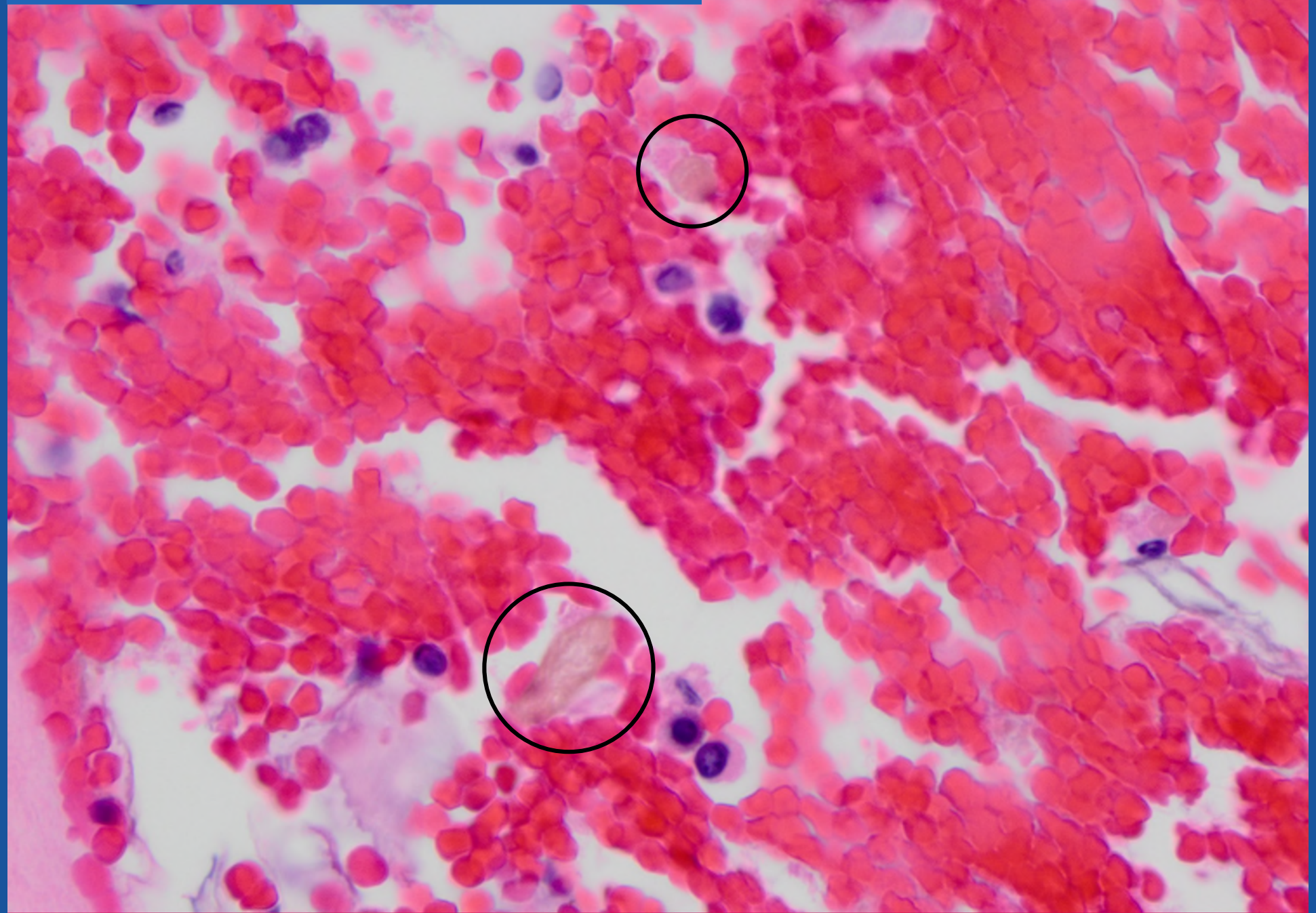

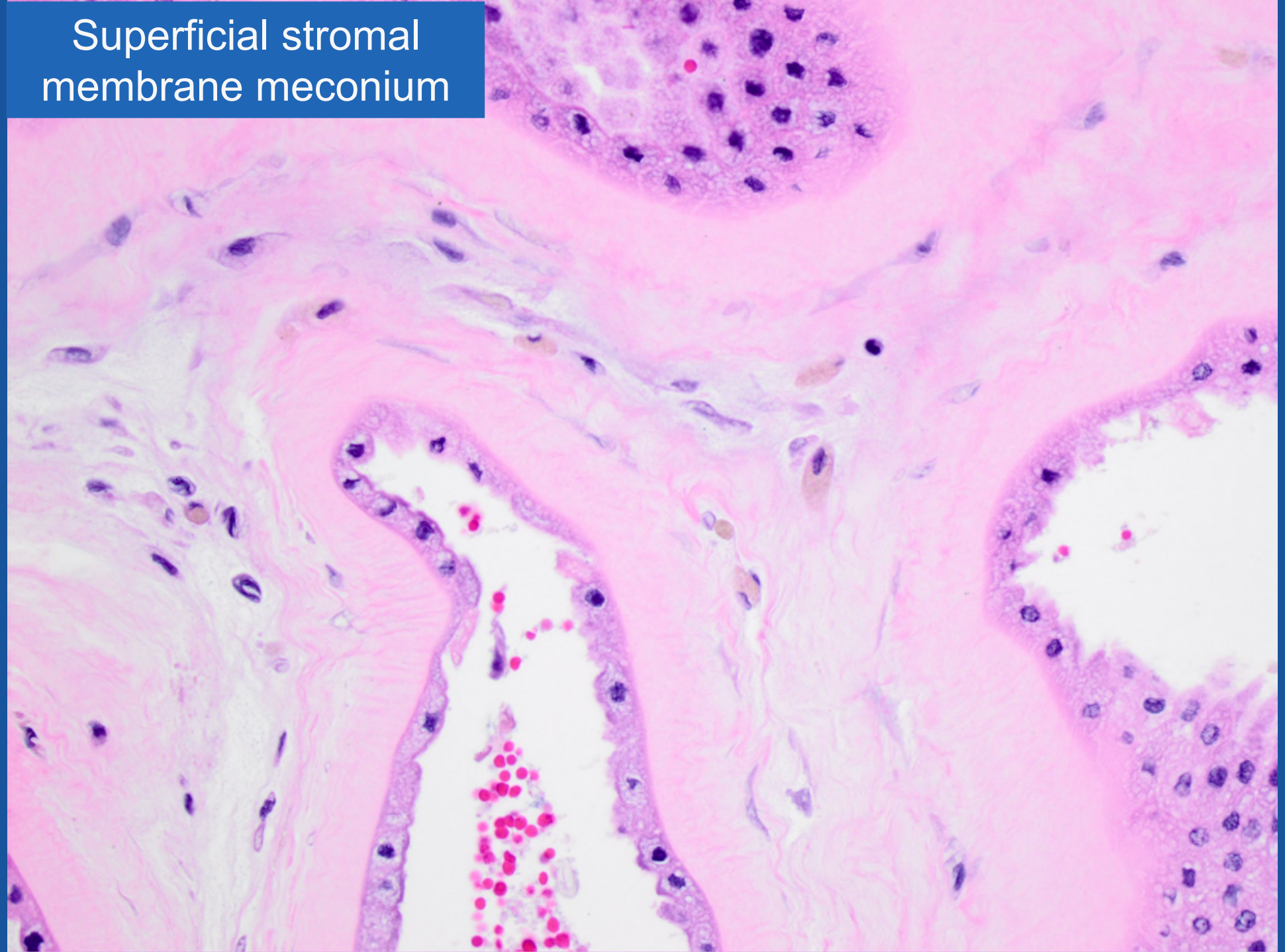
Superficial stromal membrane meconium

Deeper decidual membrane meconium
Note “bubbly” lysosomal uptake

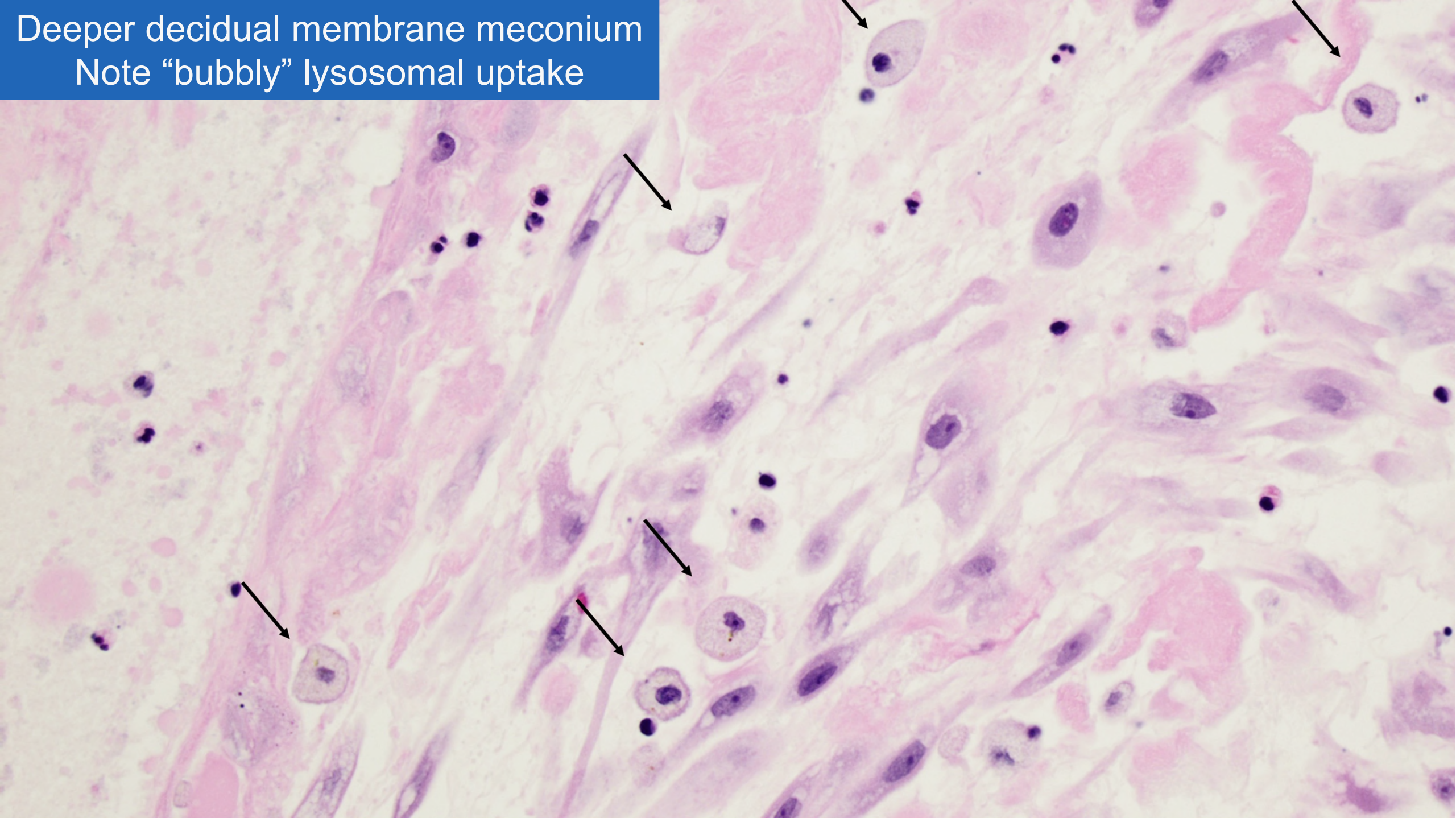

Meconium myonecrosis

- Definition: Pyknosis of umbilical and/or chorionic myocytes
  - Due to chemical necrosis from bile acids
  - Result of prolonged meconium discharge prior to delivery
  - Effect: Compound
    - Intrauterine stressor(s) elicit prolonged and continued meconium discharge
    - Altered fetal vascular tone, presumably compromising optimal placental-to-fetal blood (O_2) flow, produce superimposed hypoxia

- Pattern:
  - Affects fetal myocytes closest to amniotic fluid
  - Often with admixed meconium macrophages
  - Can elicit fetal vasculitis

- Associations with untoward fetal/neonatal outcome:
  - Stillbirth
  - Neurodisability

*Redline RW. Severe fetal placental vascular lesions in term infants with neurologic impairment. Am J Obstet Gynecol. 2005;192(2):452-7.

Meconium myonecrosis

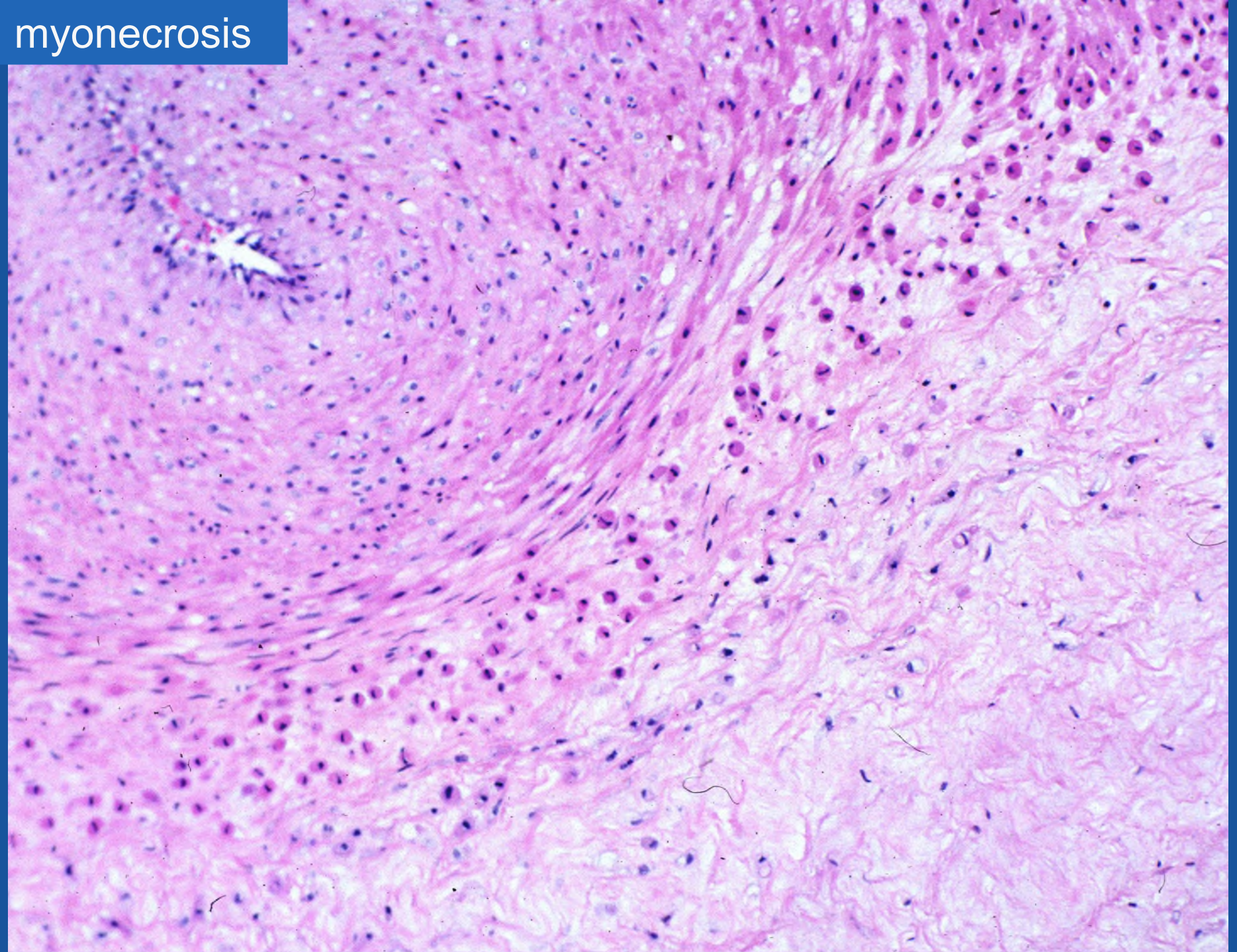

Meconium myonecrosis with fetal vasculitis

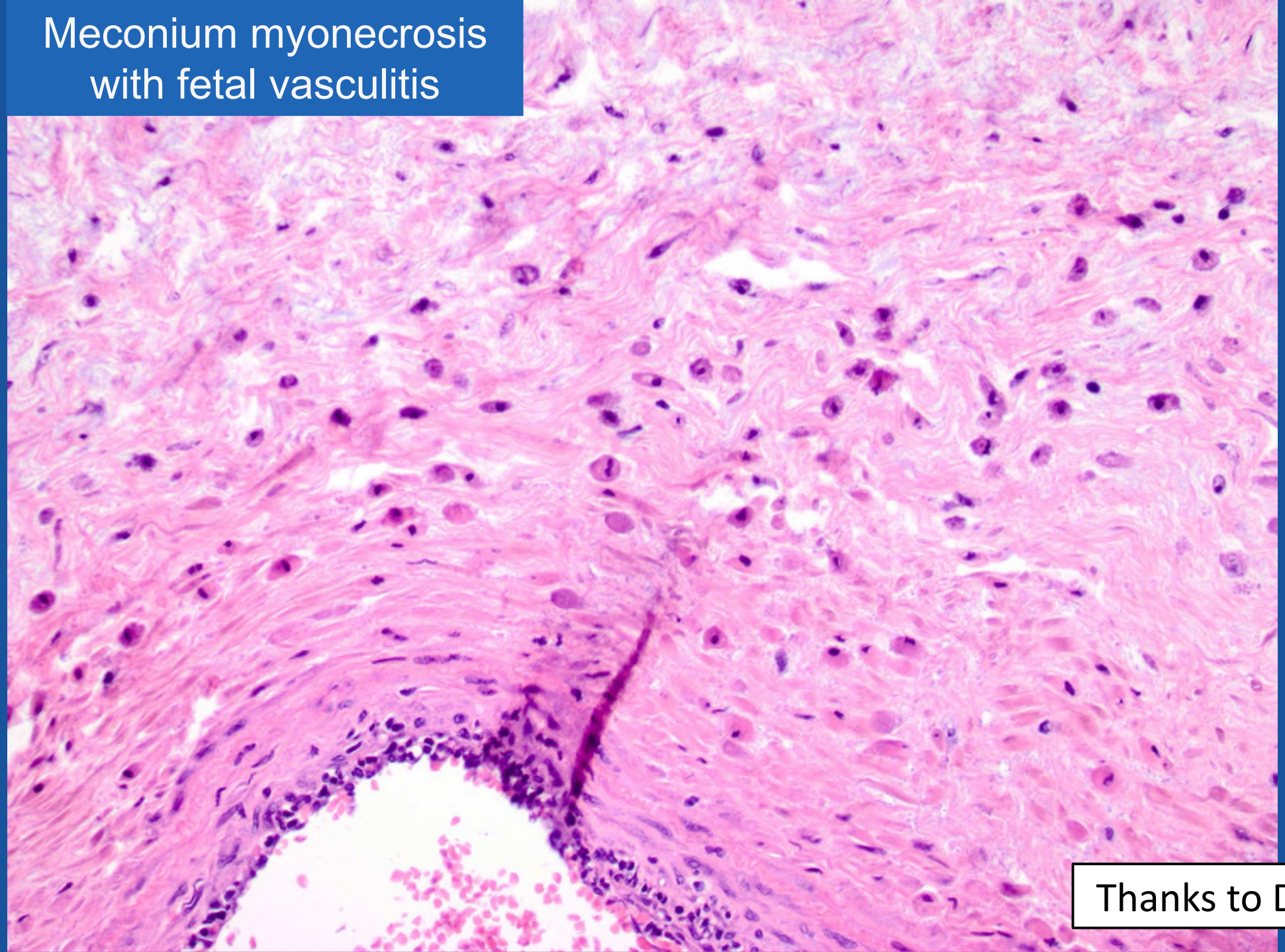

Thanks to Drucilla R

Meconium myonecrosis with loss of nuclear basophilia

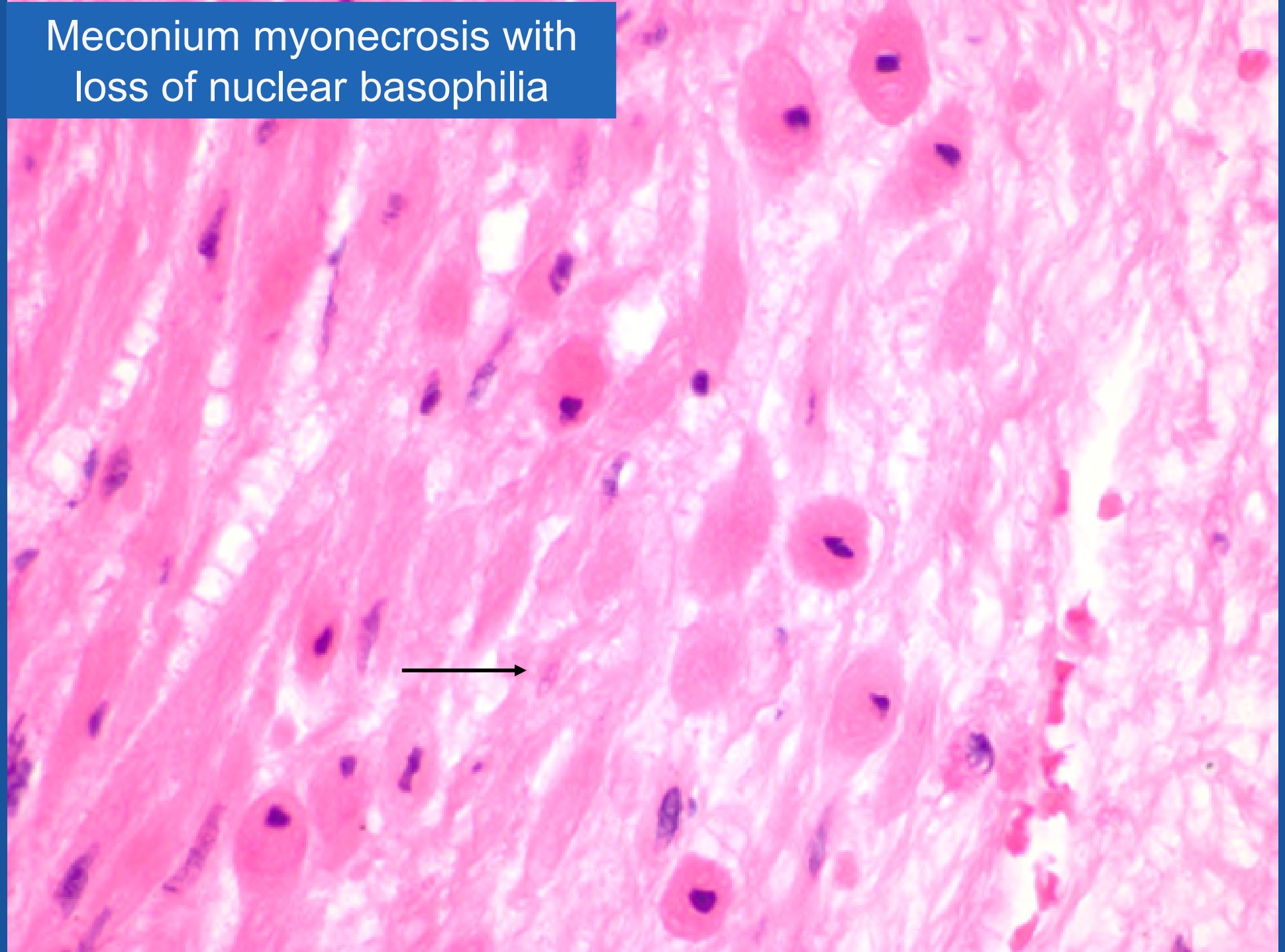

Meconium myonecrosis with meconium macrophage

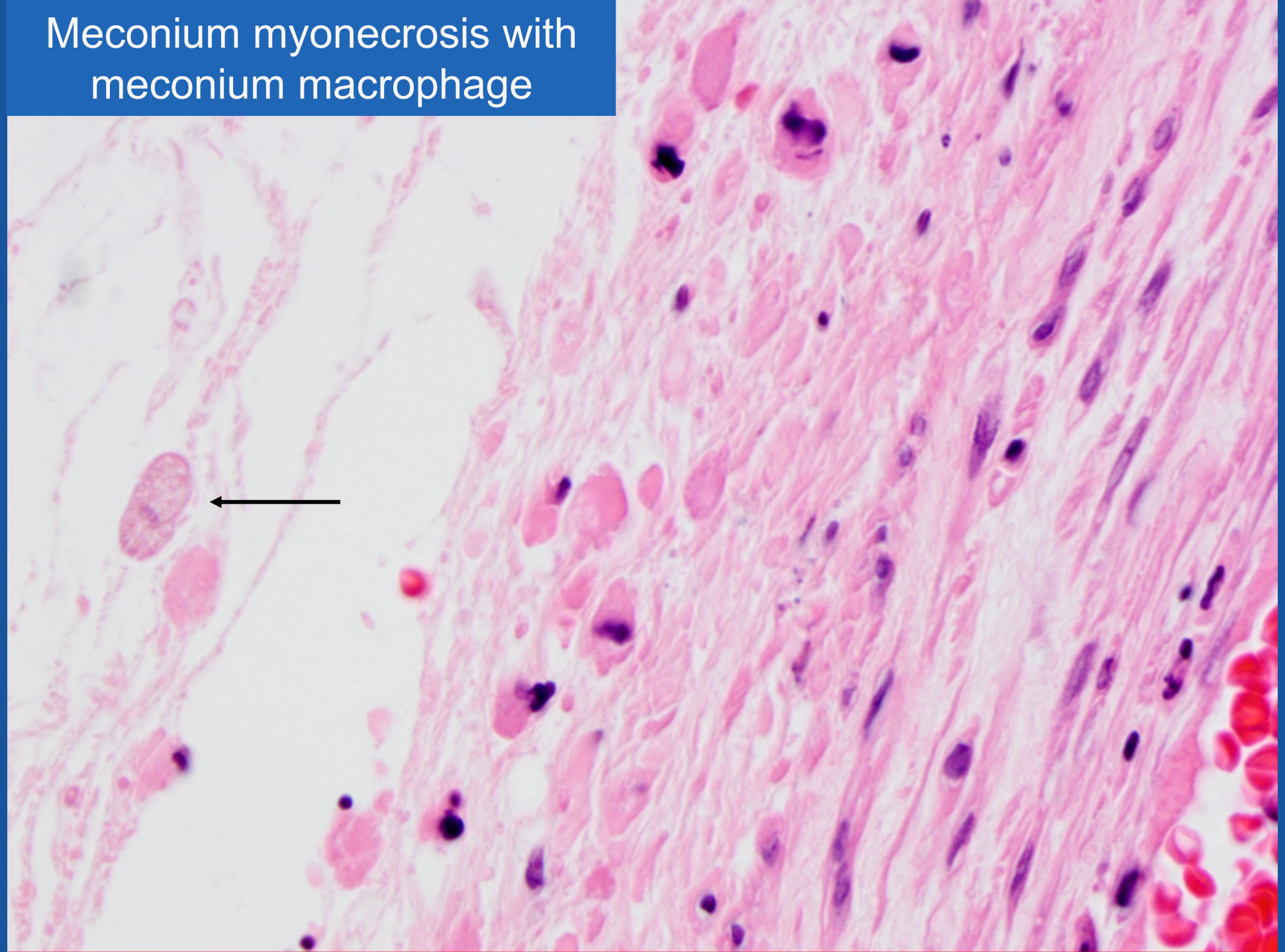

Meconium myonecrosis: ? Mechanism(s) of injury

- Altered placental vascular tone
- Cytokines with meconium vasculitis
- Superimposed effect on primary process(es)
- Umbilical cord ulceration with vessel rupture (mega-rare)

Autopsy correlations:

Chronicity of meconium discharge

- Meconium aspiration
- Meconium ingestion
- Meconium pneumonitis

NRBC correlates

- Left shift (infection)
- Erythroblastosis
- Extramedullary hematopoiesis


0
1
2
CM
3
4
BWH Pathology


0 1 2 CM 3 4
BWH Pathology

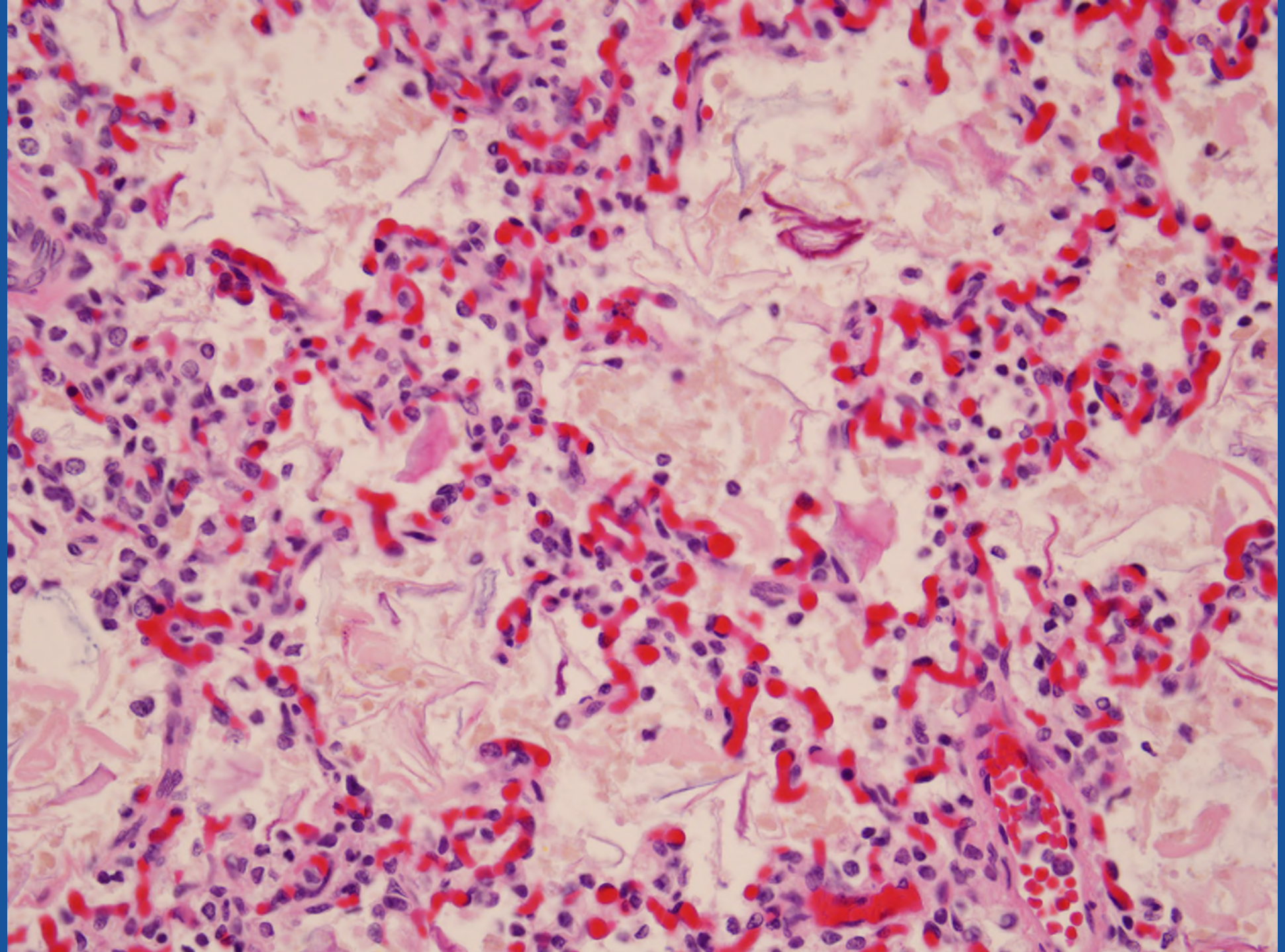

Autopsy correlations:

Additional markers of extent and intensity of antemortem stress

- Thymic involution
  - Acute: starry sky cortical changes
  - Subacute: Cortical thinning
  - [Chronic: Atrophy; Hassall's corpuscles mineralization/cystification]

- Adrenal changes:
  - Acute: Definitive cortex corticolysis
  - Subacute: Fetal cortex lipidization
  - [Chronic: Medullary ablation]

[ ] = Postnatal

Acute thymic involution: Cortical thymocyte apoptosis

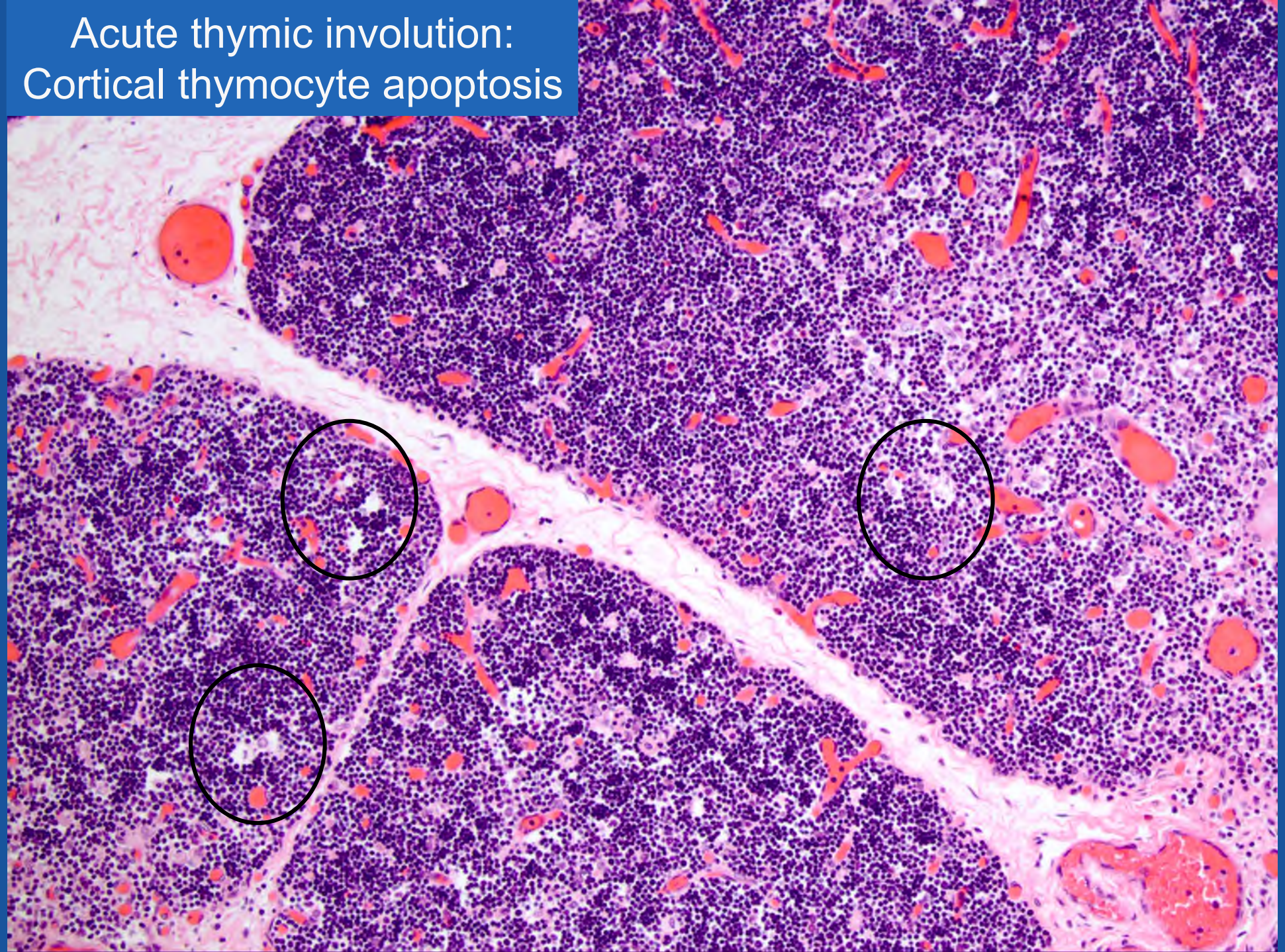

Subacute thymic involution: Cortical volume depletion

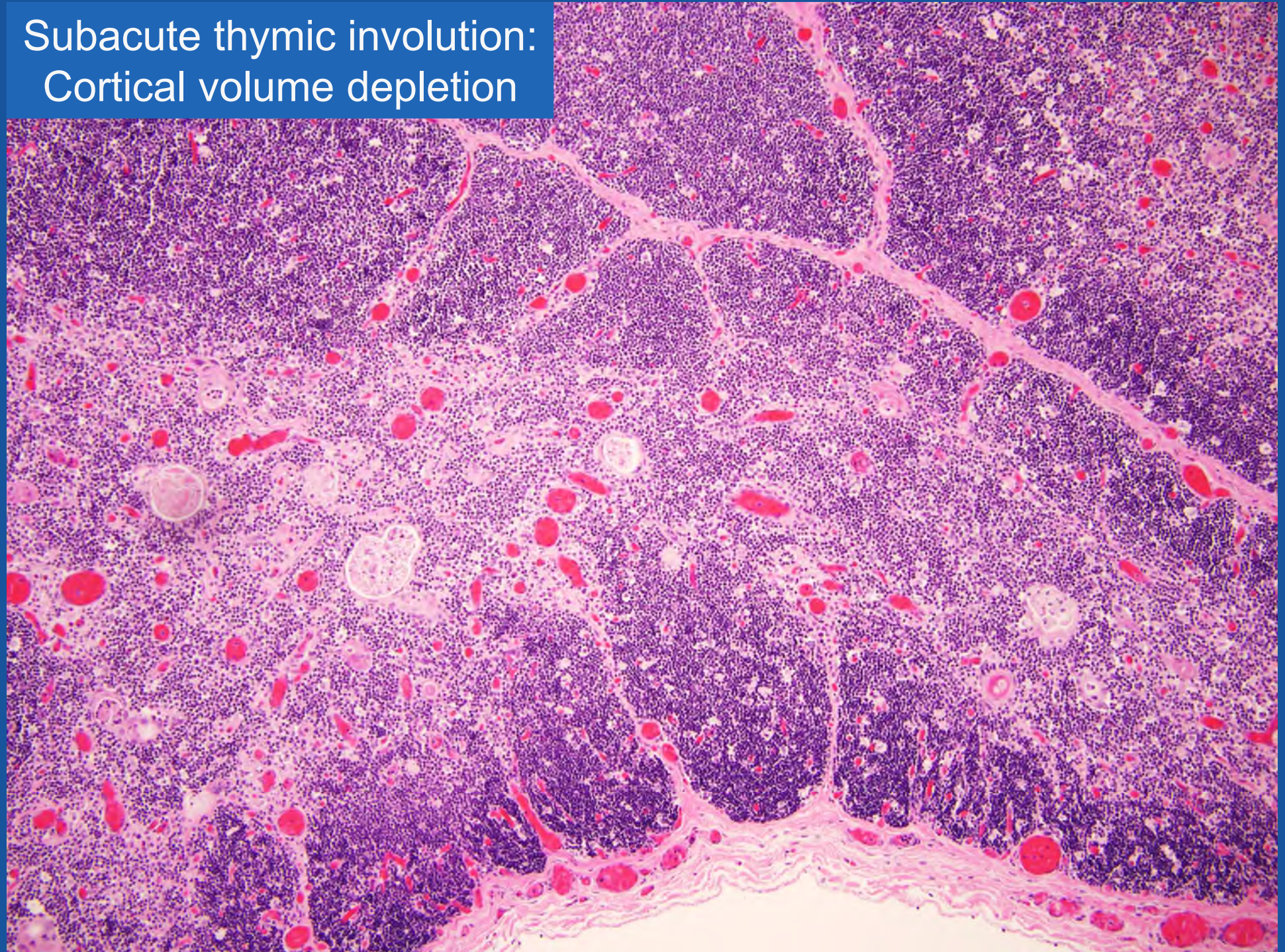

Acute adrenal cortical involution: Definitive cortex cytolysis

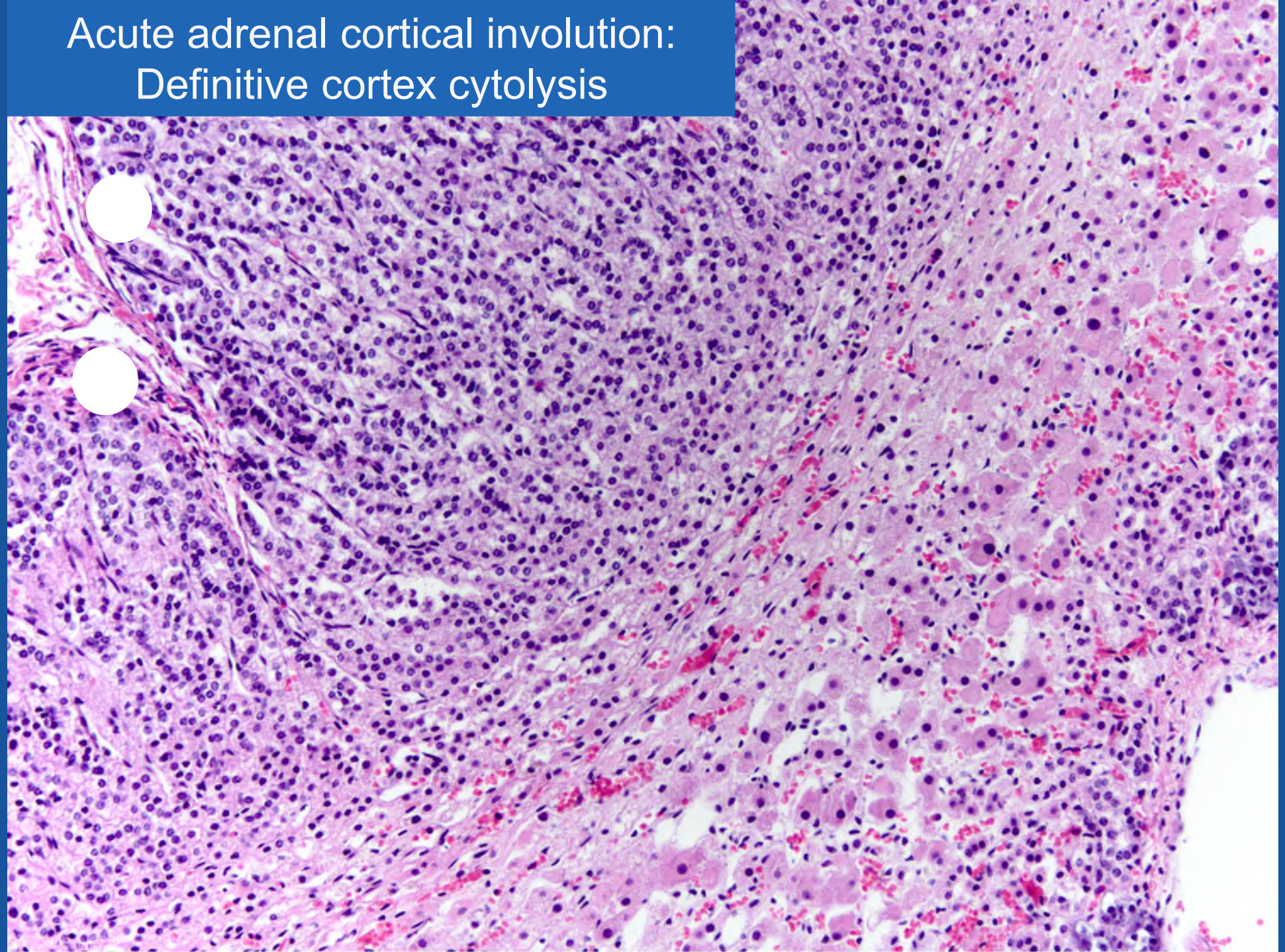

Subacute adrenal involution: Fetal cortex lipidization

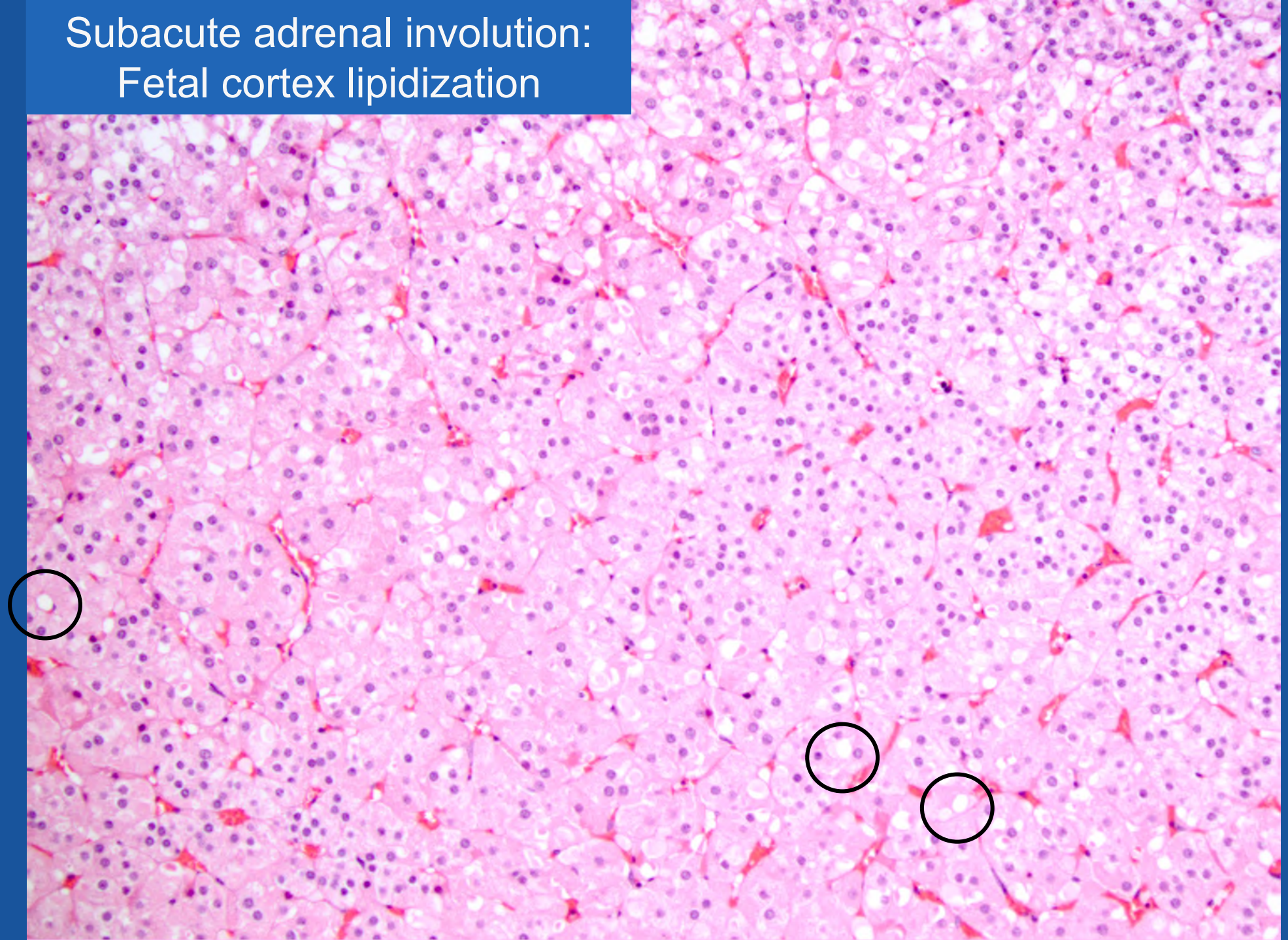

Placental Evaluation: Take Home Points

1. Stress is not equivalent to injury

2. Injury cannot be timed from placental evaluation
3. Exceptions: a. Acute catastrophic events

   b. Silent stillbirth

Selected references

Nucleated red blood cells

1. Cohen MC, Boyd TK. (2019) Chapter 26: Presence of nucleated red blood cells. In: Pathology of the placenta. Springer Publishing Co. *See references*
2. Boyd TK. (2018) Chapter 20: Increased circulating fetal nucleated red blood cells. In: *Placental and Gestational Pathology*. Cambridge University Press. *See references*

Meconium

1. Boyd TK. (2018) Chapter 19: Meconium effects. In: *Placental and Gestational Pathology*. Cambridge University Press. *See references*

General

1. Boyd TK, Parast MM, Horii M, Tantbirojn P. (2018) Chapter 32: Placental Correlates of Unanticipated Fetal Death. In: *Diagnostic Obstetric and Gynecologic Pathology*. Saunders Publishing Co. *See references*
2. Meserve EE, Sirois KF, Parast MM, Boyd TK. (2018) Chapter 31: Evaluation of the Placenta. In: *Diagnostic Obstetric and Gynecologic Pathology*. Saunders Publishing Co. *See references*

TEXAS CHILDREN'S PATHOLOGY FACULTY (54) ALL SUBSPECIALTIES