EXTENDED EWING FAMILY TUMORS (EEFTs)

STEPWISE APPROACH

TO

DIAGNOSIS

VIJAY V JOSHI, MD, PhD, FRCPath

CONSULTANT

IN PEDIATRIC PATHOLOGY

EEFTs: Grateful Acknowledgement

- Thanks for providing articles, data, photos and for sharing cases to : Drs S Smith, L Wang, S Ranganathan, V Kumar, F Balarezo, B Bagci, S Moradi, Jayalakshmy and to
- Dr Nat Pernick and his colleagues at Pathology Outlines and to
- All the authors of review and focused articles on EEFTs and of other online materials.

- AIPNA FOR SPONSORING THE WEBINAR

PLAN OF PRESENTATION:Part A and Part B

.History of Ewing Sarcoma Family (ESF)

.New ‘members’/entities of Extended Family recognized by NGS,Nomenclature

.Stepwise Approach (clinico-histologic & ICC profiles & genetic markers) to Dx of EEFTs (original & recent references)

.Biologic relevance of genetic markers

Summary

James Ewing, MD (1866-1943) – Prof of Pathology, MSKCC, NY (Hemangioendothelioma – 1921)

AP Stout, MD(1885-1967), Columbia Univ. NY,Peripheral Neuroepithelioma 1918

EEFTs: Evolution of Nomenclature (1918/21,1942,1967,1975,1979)

Characterization by ROUTINE HOSTOLOGY

.HEMANGIOENDOTHELIOMA of bone (1921) = EWING'(S) SARCOMA (ES).

.NEUROEPITHELIOMA (1918)(ulnar nerve) (Stout) =(Peripheral)Primitive NeuroEctodermal Tumor (PNET)

.MALIGNANT SRCT of thoraco-pulmonary region (ASKIN tumor) (Askin 1979)

.Similarity in Histology & ICC (diffuse membranous CD99) & genetic marker (EWS-FLI1 gene fusion)

Ewing's Sarcoma Family of Tumors: ES, PNET, Askin Tumor (Khoury 2005)

EEFTs: Evolution of Nomenclature (1918/21,1942,1967,1975,1979)

.REFERENCES

Stout AP Proc NY Path Soc 1918; 18:2

Ewing J Proc NY Path Soc 1921:21:17;

Stout AP Am J Roentgenol 1943;53:334

Seemayer T. Persp. Pediat. Pathol 1975;2:151

Askin F Cancer 1979,.43:2438)

Evolution of Nomenclature &Genetic Markers of ES and PNET (References)

- Khoury J Adv Anat Pathol 2005;12:212

Ambrose IM Cancer 1991;67:1986; Dellatre O Nature 1992;359:95;

Downing JR Amer J Pathol 1993;143:1294,

Kumar S. Hum Pathol 1999;30:324,

Marina NM. Cancer 1989;64:1954,

Jaffe R AJSP 1984;8:885,

Carazzana AO Am J Pathol 1987;627:507)

Evolution of Nomenclature ES and PNET (Cont'd)

ES,PNET: ES/PNET (Askin Tumor merged with PNET)

Current trend: ES (PNET is deleted from designation and two basic subsets of ES not designated separately by Surgical Pathologists dealing with tumors in adults)

Personal choice/experience: ES with/out neural differentiation(Schmidt D Cancer 1991;68:2251)

(Rationale: Look for rosettes in distorted or intact form in core biopsy to get a clue for working Dx of ES)

Antonescu C Histopathology 2014;64:26:A-typical ES B lobules/rosettes D-FLI1

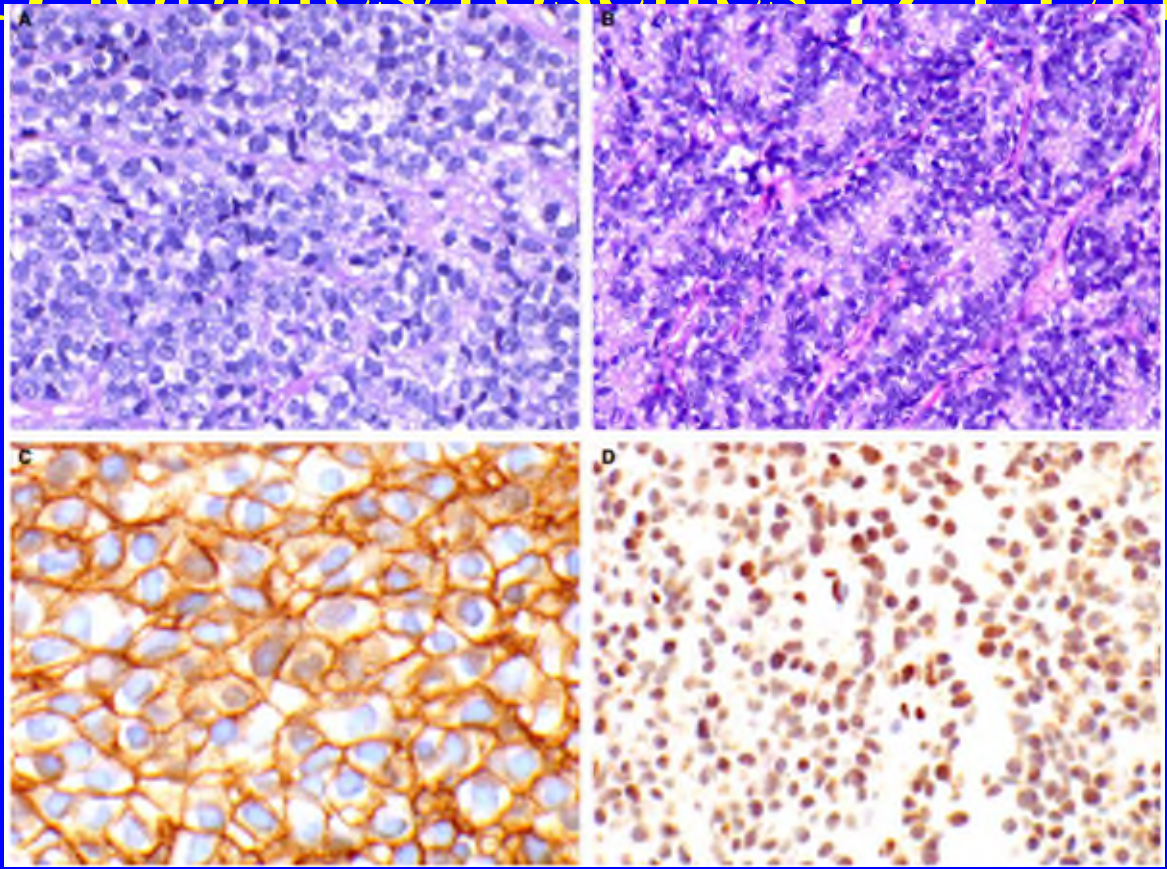

Ewing Sarcoma Family of Tumors to Extended Ewing family Tumors

- New entities with new gene fusions recognized by Next Generation Sequencing added to ES Family

Extended Ewing Family Tumors (ES as prototype/Head of the family) - Designation chosen for this presentation

Criteria for Inclusion of Entities in EEFTs

- A. SRCT with/out spindle cell component
- B. Absence of differentiation by histology, EM & ICC (Exception: ES showing neural differentiation in some cases)
- C. Fusion between FET-ETS (e.g. EWS-FLI1) gene family members or between FET-non ETS members (e.g. EWS-NFATC2, EWS-WT1)
- (Undiff RC Tumors showing fusion between two genes other than ones in C above, BCOR & CIC Rearrgd sarc, considered as distinct entities but included in Extended EFTs for this presentation)

Established & Evolving entities (NGS) (Davis 2020)-Genetic markers of EEFTs

- 1.ES(EWS-FLI1/other):(2-60+, Med 15yrs)
- 2.EWS-NAFTC2(12-70,32);PATZ1(1-81,42)
- 3.D-SRCT(EWS-WT1): (2-60+, 22)
- 4.BCOR Reargd: CCNB3 fusion sarcomas (2-44,15), BCOR-ITD (0-15,1);CCSK in children
- 5.CIC-DUX4/other sarcomas(5-80,32)
  (6.Undiff sarcomas:no distinctive gene marker)

EEFTs:Approach to Diagnosis

.Diagnostic work-up : Resource intensive - wide range of ICC stains and of tests for molecular makers

Referral to centers with expertise & resources

.Attempt at global perspective: Histologic and ICC profiles for targeted ICC stains and molecular genetic tests to reduce costs

EEFTs:Global health perspective (ASCO Educational Book 2018) Florou V p 916-924

- Resource challenges: developing countries
- Limited tools (range of ICC Antibodies , methods for molecular genetic markers)
- Prohibitive costs of clinical/pathology tests: Targeted approach to diagnostic work-up to reduce costs
- Only FNAB may be feasible: Can be triaged for ICC & genetic markers

Sets of SRCTs- DD:Established Entities with evidence of differentiation vs EEFTs

- EEFTs BASICALLY BELONG TO THE BROAD GROUP OF SRCTs IN CHILDREN (& ADULTS)
- Two sets in this broad group of SRCTs:

- A. Established SRCTs with demonstrable line of differentiation by histology/EM/ICC/Flow cytometry (Three subsets)
- B. EEFTs: Undifferentiated SRCTs (Exception: Subtype of ES showing neural differentiation)

Sets of SRCTs- DD:Established Entities with evidence of differentiation vs EEFTs

- Subsets of Established SRCTs
- 1. Conventional spectrum: NB, RMS, NHL;
- 2. SRC variants of tumors: Osteosarcoma,Syn Sarc, MPNST, Blastemal-WT, Hepatoblastoma;
- 3. Biphasic sarcomas with SRC component (only SRC component may be seen in core Bx) (e.g. Mesenchymal & Myxoid chondrosarcoma, Myxoid Liposarcoma)
- (Rarely : Germinoma, Granulocytic sarcoma, Nasopharyngeal carcinoma, Inflamm myofibr tumor)

DIAGNOSIS OF EEFTs: FIRST STEP

- R/O by stepwise approach all subsets of established SRCTs with demonstrable line of differentiation by different methods (EM,ICC):

- Main established entities in DD of ES:

.NB (UD) (viscera),

.Embryonal RMS,dense pattern variant (Soft Tissue),

.Alveolar RMS,solid variant (ST),

.Lymphoblastic CD45-ve,CD99+ve NHL

.SRC variant of osteosarcoma (bone)

EEFTs: Approach to Dx –First Step – Assumption for this presentation

- All aforementioned entities in subsets of Established Pediatric/Adult SRCTs

Ruled out by stepwise approach

EEFTs:Approach to Dx

- Current trend: Needle Bx (4-5 cores):
- Bx preferable from soft tissue extension of bone tumor (decalcified tissue unsuitable for NGS)
- Small but 'adequate' sample: 91% rate of accuracy reported in 233 cases (Clinical advantages: no anaesthesia, reduced morbidity & complication rate – Adam S Clin Orthop Relat Res 2010;468:2474)

EEFTs:Next Genern Sequencing Research & Diagnostic Method

- Fresh frozen tumor from one of the cores
- FFPE tissue:Block/10 unstained slides: five micron sections
- FNA/cytology smears: preferably 5 K tumor cells (3-10 ng of DNA)
- Sections - at least 20% tumor nuclei (insufficient cells due to excessive stroma of tumor/surrounding tissue-ES: little stroma, Non-ES more stroma)

EEFTs:Approach to Dx-NGS

- Type of sample for whole genome vs targeted NGS

- High mol weight DNA from fresh tissue required for whole genome sequencing
- Low mol weight DNA from FFPE tissue (unrecycled buffered neutral formalin) acceptable for targeted sequencing

EEFTs:Approach to Dx (Evolving field)

- Twelve-year old White-American boy with a large mass of mid-shaft of femur/soft tissue of chest wall
- Size & other imaging features, lab data (LDH,CBC etc.) suspicious for malignancy
- Needle core biopsies (4-5 fragments)
- Histology: SRC + spindle cell component
- Assumption: established SRCTs ruled out
- DD ONLY BETWEEN EEFTs

Core Bx: Undifferentiated round cell & spindle cell morphology

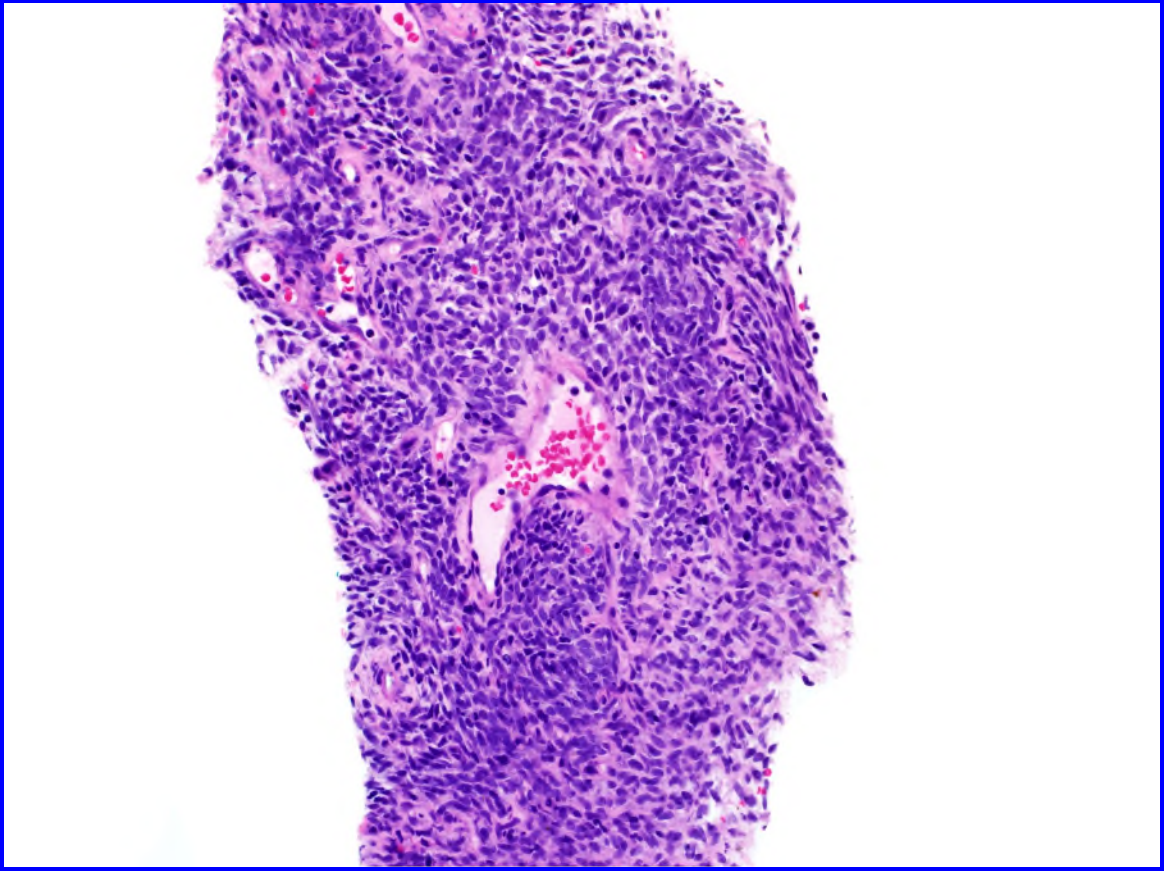

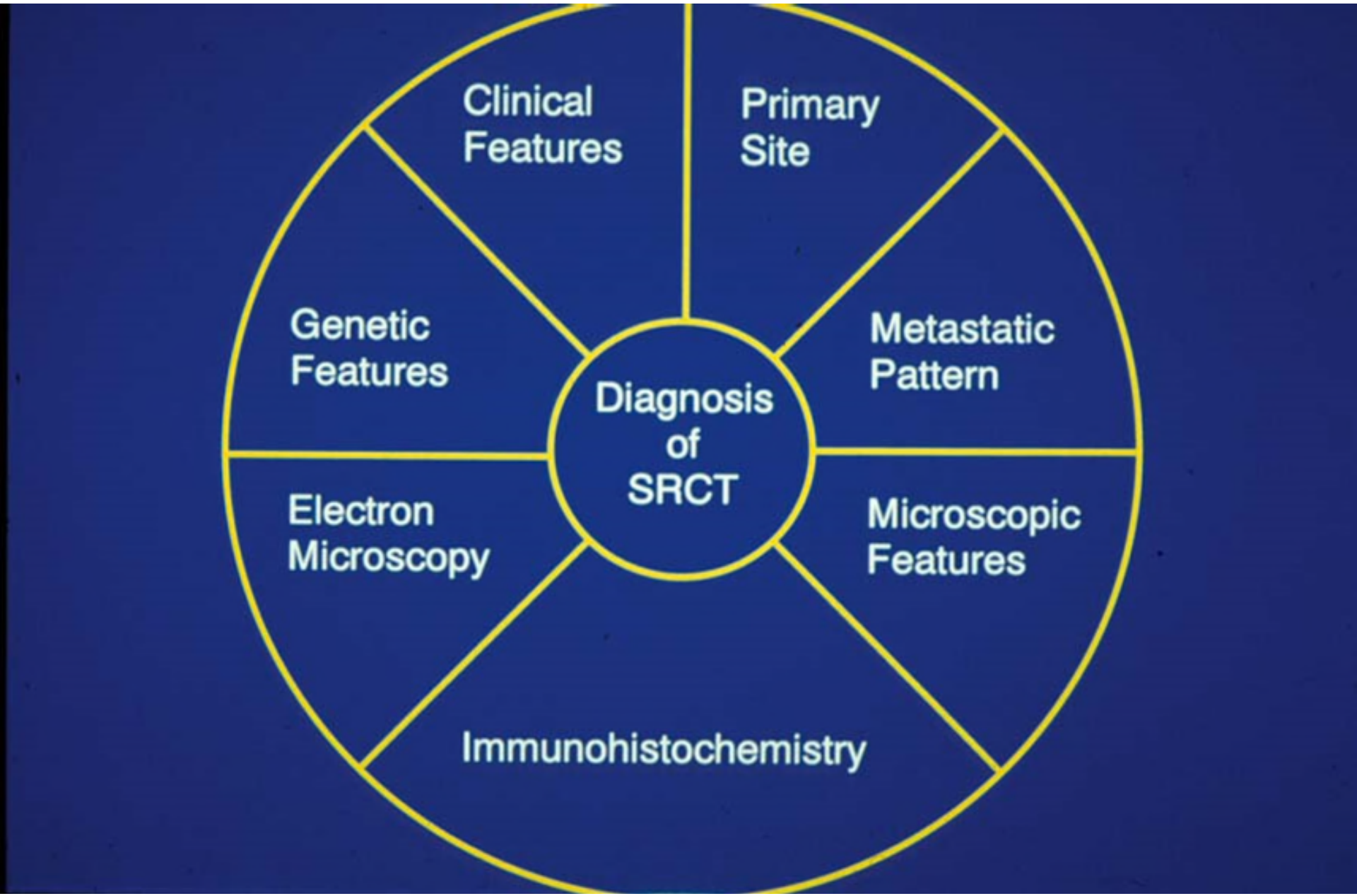
Clinical Features
Primary Site
Genetic Features
Metastatic Pattern
Diagnosis of SRCT
Electron Microscopy
Microscopic Features
Immunohistochemistry

EEFTs (emphasis on stepwise approach to diagnosis)

Emphasis on working Dx: clues from

.Clinical features, imaging studies, lab data

.Routine histology,

.(EM: optional, science for the sake of science)

.ICC profile

Definitive Dx (confirmation of working Dx) by

Molecular genetic marker(FISH,RT-PCR,NGS)

(Joshi VV et al Pathol Case Rev 2000;5:26)

EEFTs:Stepwise approach to Dx of EEFTs

- Construct clinicohistologic profile:Clues to a working diagnosis
- Request from wide panel, focused ICC stains useful for strengthening working Dx
- Targeted test(s) (RT-PCR,FISH,NGS) for genetic marker to confirm working Dx
- Focused/targeted tests for reducing costs and turn around time in resource-challenged institutions or even resource rich ones

EEFTs:Different Entities

- 1.ES:FET-ETS family gene fusion sarcoma
- 2.FET-Non ETS family gene fusion: EWS-NFATC2 fusion & EWS-PATZ1 fusion RCS
- 3.D-SRCT: EWS-WT1 fusion sarcoma
- 4.BCOR-CCNB3 or BCOR-ITD sarcomas e.g. Primitive Myxoid Mesenchymal Tumor of Infancy (PMMTI) & 3 other subsets
- 5.CIC-DUX4 (or other gene) fusion sarcomas
- (6.Undifferentiated (unclassified) sarcomas)

EEFTs:Dx-Clues from step 1:clinical features(Riggi 2021)

- Age, Sex, Race, Primary site, Metastatic pattern
- AGE:
- Neonate or Infant: PMMTI (subset of BCOR sarcoma),
- Young child: BCOR sarcoma of kidney
- Older child: ES (peaks at 15 yrs)
- (Any tumor at any age:Cong ES-Saito Y Pediatr Blood Cancer 2008;51:698)

EEFTs:Dx-Clues from clinical features(Riggi 2021)

- Sex:

BCOR sarcoma - M:F-6:1

EWS-NFATC2 RCS – M:F-5:1

(Davis 2020)

EEFTs:Dx-Clues from clinical features(Riggi 2021)

- Race:

ES ~10X more common in Whites than in Blacks (<EWS-FLI1 transcriptional activity in Blacks)

(ES occurs in Eastern countries: ES comprises ~15% of bone cancer in India Chakraborty D J Bone Oncology2018;12: 49)

EEFTs:Dx (Clues from Primary site in children)

- Bone>SoftTissue:

ES (metaphysis) (ES of ST > common in adults), EWS/FUS-NFATC2 & EWS-PATZ1 fusion sarcomas

- ST>Bone: BCOR-CCNB3 & BCOR-ITD sarcoma
- ST:CIC rearrgd (5% in bone-Carter 2019)
- Abdomen-Pelvis(paraserosal):D-SRCT

EEFTs:Dx (Clues from Primary site in children)

- Viscera:

ES: Kidney, lung, GIT, adrenal, pancreas, liver (Riggi 2020), thyroid, parotid (Bishop 2015)

(Any tumor anywhere: BCOR-ITD sarcoma/CCSK) , D-SRCT: Kidney)

- (Metastatic pattern- BM:ES, Bone:CCSK)

EEFTs:Dx-Clues:clinical features - examples (Riggi 2021)

- Positive/-ve clues from age, sex, race, primary site, metastatic pattern (Lab data ?)
- (Imaging studies to be reviewed before constructing histologic profile)
- ES 10 times less common in Black children (ES does occur in Eastern countries(15% of bone cancer in India Chakraborty D J Bone Oncol 2018;12:49)
- Imaging studies favor ES of bone .

EEFTs:Dx-Clues from clinical features & imaging (Riggi 2021)

- Example of clinical profile: White boy,14 years old, metaphyseal tumor in R femur, moth-eaten appearance, no intratumoral bone formation (Valeran A Appled Radiol 2018;47:8), high serum LDH

- Commonest EEFT with this clinical profile : Clue to Dx of ES

EEFTs:Dx (Next step: Clues from routine histology)

.Histologic features described in literature & seen in personal experience mostly from resected specimens or incisional Bx:

(Current trend-Core Bx: Focal features, e.g. rosettes may not be seen or may be distorted)

Knowledge of features seen in resected specimens as a guide to what to look for in core Bx is helpful

EEFTs:Dx (Next step: Clues from routine histology)

.

Histologic features (in resected specimens or incisional bx)

- Tumor Cells Their Pattern Stroma
- Vascularity Secondary changes

EEFTs:Dx (Clues from routine histology)

- Features of individual tumor cells: atypia

shape/size-uniformity or variation, spacing

chromatin/nucleoli mitosis

degenerative change (light & dark cells)

rhabdoid/plasmacytoid change

EEFTs:Dx (Clues from routine histology)

- Pattern: Diffuse or specific pattern

.Diffuse

.Cords, Clusters, Lobules, Nests, Islands.

.Rosettes

.Focal Gland-like/pseudo alveolar or Myoepithelioma-like or

Adamantinoma-like pattern

EEFTs:Dx (Clues from routine histology)

- Stroma: Amount

Amount - Minimal/moderate/abundant

Type -

Collagenous myxoid hyaline

EEFTs:Dx (Clues from routine histology)

- Vascularity: Any particular pattern

Capillaries and their pattern

Larger blood vessels

- Secondary changes:No particular clues, but to be looked for and noted

Necrosis Microcysts Calcification

EEFTs:Dx (Clues from histologic profile)

.Look for & Make a note of details of each aspect of the features

Tumor Cells Their Pattern Stroma

Vascularity Secondary changes

. Construct a histologic profile for a working Dx to be used for targeted ICC stains

.Important first step before constructing profile: Two subgroups – ES & Non-ES

EEFTs:Dx (Clues from routine Tumor Cell cytology/histology)

- Two groups on the basis of clues from basic cellular features:
- ES (uniform evenly spaced RCs without atypia)
- Non-ES (unevenly spaced RCs + Spindle cells,variable atypia)

Non-ES divided into two subsets

EEFTs:Dx (Clues from routine Tumor Cell cytology/histology)

- Non-ES divided into two subsets
- BCOR Rearrgd sarcomas (minimal atypia, four elements and classic pattern with chicken wire capillaries)
- Non-BCOR Rearrgd sarc (moderate atypia):
- EWS-NFATC2 EWS-PATZ1
- D-SRCT(EWS-WT1) CIC Rearrgd sarcomas
- (Patterns- desmoplasia; brisk mitosis}

EEFTs:Dx (Clues from routine Tumor Cell cytology/histology)

- Two groups on the basis of clues from basic cellular features: ES & Non-ES

1.EEFT with SINGLE cell type - uniform evenly spaced RCs, generally low mitotic activity : ES, typical

2.EEFTs generally with TWO cell types - unevenly spaced RCs & spindle cells, variable but generally atypia of one/both cell types, generally moderate mitotic activity: Non-ES

EEFTs:Dx (Clues from routine Tumor Cell cytology/histology)

- Two groups on the basis of clues from cellular features: ES & Non-ES

1.EEFT with SINGLE cell type –

.Uniform/monotonous evenly spaced RCs,

.Absent/minimal atypia (fine chromatin absent/ inconspicuous nucleoli)

.Usually low mitotic activity clear cytoplasm

Clues for ES, typical (Complete histologic profile after finding more clues)

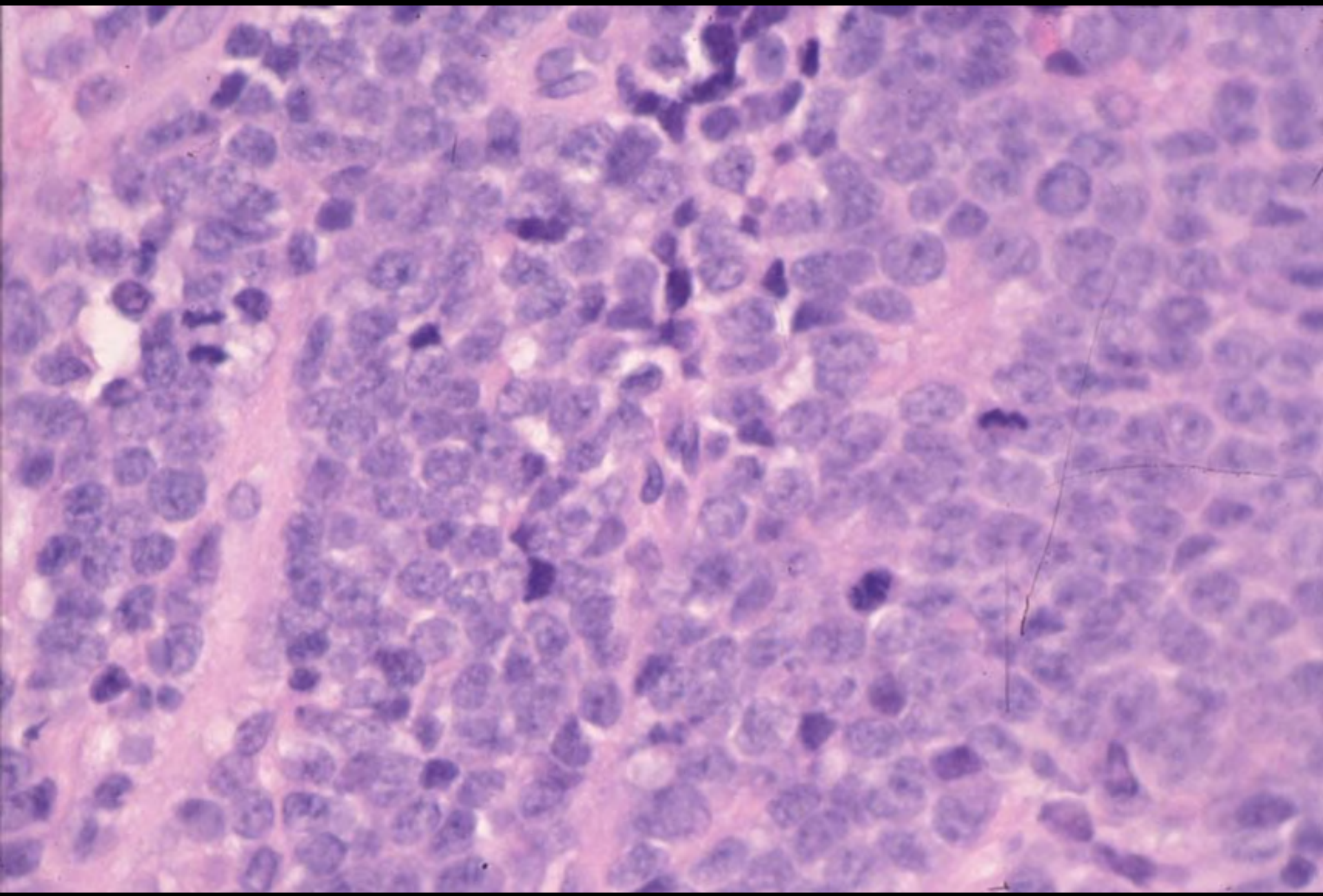

EEFTs:Dx (Two groups based on routine Tumor Cell cytology/histology)

2.EEFTs: features unlike group I, but heterogeneous tumors with certain common features :

Uneven spacing-RCs +/- spindle cells(stroma)

Variable cellular atypia (hyperchromasia, nucleoli, pleomorphism)

Variable mitosis (usually moderate to brisk)

Clues for Non-ES (Atypical ES) (constructing a complete histologic profile after more clues)

EWS-PATZ1 Fusion Sarcoma:Chougule A 2019-RC, Spindle cells,Hyalinized str/capil

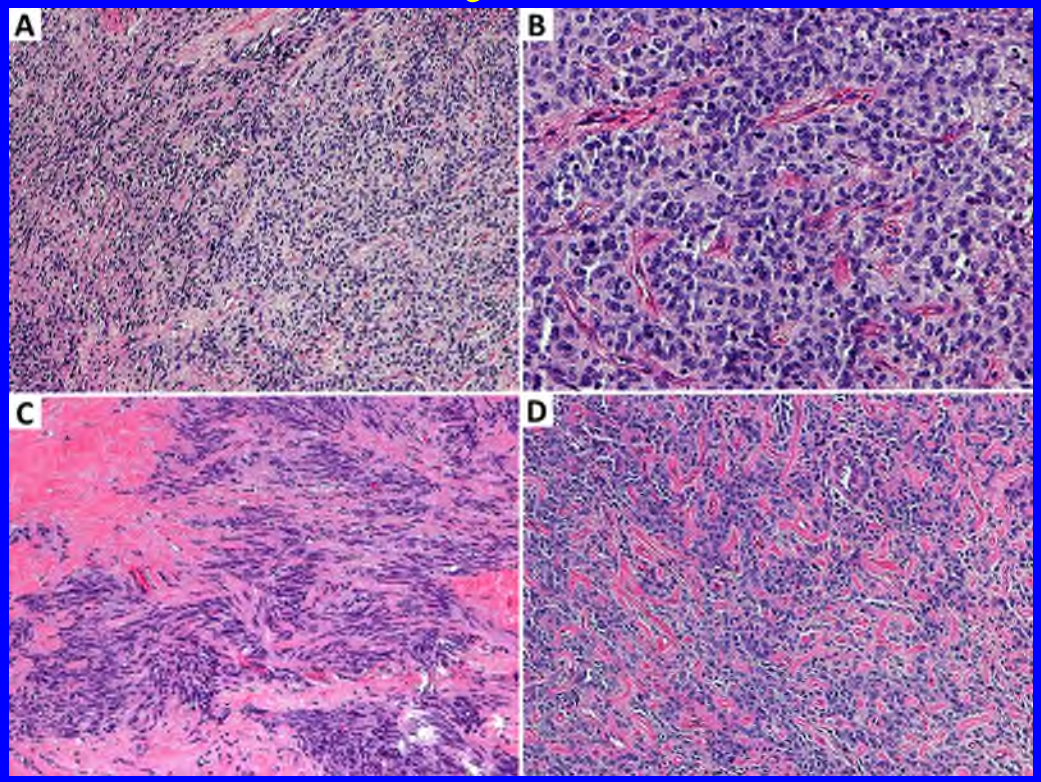

Smith SC 2015:CIC rearrgd: uneven spacing,b:myxoid stroma c/f:nucleoli d:necr e:brisk mitosis

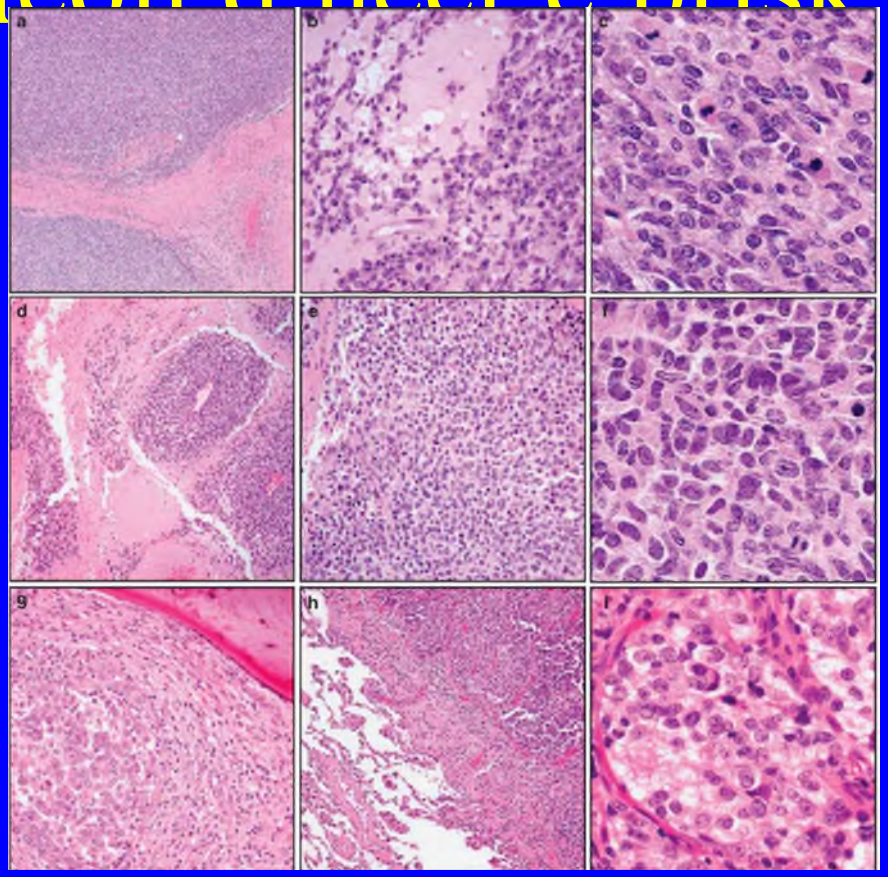

EEFTs:Two groups – basic histology

- .ES:FET-ETS family gene fusion sarcoma
- Non-ES ----------
- 1.FET-Non ETS family gene fusion: EWS-NFATC2 fusion & EWS-PATZ1 fusion RCS
- 2.D-SRCT: EWS-WT1 fusion sarcoma
- 3.BCOR-CCNB3 or BCOR-ITD sarcomas e.g. Primitive Myxoid Mesenchymal Tumor of Infancy (PMMTI) & 3 other subsets
- 4.CIC-DUX4 (or other gene) fusion sarcomas

EEFTs:Dx (Clues from routine Tumor Cell histology)

.Two groups - cellular features: Mitosis

2. EEFTs showing moderate to brisk mitotic activity: clue for Non-ES (BCOR & CIC Rearragd 12, 30/10hpf respectively,exception-EWS-PATZ1 <1/10HPF)

EEFTs:Dx (Clues from routine Tumor Cell cytology/histology)

.Two groups not as clearly defined in practice as described – normal variations (mostly RCs in CIC Rearrgd or minimal atypia in BCOR Rearrgd sarcoma) or exceptions (e.g. spindle cell or moderate mitosis in ES) .

.But evenly/unevenly spaced uniform/atypical RCs & spindle cells, min/moderate stroma helpful in the group which a given case belongs to.

Smith SC 2015:CIC rearrgd: uneven spacing,b:myxoid stroma c/f:nucleoli d:necr e:brisk mitosis

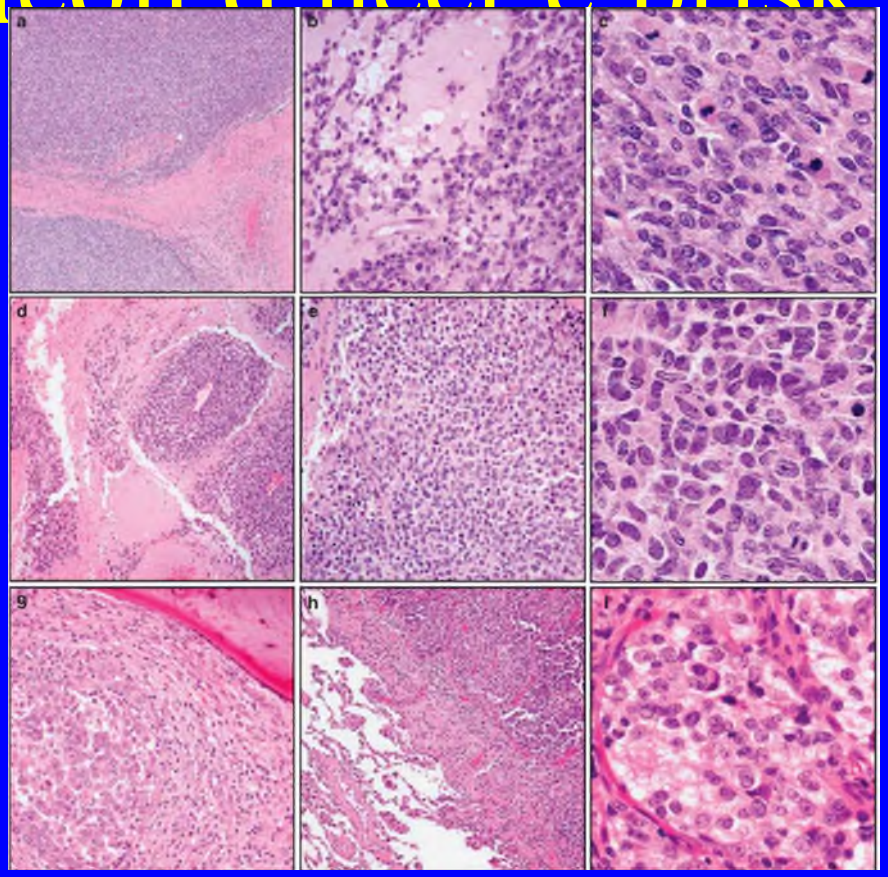

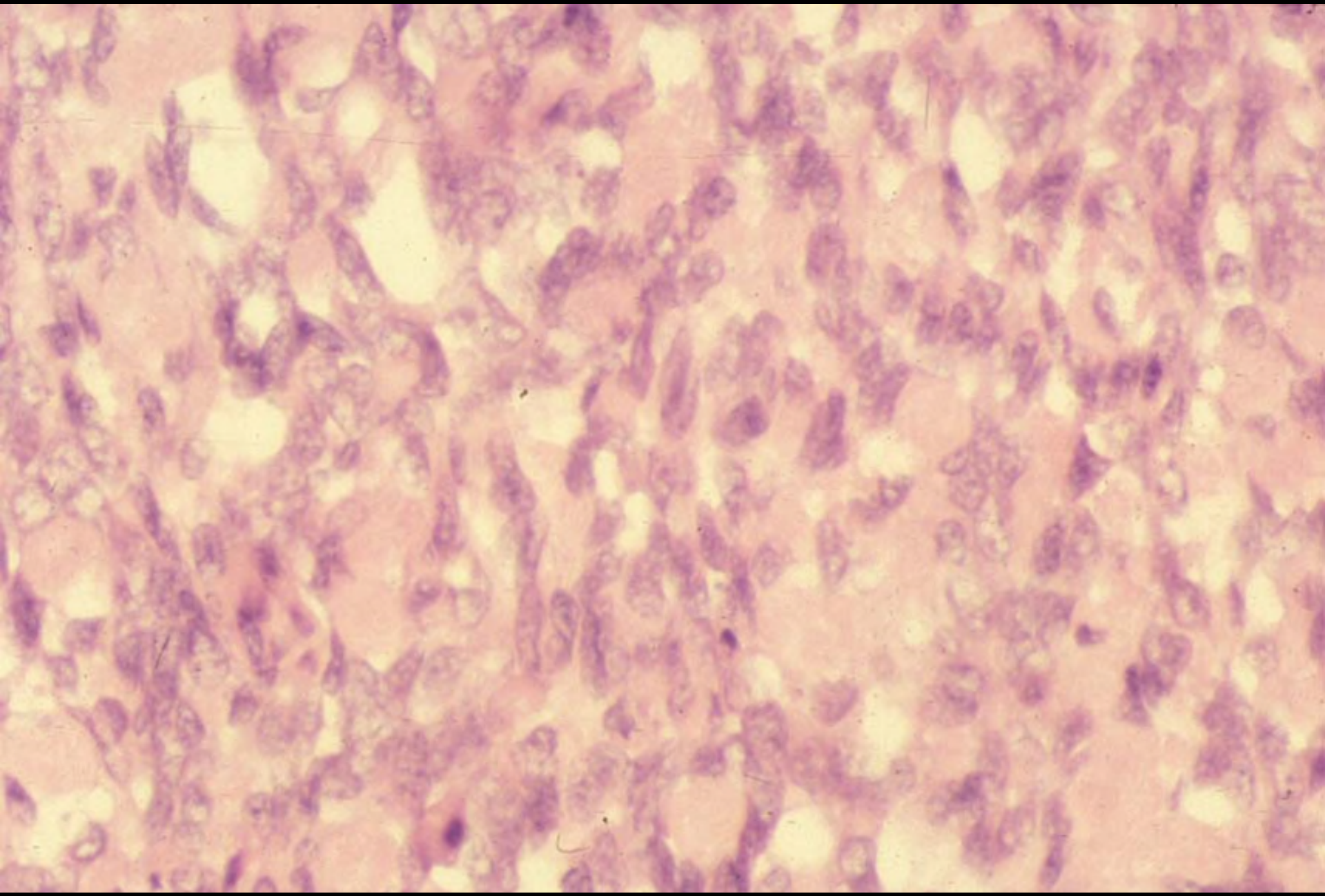

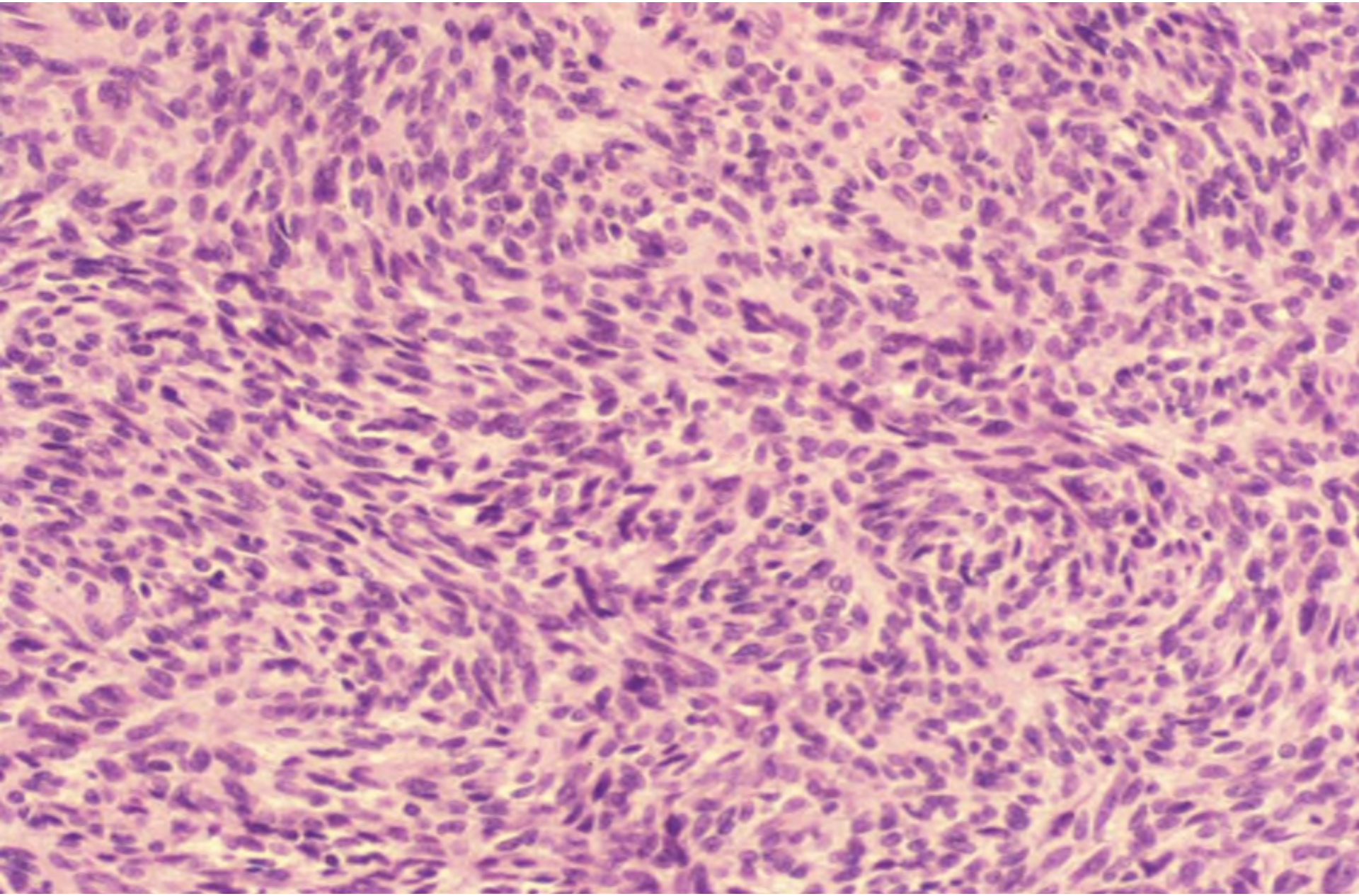

EEFTs:Dx (Clues from histologic profile)

.Presentation of five histologic profiles constructed from literature & personal experience as clues for ES (different subtypes)

and

one profile as a clue for a Non-ES viz BCOR Rearragd sarcomas

.

EEFTs:Dx (Clues from routine Tumor Cell cytology/histology)

First histologic profile

a. uniform evenly spaced RCs with low mitotic activity

b. fine chromatin (it packages long DNA molecule into compact form)

c. inconspicuous nucleoli d. light & dark cells

e. no rosettes f. diffuse/lobular pattern

g.little stroma h. thin capillaries (no pattern)

EEFTs:Dx (Clues from first histologic profile – continued)

i.Clear cytoplasm (Glycogen + ve)

j. Sparse/no reticulin (++ in RMS & NHL)

Clue from +ve (uniform evenly spaced cells etc) and -ve (absence of atypia, rosettes & no reticulin around individual cells,stroma) features :Typical ES without neural differentiation

(Mod. mitotic activity: rare/occasional cases)

EEFTs:Dx (Clues provided by FNAB-Multiple passes)

- Cellular features better seen in

FNAB smears (More prevalent in developing countries - late stage of disease, poor general condition of patient)

&

Imprints: resected specimen/incisional Bx

FNAC of ES (Buch AC-DYPMC,PUNE- J Cytol 2010;27:146) Giemsa & PAS+ Uniform RCs,fine chromatin

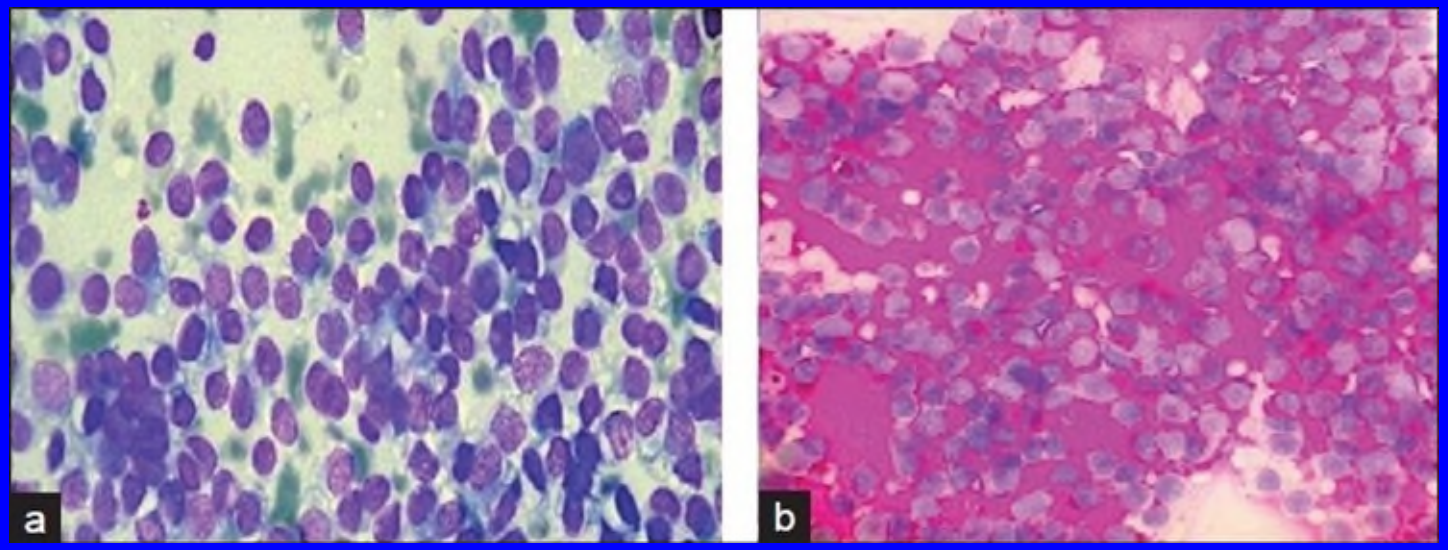

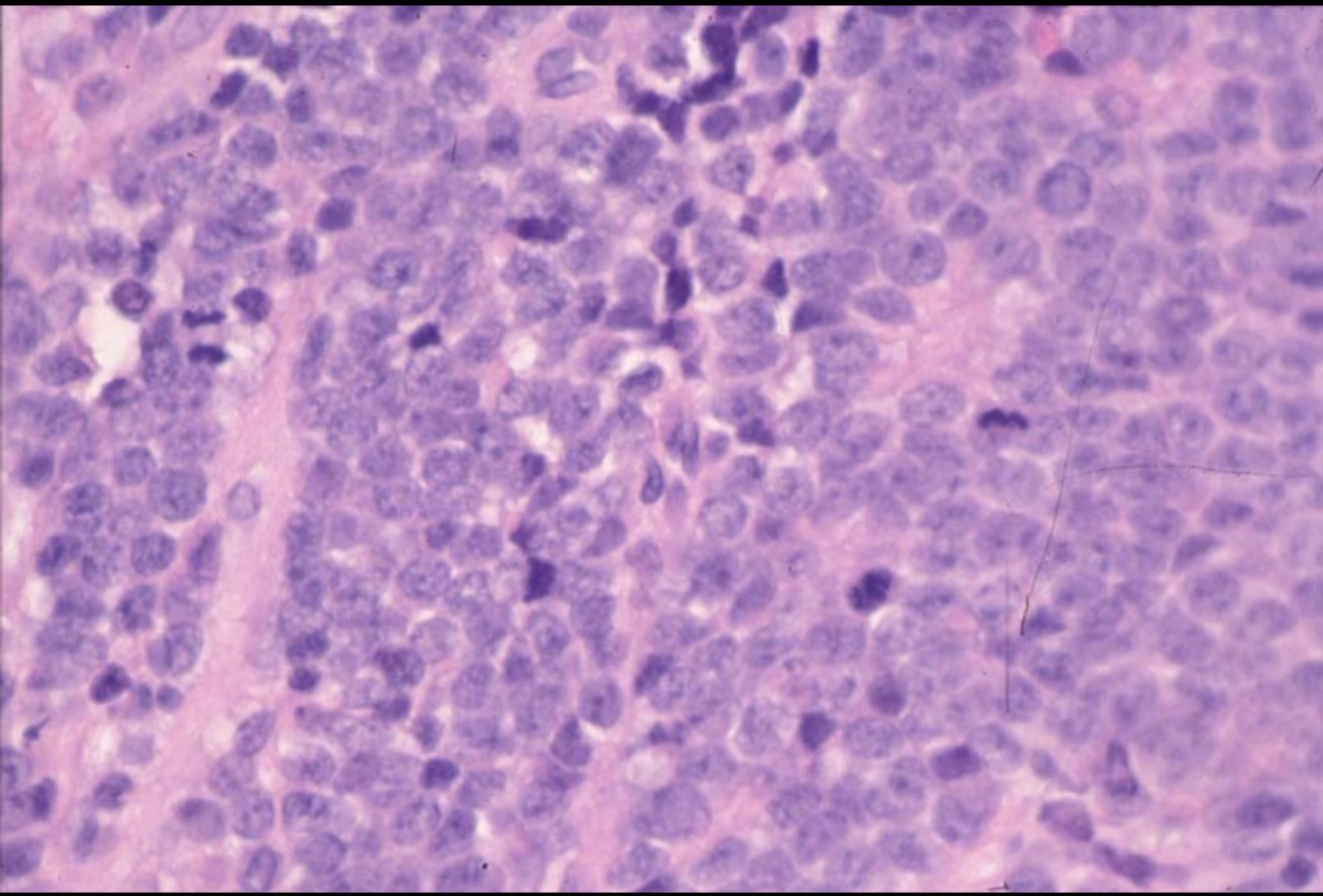

ES-light & dark cells (Parham 2010)

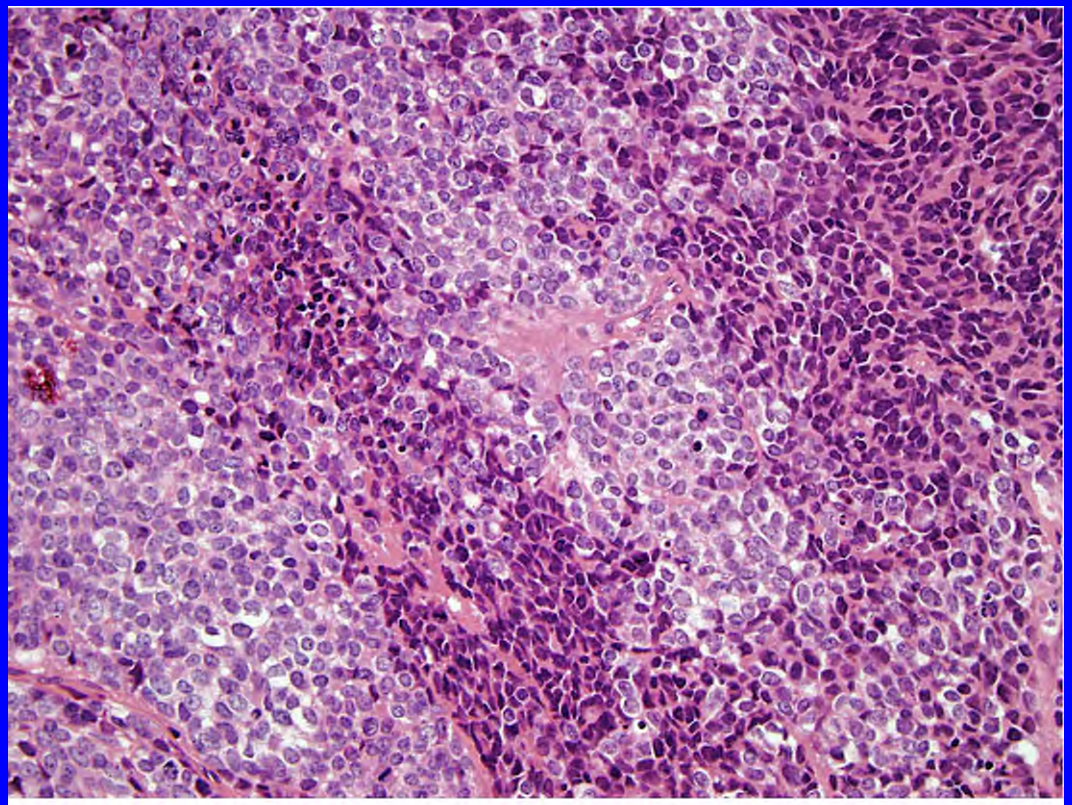

"light" cell and "dark" cell appearance

ES:Uniform evenly spaced RCs pale/clear cytoplasm due to Glycogen.

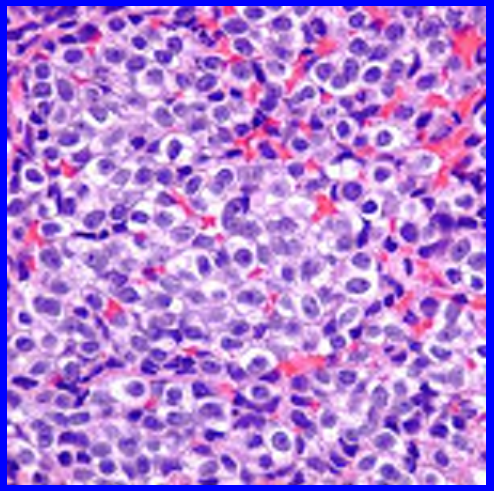

ES-PAS Stain- Pathology Outlines

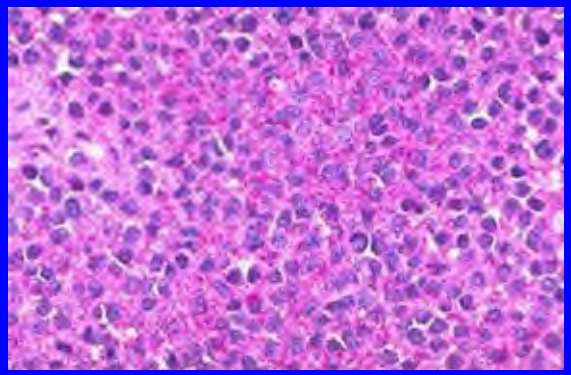

EEFTs:Dx (Clues from routine Tumor Cell histology)

.

Glycogen + in 65% of ES (Kissane J Hum Pathol 1983;14:773)

(NB 50, RMS/NHL 10%)

EEFTs:ES - PAS & Reticulin stains : Not done currently

.Ultrastructure of glycogen: aggregate/rosette form in ES, individual particles in other SRCTs(Parham 1996)

.Stain for Reticulin (histological term used for connective tissue fibers composed of type 3 collagen): no reticulin around individual cells in ES (RMS & NHL more marked staining) (Kissane 1983,Parham 1996)

(PAS & Reticulin stains of ?historical interest- Latter helpful in highlighting chicken wire capillary pattern in BCOR Rearrangd sarcomas)

ES-focal,multi-particulate glycog,few organelles(Courtesy Dr G Mierau)

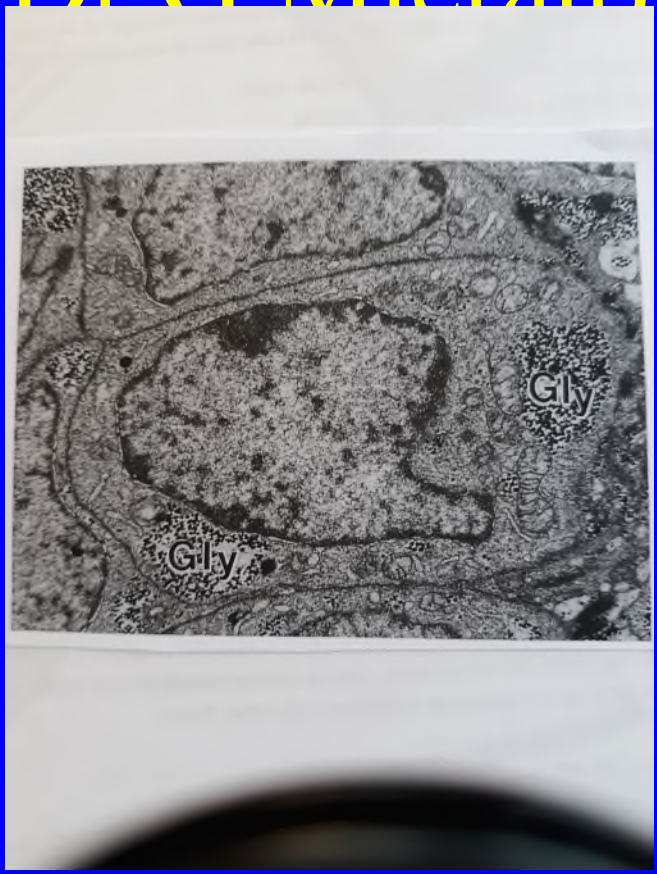

ES:Reticulin only in the bv wall, none around cells(AFIP Fasc 5 2nd series)

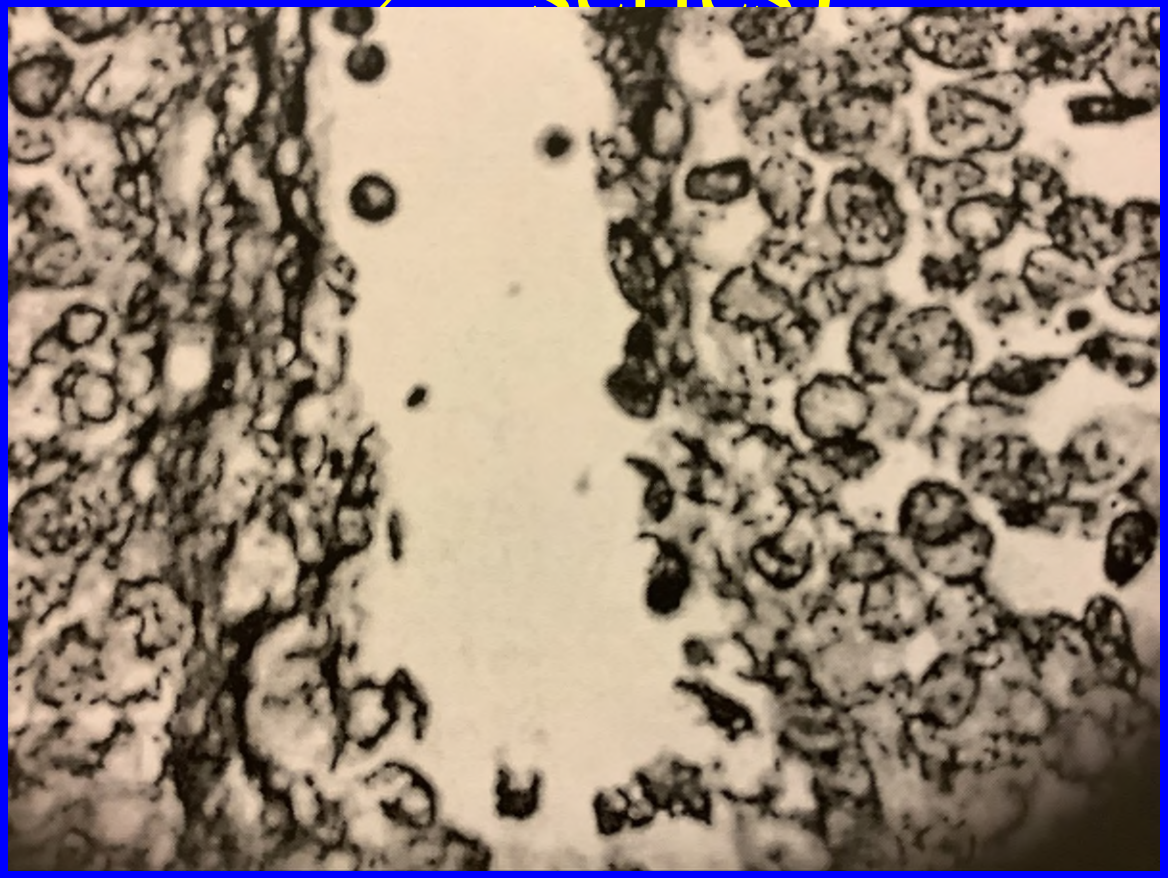

ES: capillaries with no particular pattern (Pathology Outlines)

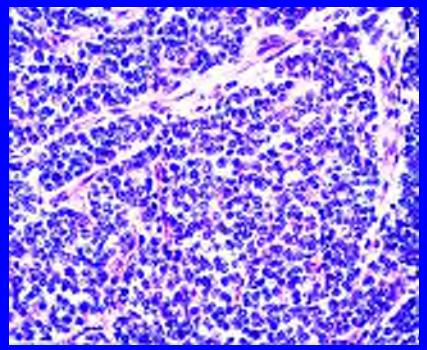

EEFTs:Dx (Clues from routine Tumor Cell cytology/histology)

Next histologic profile :All features seen first profile +

. Rare to occasional ROSETTES

Clue: ES, typical with neural differentiation (24% cases of soft tissue ES- Shimada 1988)

Antonescu C Histopathology 2014;64:26:A-typical ES B lobules/rosettes D-FLI1

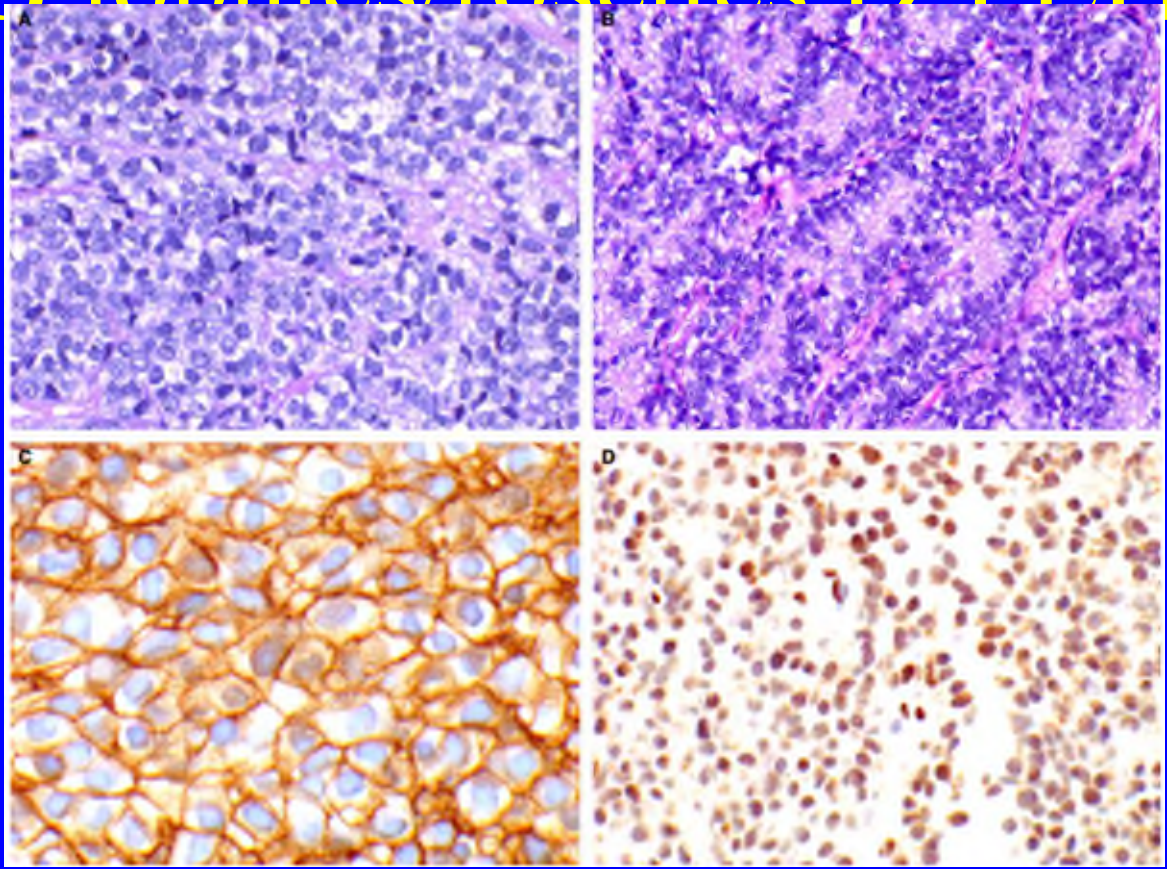

EEFTs:Dx (Clues provided by FNA cytology-Multiple passes & by EM)

.Cell blocks from FNAB (Three cases):

Suggestion of Rosettes in one case - clue for ES with neural differentiation

Definitive Dx made by

ICC for CD99,NSE,Vimentin: all +ve

FISH & RT-PCR for EWS-FLI1

(Sanati S Cancer 2007;111:192)

.EM: Neuritic processes and granules (personal cases)

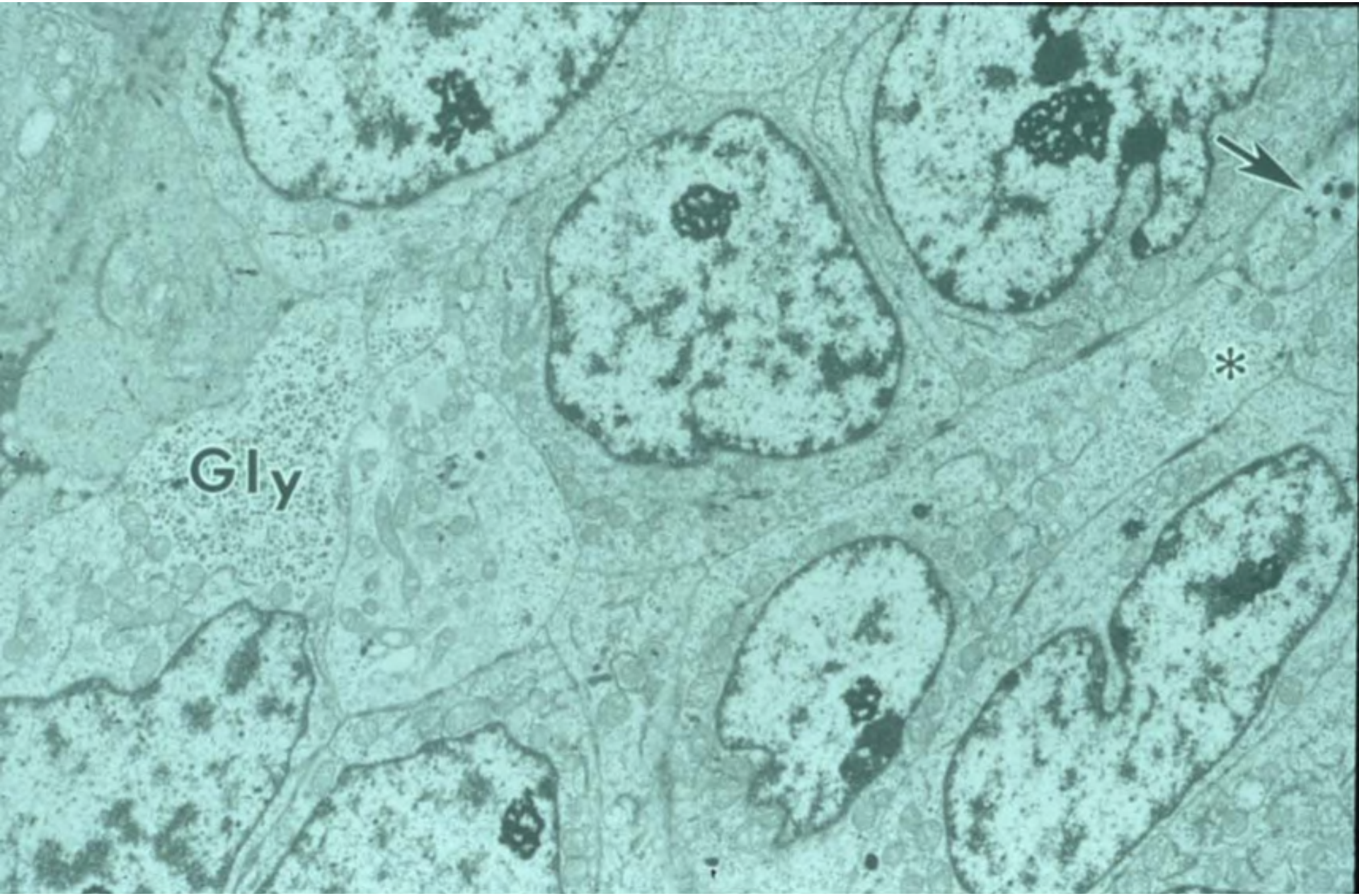
Gly
*

EEFTs:Dx (Clues from routine Tumor Cell histology)

- Next histologic profile - Rare

All features of the first profile with

the addition of foci of

.Basaloid cells and Squamous cells:

Typical ES with epithelial differentiation

Antonescu 2014:ES-A:basaloid,B sq,C:CD99,D-Epith Keratin+

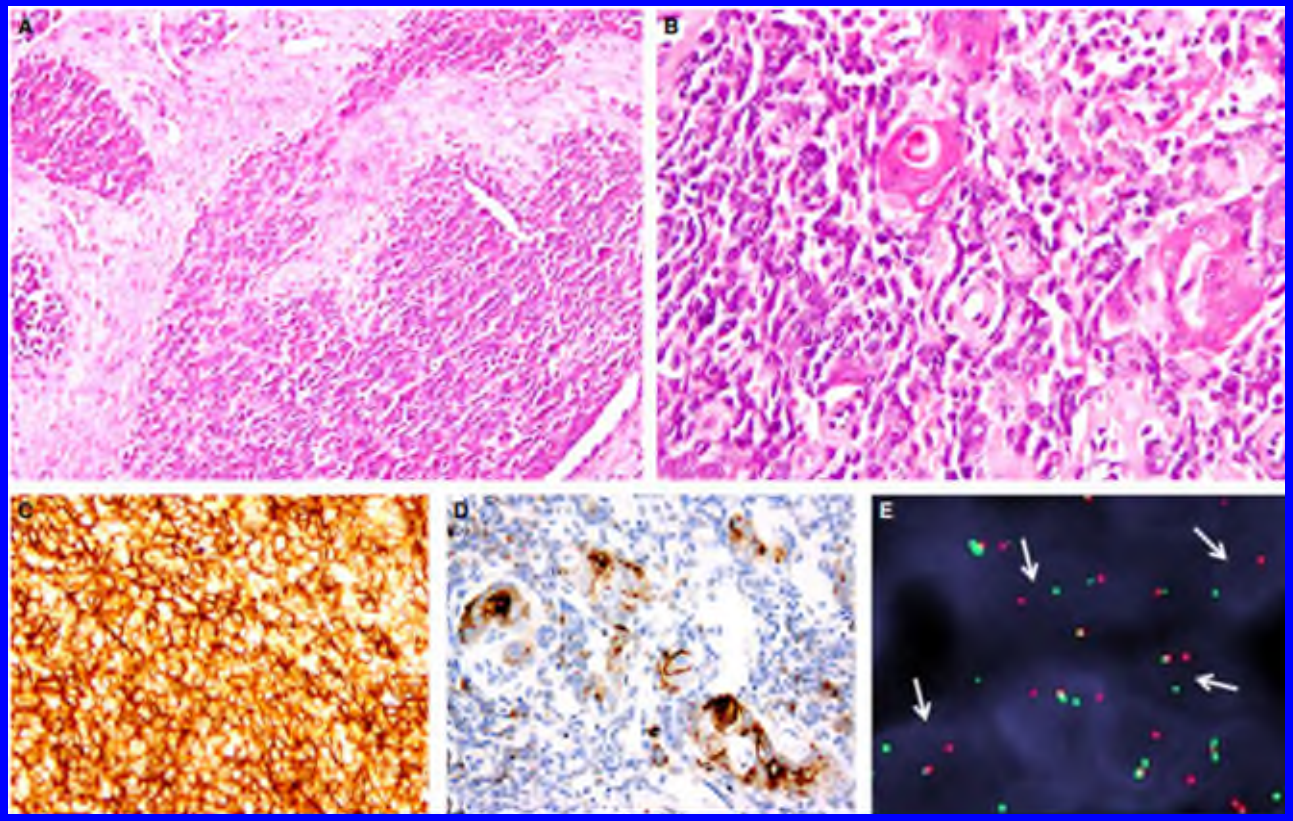

EEFTs:Dx (Clues from routine Tumor Cell histology)

- Next Histologic profile: Rare

All features of first profile suggestive of typical ES except diffuse/lobular pattern

but with adamantinoma-like pattern

(Rarely rosettes may be present as in histologic profile of ES with neural differentiation)

Clue:Typical ES with adamantinoma-like pattern

Adamantinoma-like ES (Bishop 2015)Nests of uniform RCs, septa,palisading,rosettes,hyaline

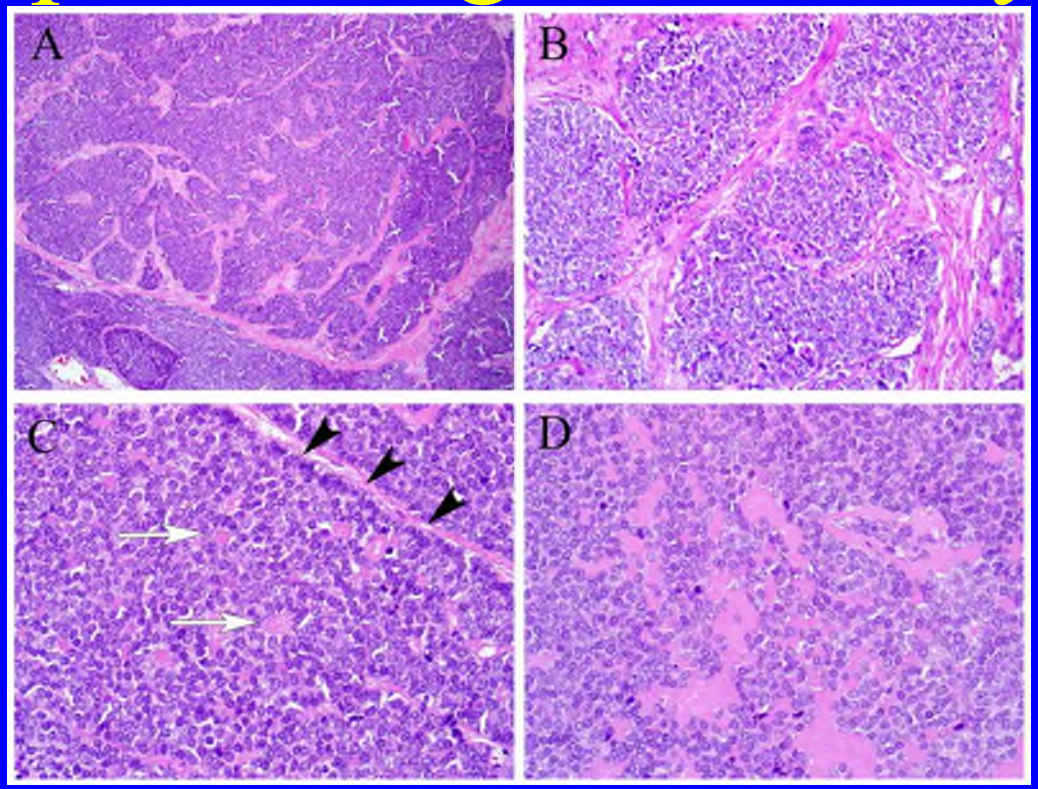

EEFTs:Dx (Clues from routine Tumor Cell cytology/histology)

Next histologic profile: Rare

a. Large evenly spaced atypical cells
b.Coarse chromatin

c. Prominent nucleoli prominent mitosis

e. Sparse/no reticulin & stroma

Clue based on these features: Large cell atypical ES (DD – Non-ES : even spacing, only RCs, little/no stroma as clues)

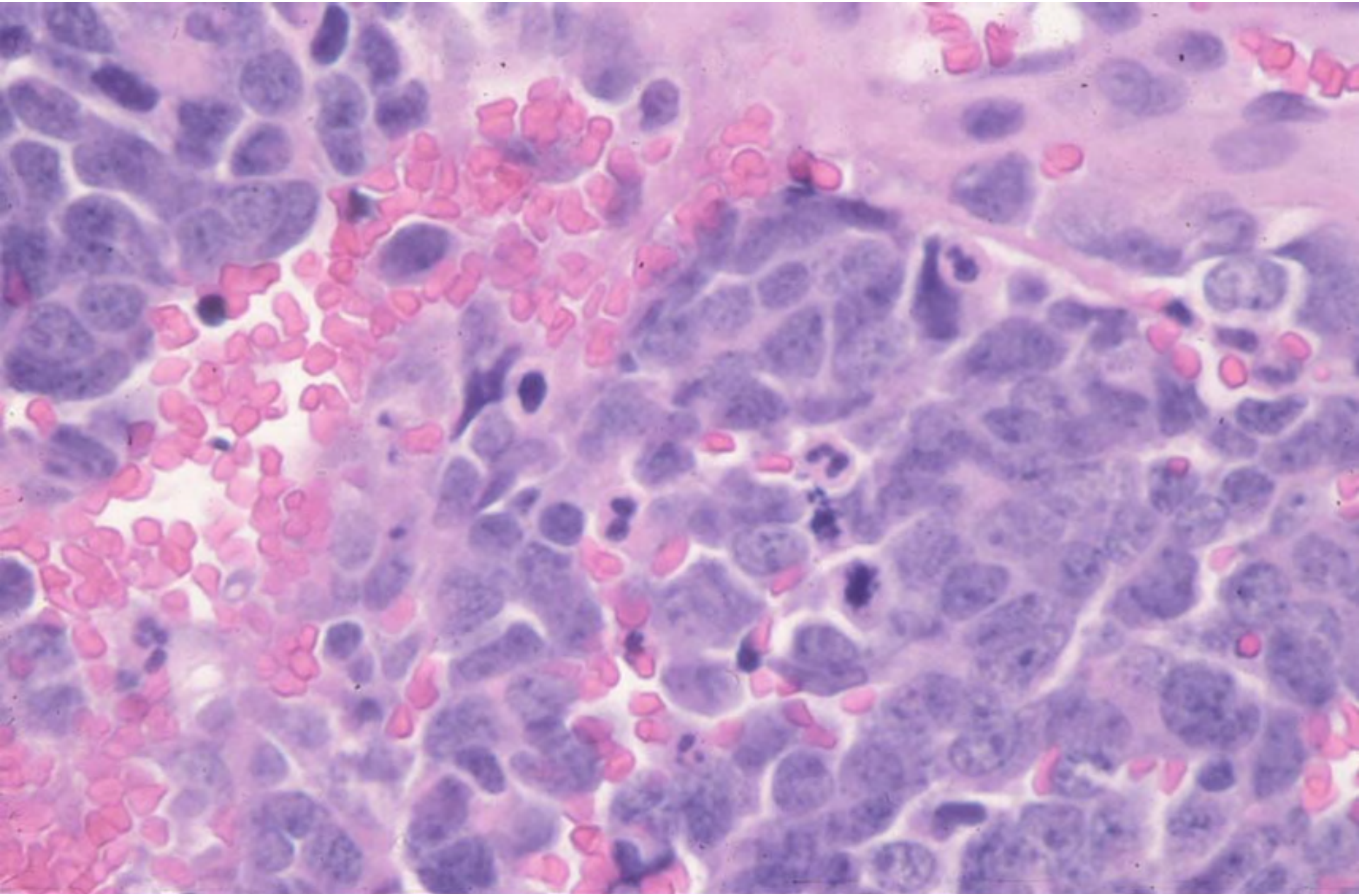

EEFTs:Dx (Clues from routine Tumor Cell cytology/histology)

Subtypes of ES based on histologic profiles

I.Typical ES:.a & b:With/out neural differentiation

.c: Rarely with focal epithelial differentiation

.d: Rarely with adamantinoma-like pattern (rosettes may be present)

II. Atypical large cell ES

(All of above show diffuse membranous staining for CD99 & FET-ETS gene fusion)

EEFTs:Dx (Next histologic profile- Non-ES)

2.EEFTs: features unlike group 1, but heterogeneous tumors with certain common features :

Uneven spacing-RCs +/- spindle cells(stroma)

Variable cellular atypia (varying cell contours or hyperchromasia, nucleoli, pleomorphism)

Variable mitosis (usually moderate to brisk)

Clues for Non-ES (Atypical ES) (More clues: constructing a complete histologic profile)

EEFTs:Dx (Clues from routine Tumor Cell cytology/histology)

Non-ES: Two subgroups based on usual features (two cell types, uneven spacing, stroma) but different degree of cellular atypia

1.BCOR Rearrgd sacomas with variable cell contours as the only feature of cellular atypia (fine chromatin, no nucleoli, low mitosis)

2.Non-BCOR Rearragd sarcomas: moderate atypia with nucleoli, pleomorphism, mitosis

EEFTs:Two histologic subgroups of Non-ES

- A.
- BCOR-CCNB3 or BCOR-ITD sarcomas e.g. Primitive Myxoid Mesenchymal Tumor of Infancy (PMMTI) & 3 other subsets
- B.
- 1.FET-Non ETS fusion sarc : two subsets,
- 2. D-SRCT (EWS-WT1)
- 3. CIC-DUX4 (or other gene) fusion sarcomas

EEFTs:Dx (Clues from routine Tumor Cell cytology/histology)

Next histologic profile: Non-ES (1st subgroup: BCOR Rarrgd sarcoma)

RCs arranged in cords/nests

Spindle cells forming septa

Variable contours as the only feature of cellular atypia (tumor cells with fine chromatin, no conspicuous nucleoli,low)

mitotic activity) Myxoid stroma

Chicken-wire capillary pattern

EEFTs:Basic histologic components of BCOR rearrg sarcomas

.Literature review indicates that ALL subsets of BCOR rearrgd sarcomas share the four basic elements & pattern as noted in this profile

RCs in cords/nests, Spindle cells forming septa

(Both cell types with minimal atypia – varying contours)

Myxoid stroma Chicken-wire capillaries

This profile was also described previously in detailed analysis of CCSK (Argani P AJSP 2000;24:4 & Balarezo F, Joshi VV Adv Anat Pathol 2001;8:98)

EEFTs (Subsets of BCOR rearranged sarcomas)

- a. BCOR fusion sarc: partners-CCNB3 (90%),MAML3,ZC3H7B, KM2D

- b. ST Sarcomas with BCOR-ITD (internal tandem duplication of exon 16) referred to as Primitive Myxoid Mesenchymal Tumor of Infancy and/or Infantile Undiff RC sarc with BCOR-ITD

- c. CCSK (BCOR-ITD ~90%) or (BCOR-CCNB3 fusion)

EEFTs:Basic histologic components of BCOR rearrg sarcomas

This similarity of recently described BCOR Rearrgd sarcomas to CCSK is well-illustrated and mentioned in recent articles on BCOR Rearrgd sarcomas but not emphasized as a strong clue for working Dx on routine histologic examination .

EEFTs: Histologic components and patterns in BCOR rearrg sarcomas

.

Based on 29,36 & 6 cases described by

Kao YC (AJSP 2016;40:1009 & 2018;42:604)

Peters TL (Mod Path 2015;28:575)

Suurmeijer AJH (Genes, Chrom Cancer 2019;58:100)

(Study of 351 NWTS CCSKcases: Argani P AJSP 2000;24:4)

.

EEFTs:Classic & variant patterns:BCOR Rearrgd sarcomas

- Variant patterns besides classic pattern described in lit on CCSK & recent cases of other subsets

.

Different features (e.g. epithelioid): Cord cells &/OR

Selective proliferation of cord or septal cells &/OR

Excess or virtual absence or focal hyalinization of matrix (Lack of clear appearance) &/OR

.

Obscured or focally indiscernible capillary network due to cellularity or large amount of myxoid matrix

EEFTs: Histologic components and patterns in BCOR rearrg sarcomas

CLASSIC PATTERN

CCSK

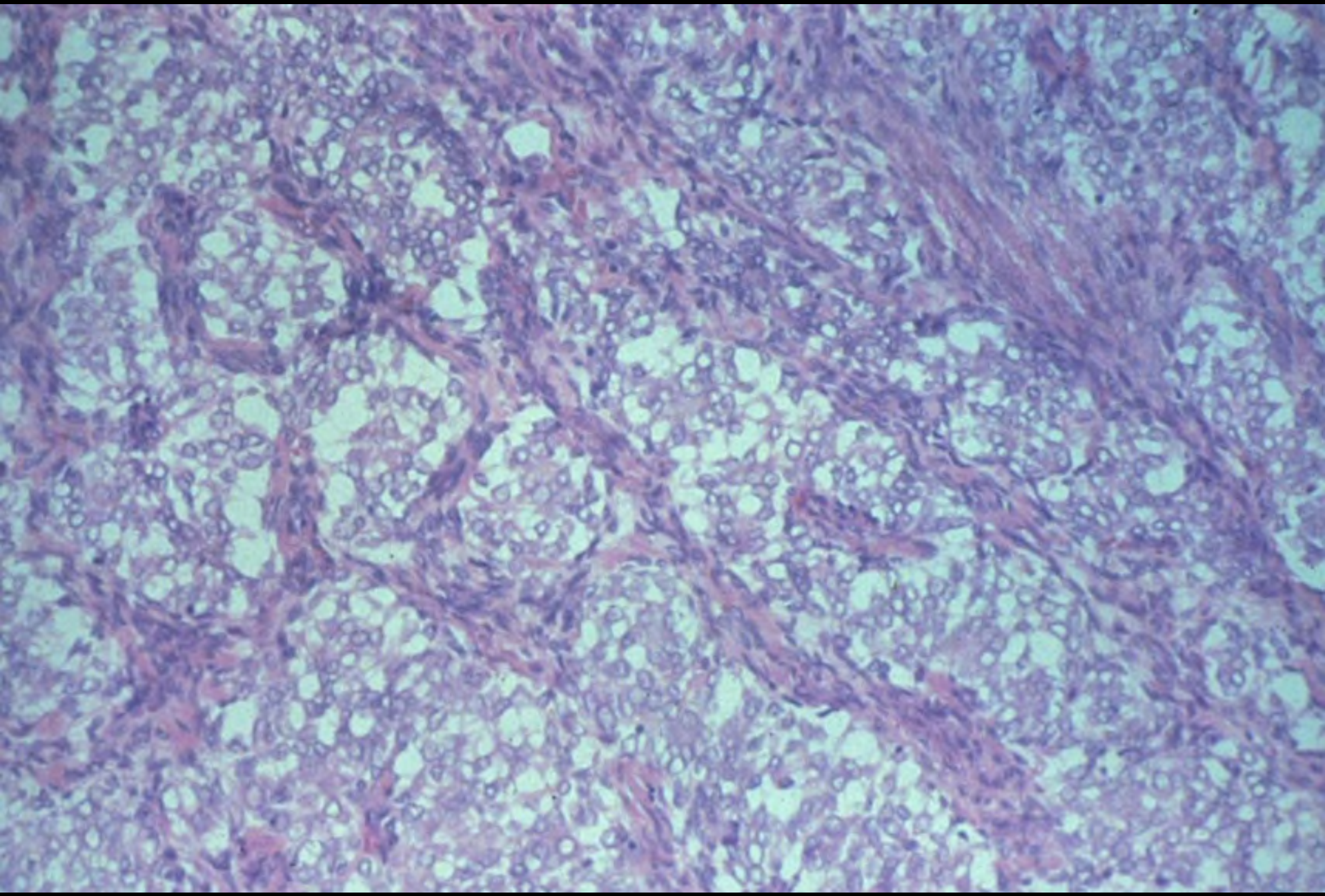

Myxoid liposarc – chicken wire capillaries,lipobl,myxoid stroma

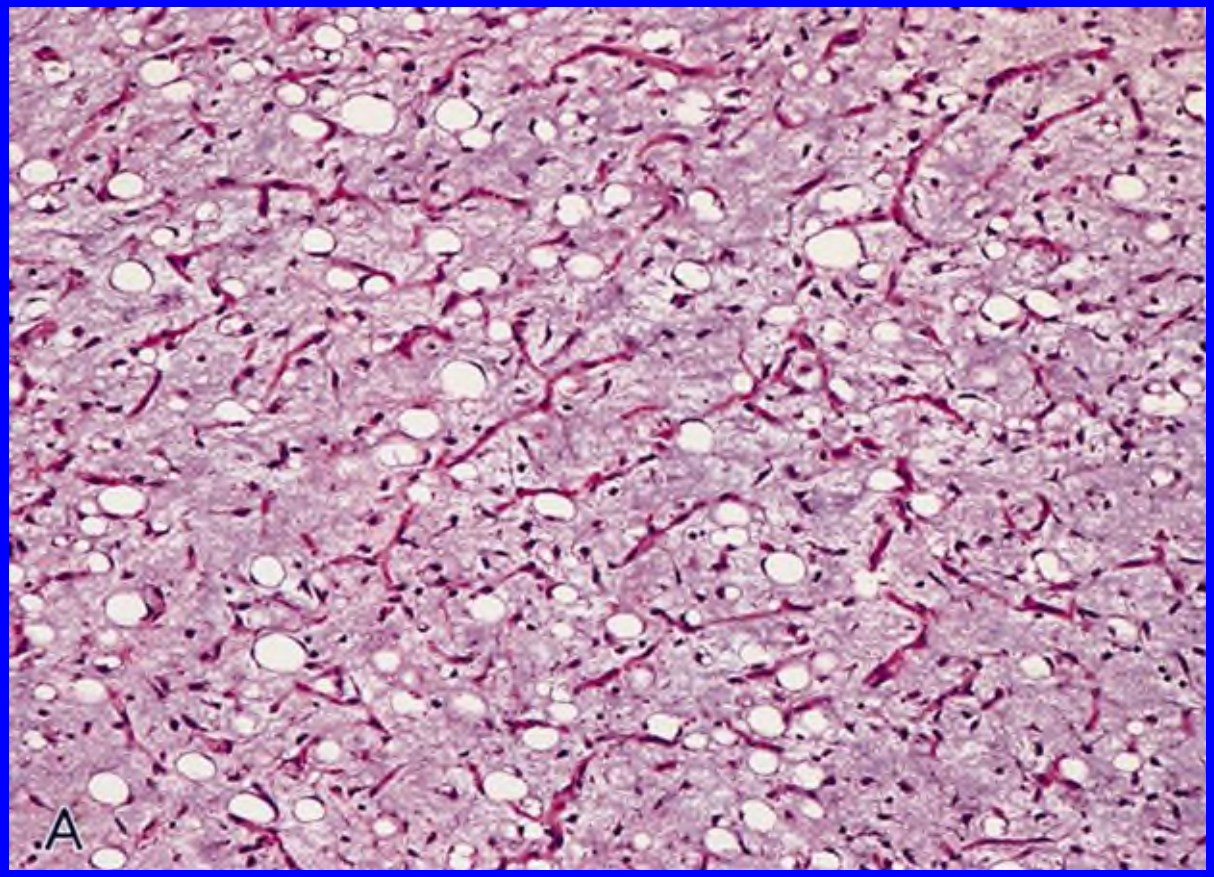

EEFTs: Histologic components and patterns in BCOR rearrg sarcomas

VARIANT PATTERNS

CCSK

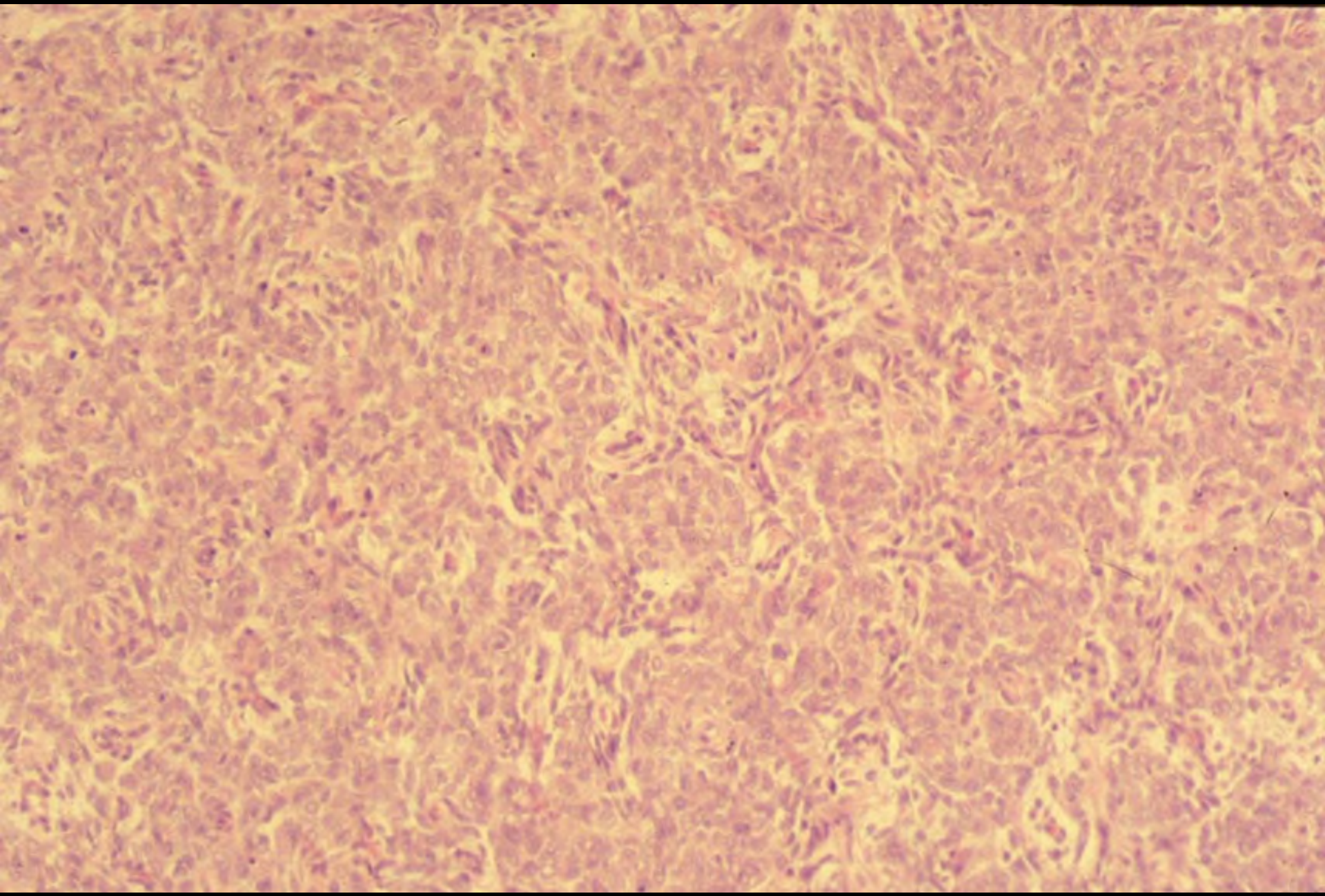

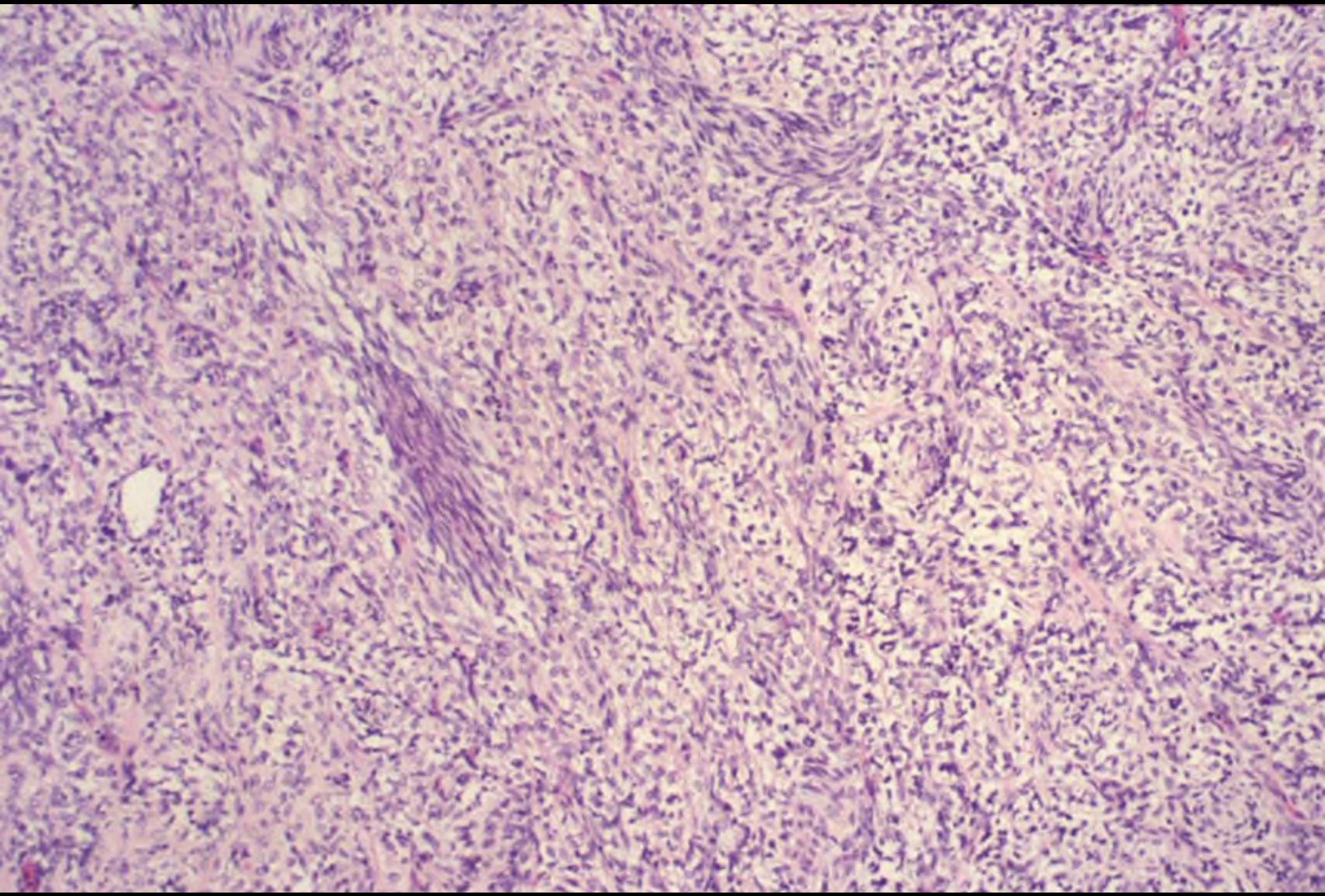

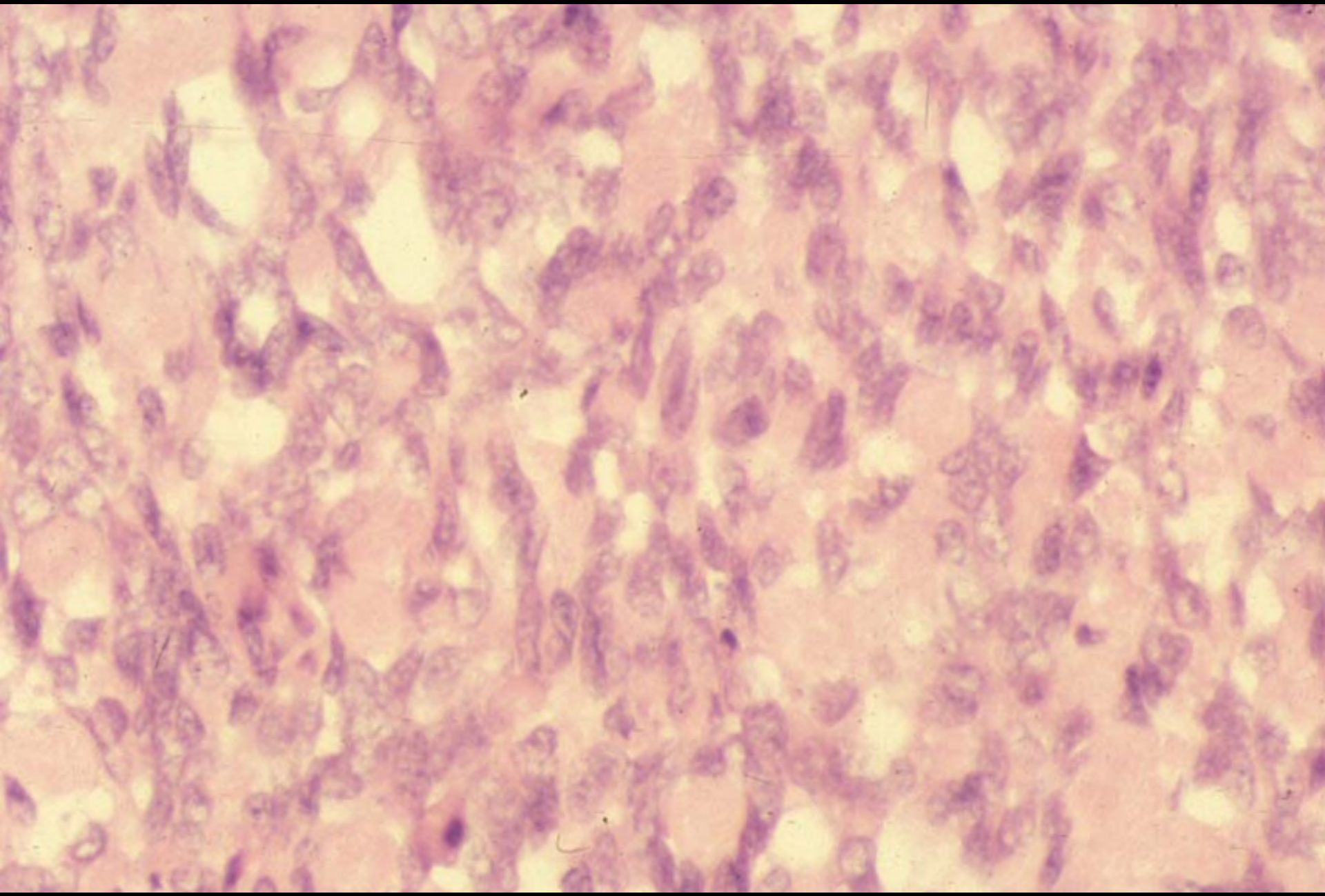

EEFTs: Histologic components and patterns in BCOR rearrg sarcomas

CLASSIC AND VARIANT PATTERNS

RECENTLY DESCRIBED SUBSETS
OF

BCOR REARRGD SARCOMAS INCLUDING CCSK

Kao2016:BCOR-ITD sarc:B-RCs capill.,C-cellular septa,D,F-myx str(vacuol cytopl),E-rosette, A-YWHAE-NUTM2B:same

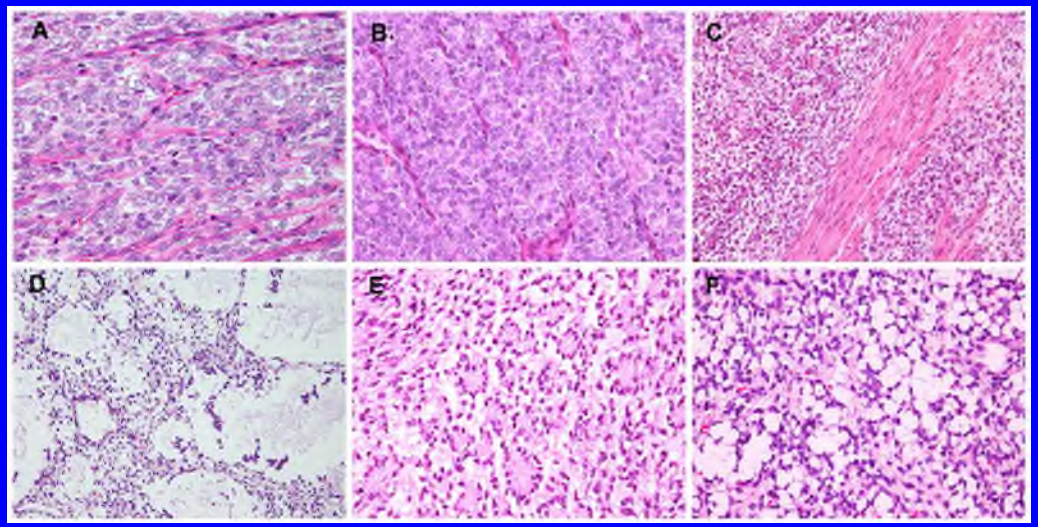

RCs,Septa,Cap,min. myxoid str: A:BCOR-ITD,B,C,D:CCSK ,E-BCOR-ICC:Suurmeijer 2019

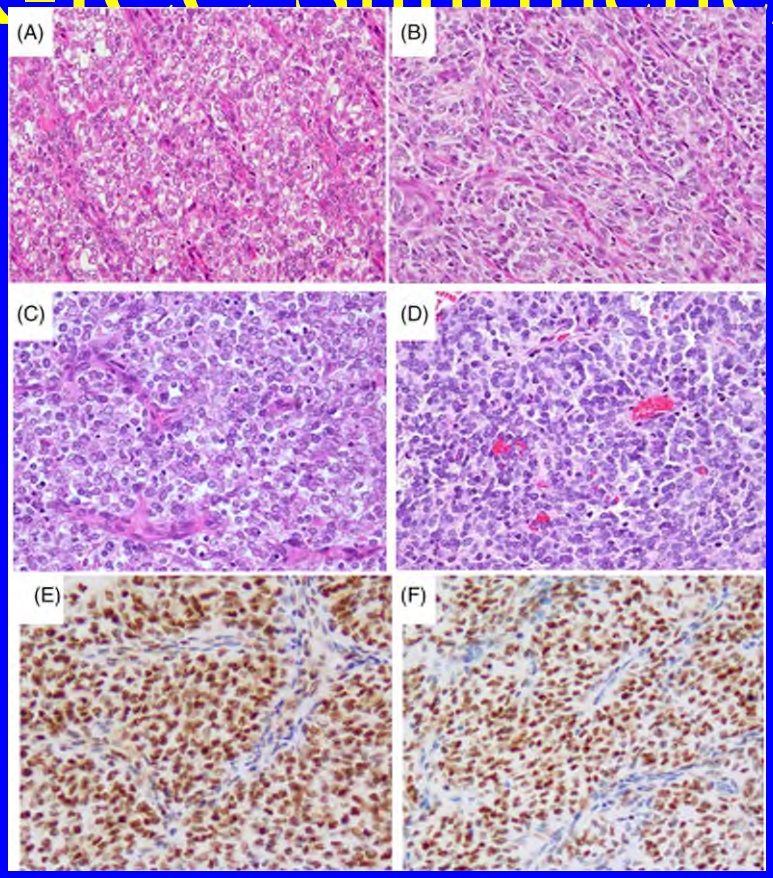

Kao 2016:PMMTI/URCS:A-H:RCs,spindle cells,cap,cellular septa,rhabd cells,myx str(cytopl)

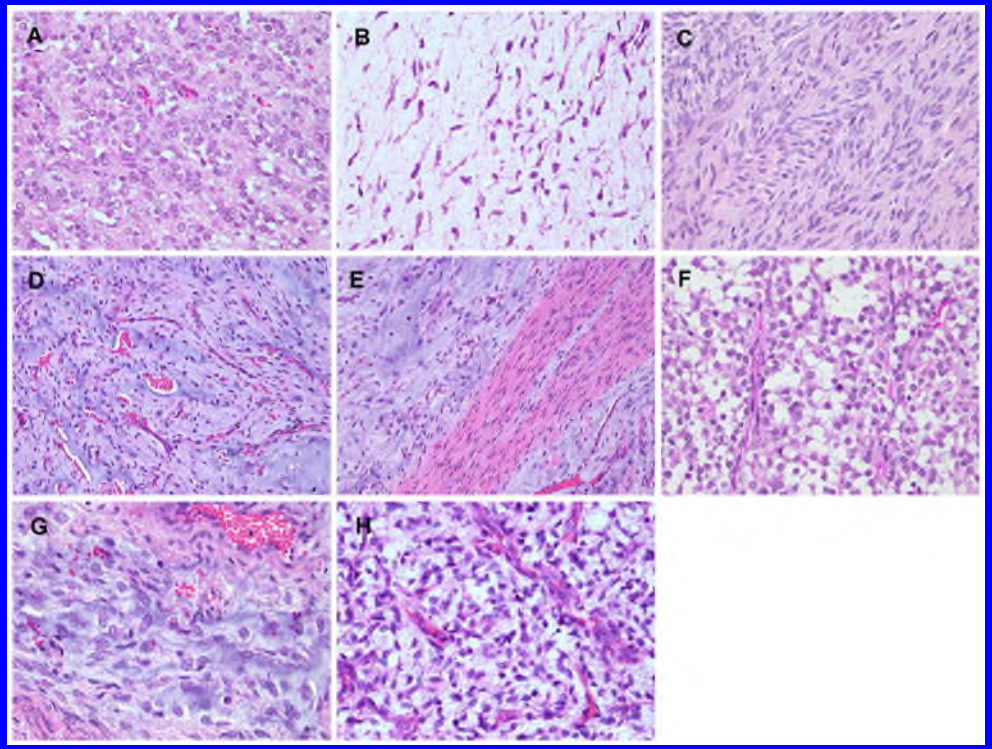

EEFTs:Dx (Clues from routine Tumor Cell cytology/histology)

Non-ES: Two subgroups based on usual features (two cell types, uneven spacing, stroma) but different degree of cellular atypia

1.BCOR Rearrgd sacomas with variable cell contours as the only feature of cellular atypia (fine chromatin, no nucleoli, low mitosis)

2.Non-BCOR Rearragd sarcomas: moderate atypia with nucleoli, pleomorphism, mitosis

EEFTs:Second histologic subgroups of Non-ES

- 1.FET-Non ETS fusion sarcoma :

a. EWS-NFATC2 fusion sarcoma

b. EWS-PATZ1 fusion sarcoma

- 2. D-SRCT (EWS-WT1)
- 3. CIC-DUX4 (or other gene) fusion sarcomas

EEFTs:Dx (Clues from routine Tumor Cell cytology/histology)

- Second subgroup of Non-ES - Features other than cellular atypia providing clues

.Myoepithelioma-like pattern, focal stag-horn blood vessels:

EWS-NFATC2 fusion sarcoma

EWS/FUS-NFATc2 RCS :A-RC area,B-myoepith pattern,C,D nucl atypia :Diaz-Perez 2019

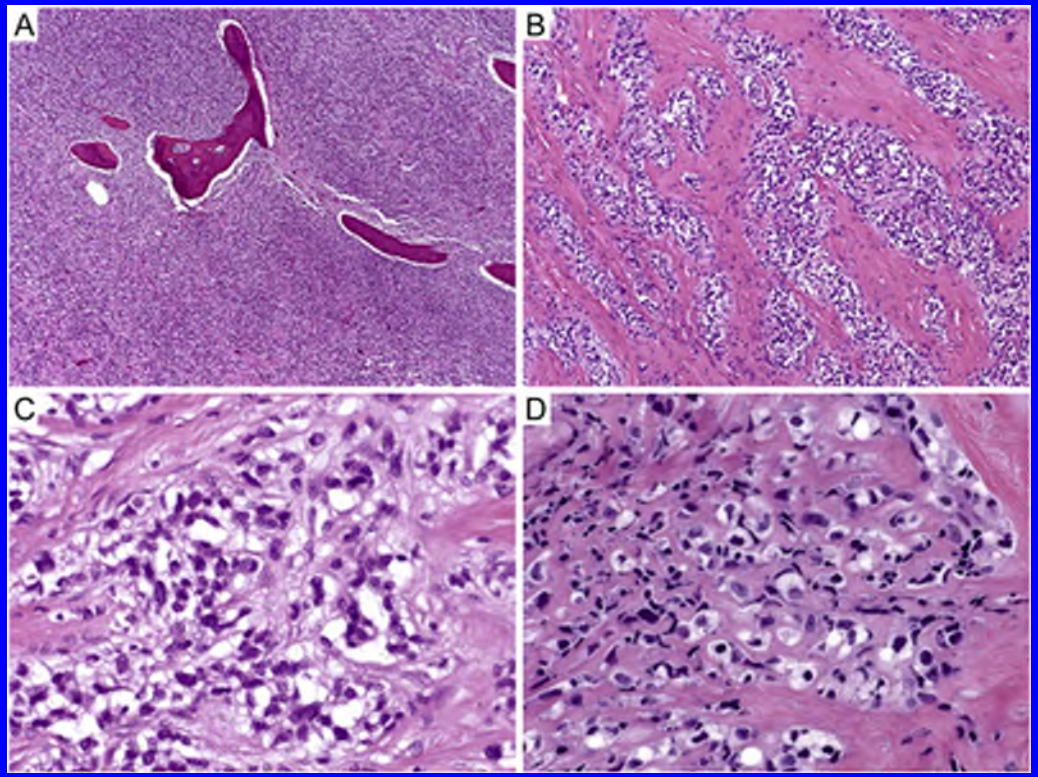

EEFTs:Second histologic subgroups of Non-ES

- 1.FET-Non ETS fusion sarcoma :

a. EWS-NFATC2 fusion sarcoma

b. EWS-PATZ1 fusion sarcoma

- 2. D-SRCT (EWS-WT1)
- 3. CIC-DUX4 (or other gene) fusion sarcomas

EEFTs:Dx (Clues from routine Tumor Cell cytology/histology)

- Second subgroup of Non-ES – Features providing clues
- Low mitotic rate (<1/10 hpf), hyalinized stroma and hyalinized capillaries:

EWS-PATZ1 fusion sarcoma

EWS-PATZ1 Fusion Sarcoma:Chougule A 2019-RC, Spindle cells,Hyalinized str/capil

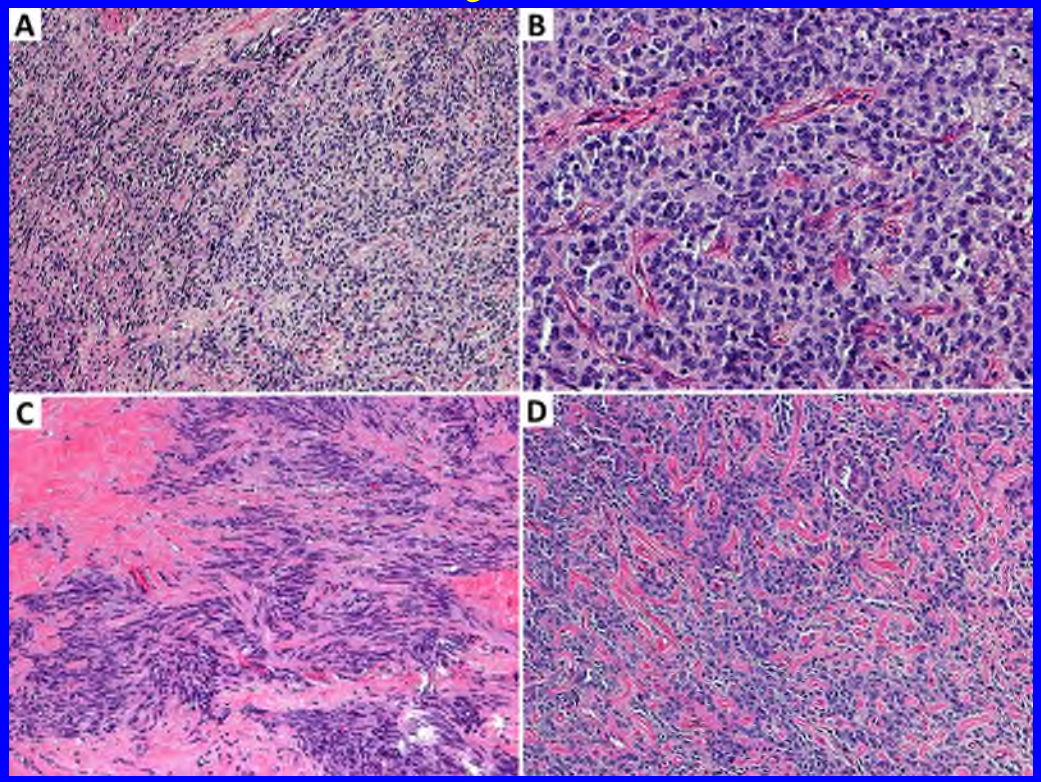

EEFTs:Second histologic subgroups of Non-ES

- 1.FET-Non ETS fusion sarcoma :

a. EWS-NFATC2 fusion sarcoma

b. EWS-PATZ1 fusion sarcoma

- 2. D-SRCT (EWS-WT1)
- 3. CIC-DUX4 (or other gene) fusion sarcomas

EEFTs:Dx (Clues from routine Tumor Cell cytology/histology)

- Features other than cellular atypia providing clues to Non-ES other than BCOR sarcomas

.Desmoplasia, EM-Whorls of intermediate filaments :

D-SRCT- EWS-WT1 fusion sarcoma

(No desmoplasia in renal D-SRCT –Wang L AJSP 2007;31:576)

D-SRCT:islands of tumor cells and fibro-collagenous stroma

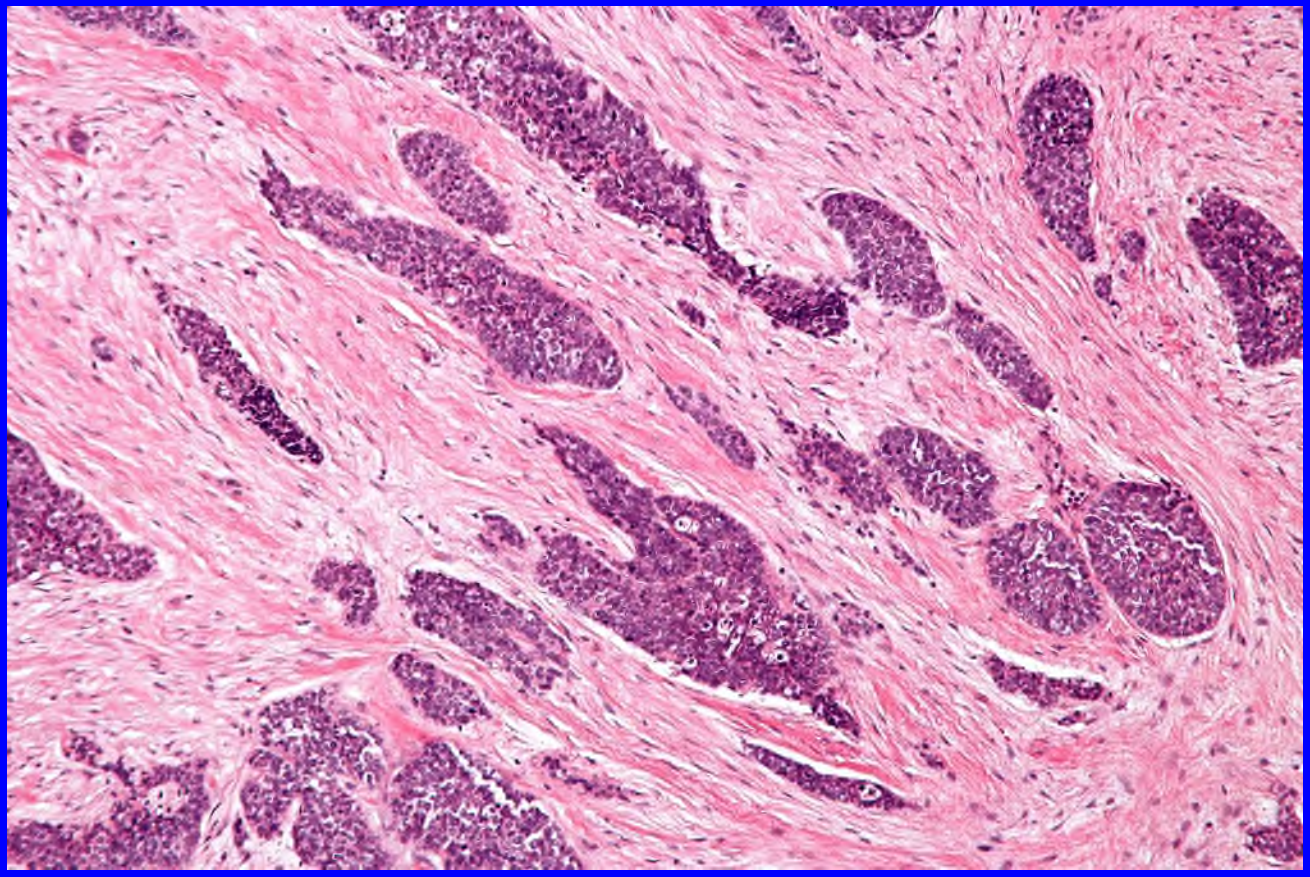

D-SRCT,Kidney,No desmopl, geographic necr+, calcif+, RC,Myxoid matrix Wang L 2007

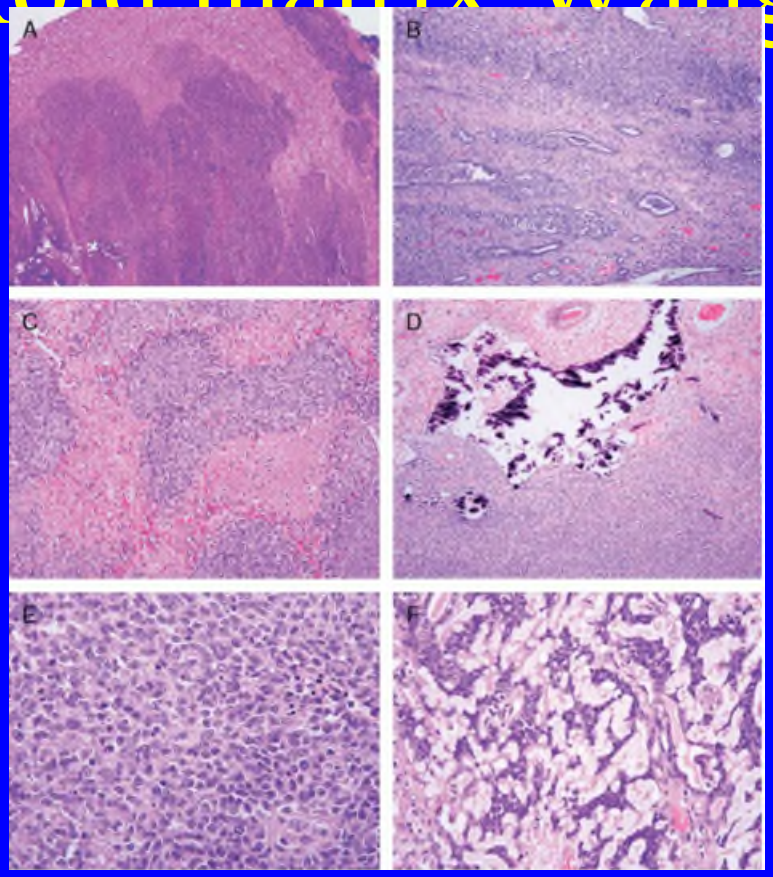

D-SRCT-Intermediate junctions & whorls of I filaments -Wang LL AJSP 2007;31:576

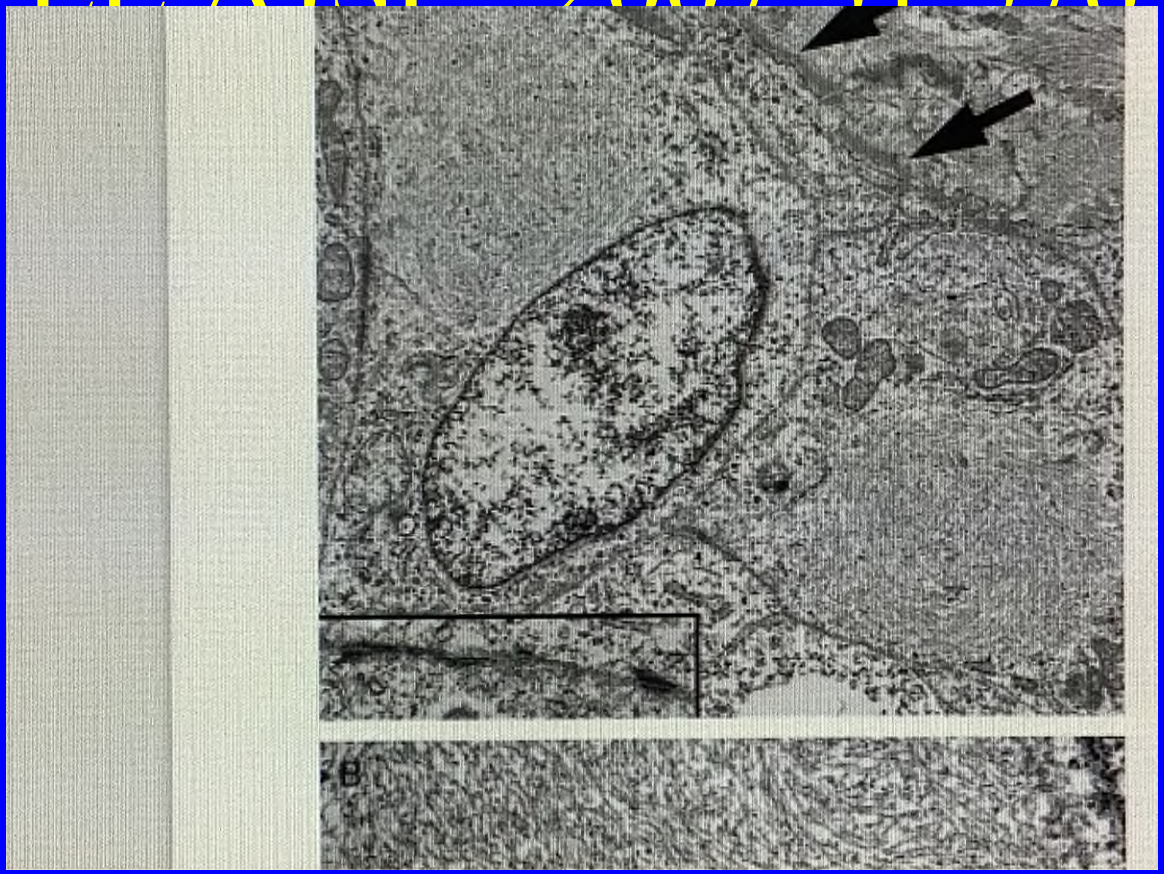

EEFTs:Second histologic subgroups of Non-ES

- 1.FET-Non ETS fusion sarcoma :

a. EWS-NFATC2 fusion sarcoma

b. EWS-PATZ1 fusion sarcoma

- 2. D-SRCT (EWS-WT1)
- 3. CIC-DUX4 (or other gene) fusion sarcomas

EEFTs:Dx (Clues from routine Tumor Cell cytology/histology)

- Second subgroup of Non-ES – Features providing clues to Non-ES other than BCOR Rarragd sarcoma

Brisk mitosis (av 30/10 hpf)

Focal rhabdoid change:

CIC Rearranged sarcoma

Smith SC 2015:CIC rearrgd RCs + spindle cells b:myxoid change c/f:nucleoli d:necr e:brisk mitosis

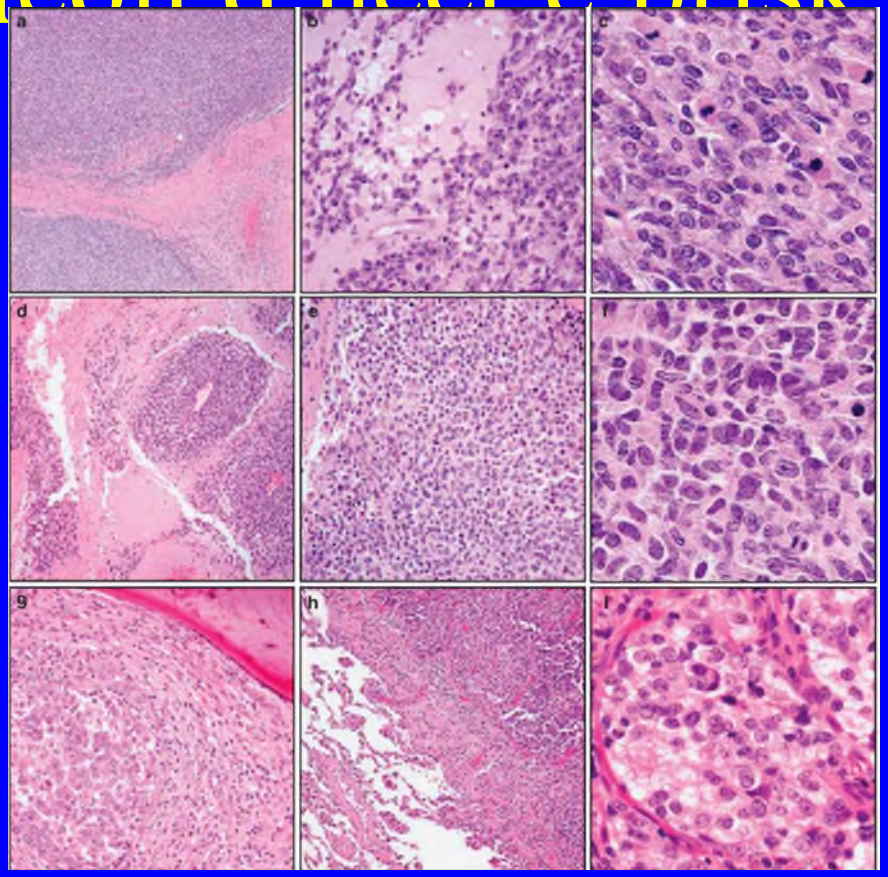

CIC rearg sarc-Machado I:Ann Dx Path2016;22:25 Rhabd,CD99, WT1

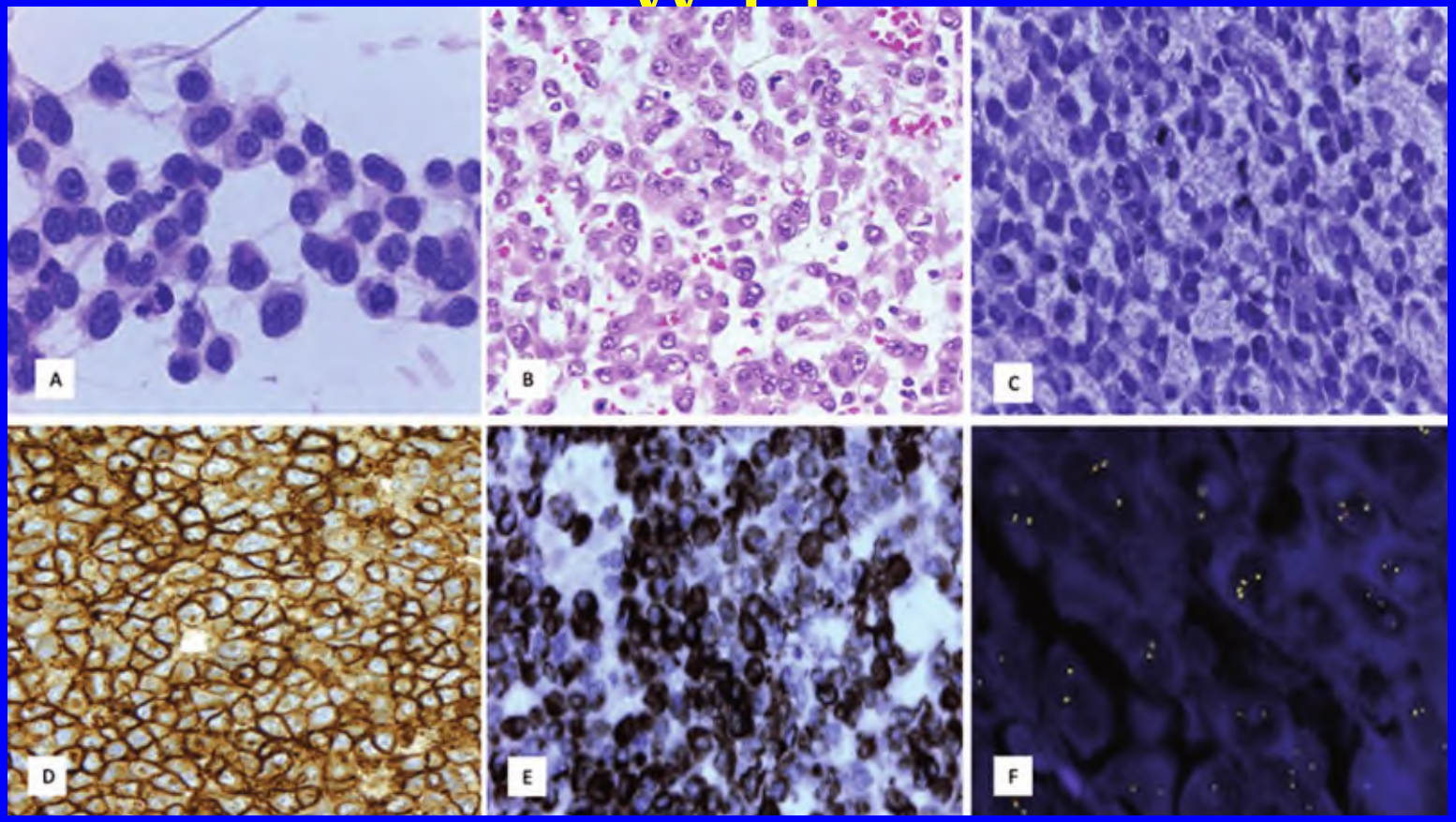

EEFTs:Dx (Clues from routine Tumor Cell cytology/histology)

- Two groups on the basis of clues from basic cellular features: ES & Non-ES

1.EEFT with SINGLE cell type - uniform evenly spaced RCs, generally low mitotic activity : ES, typical

2.EEFTs generally with TWO cell types - unevenly spaced RCs & spindle cells, variable but generally atypia of one/both cell types, generally moderate mitotic activity: Non-ES

EEFTs:Dx (Clues from routine Tumor Cell cytology/histology)

- Two groups on the basis of clues from basic cellular features:
- ES (uniform evenly spaced RCs without atypia)
- Non-ES (unevenly spaced RCs + Spindle cells,variable atypia)

Non-ES divided into two subsets

EEFTs:Dx (Clues from routine Tumor Cell cytology/histology)

- Non-ES divided into two subsets
- BCOR Rearrgd sarcomas (minimal atypia, four elements and classic pattern with chicken wire capillaries)
- Non-BCOR Rearrgd sarc (moderate atypia):
- EWS-NFATC2 EWS-PATZ1
- D-SRCT(EWS-WT1) CIC Rearrgd sarcomas
- (Patterns- desmoplasia; brisk mitosis}

EEFTs:Next steps

.Request ICC stains from the ICC profile which fits the working Dx based on clinical and histologic profile (focused ICC stains)

.Request targeted test(s) for molecular genetic marker for making definitive Dx if ICC profile confirms the working Dx