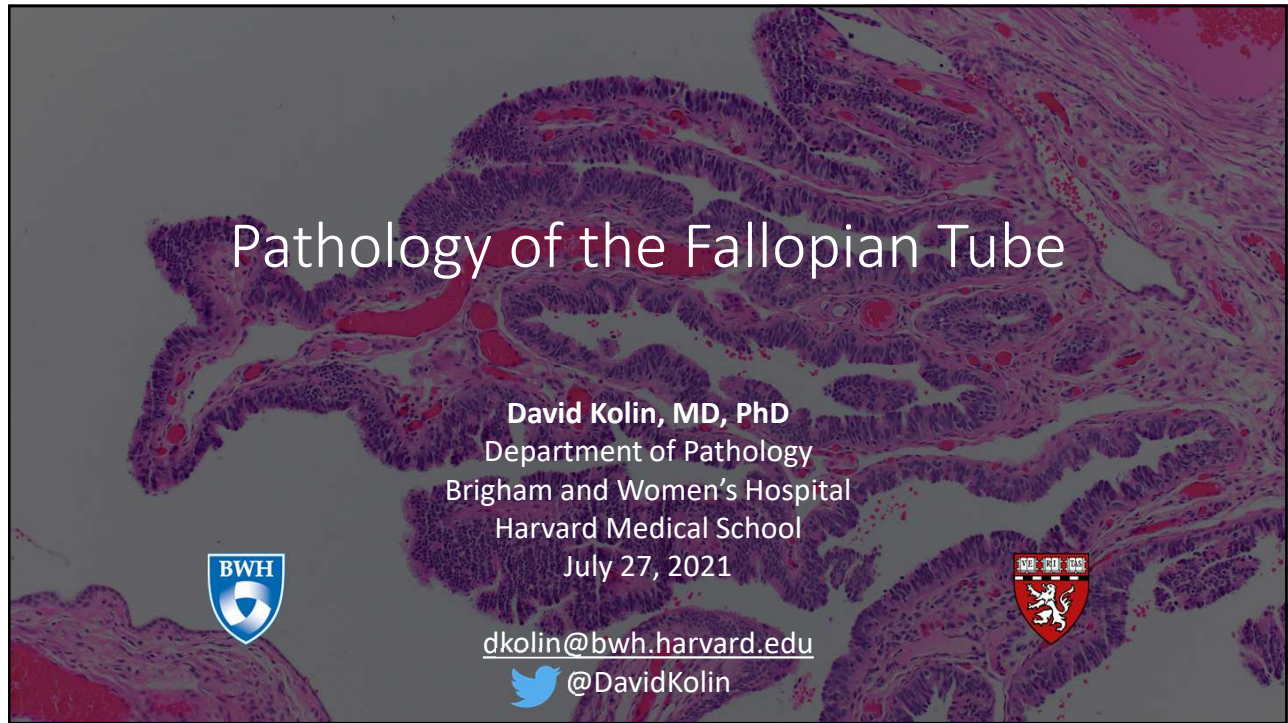


Pathology of the Fallopian Tube

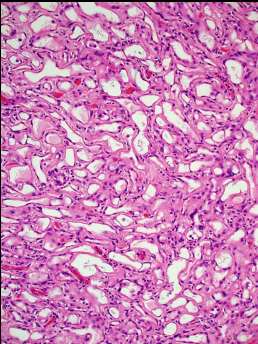
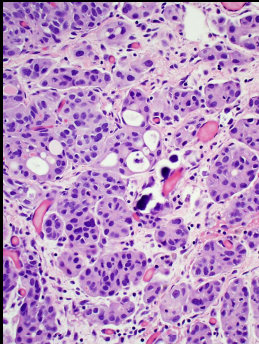
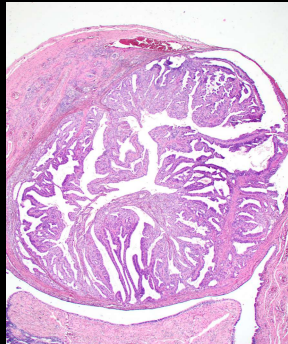
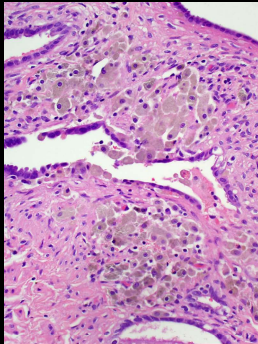
David Kolin, MD, PhD
Department of Pathology
Brigham and Women's Hospital
Harvard Medical School
July 27, 2021

dkolin@bwh.harvard.edu
[@DavidKolin](https://twitter.com/DavidKolin)



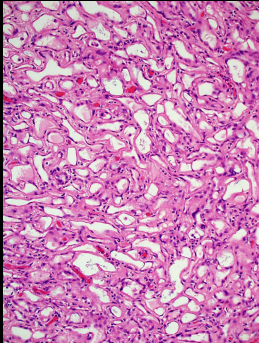
1

Outline

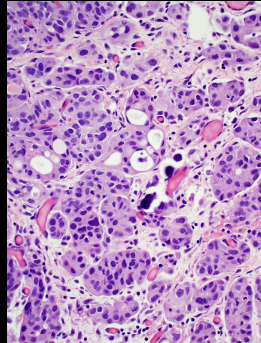
			
Mesothelial neoplasia	Serous neoplasia	Endometrioid neoplasia	Tubal doodads: infectious, inflammatory, and other

2

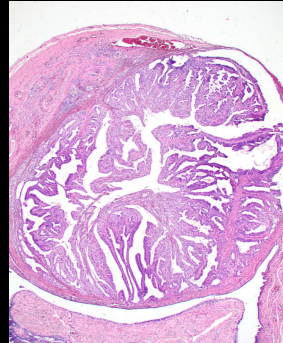
Outline



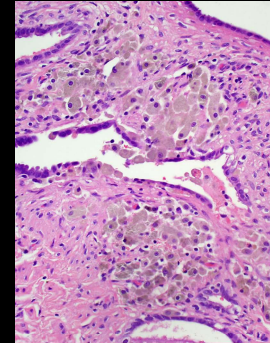
Mesothelial
neoplasia



Serous
neoplasia



Endometrioid
neoplasia



Tubal doodads:
infectious,
inflammatory,
and other

3

Mesothelial tumors of the tube

- Adenomatoid tumor
- Malignant mesothelioma
- Well-differentiated papillary mesothelial tumor

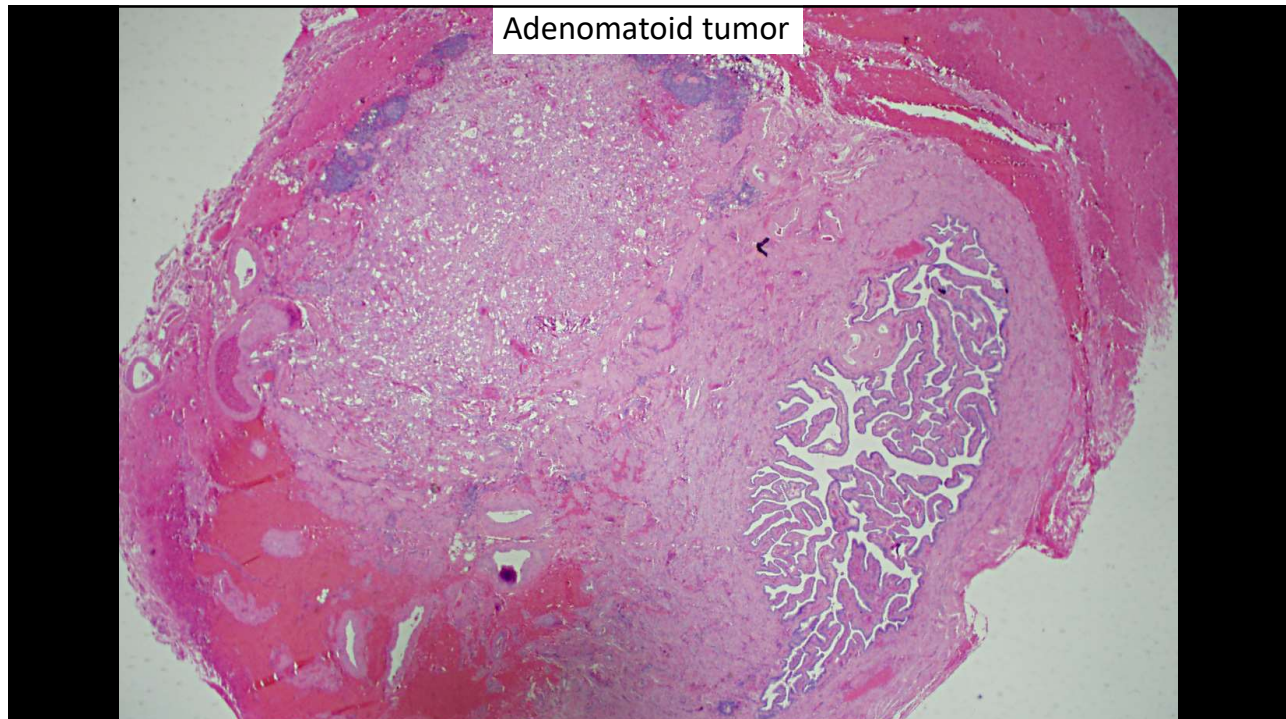
4

Adenomatoid tumors

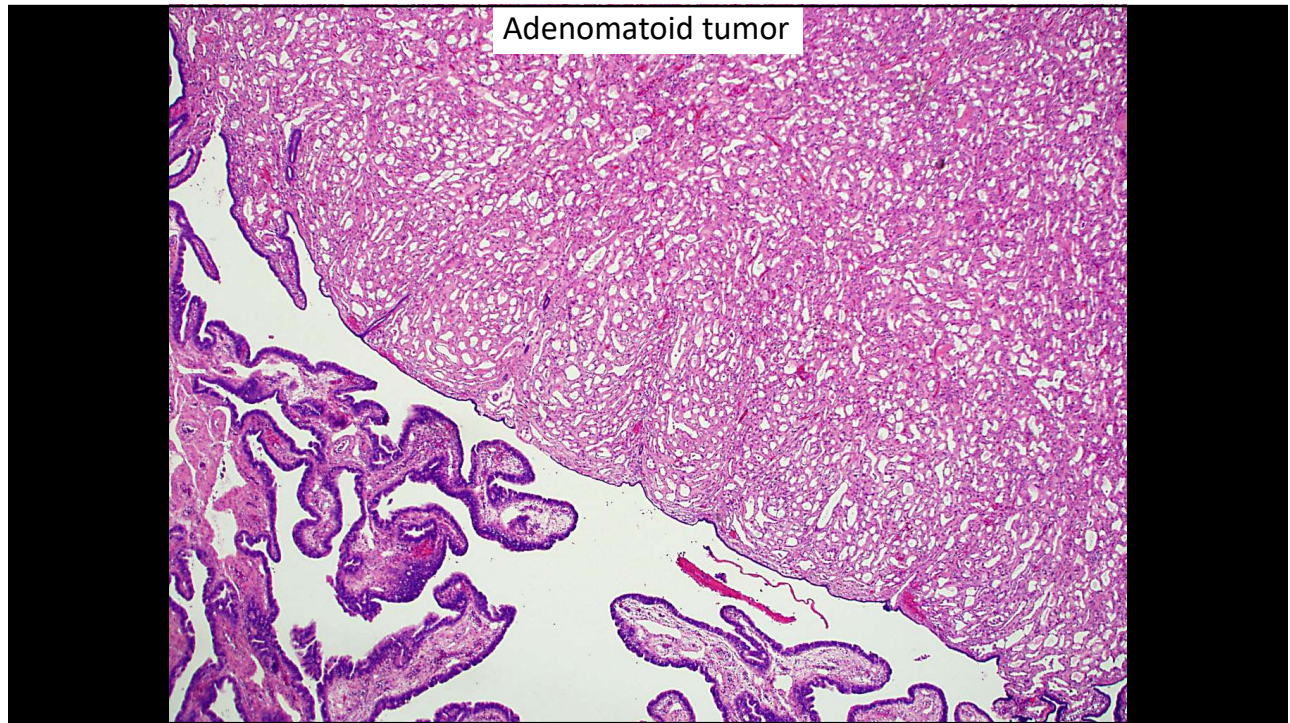
- Most common benign tumor of tube
- Mesothelial-derived proliferations
- Occur in the uterus, tube, ovary, paratesticular
- Gross: solid tan-white nodules, usually smaller than 2 cm
- In the tube, well-circumscribed (lack the infiltrative border seen in uterus)
- Variety of architectures/morphology: angiomatoid, tubular, solid, lipoblast-like, signet-ring cell
- Cytologic atypia (bizarre/symplastic-type atypia)
- Missense mutations in *TRAF7*

Goode et al. Mod Pathol. 2018;31(4):660-673.

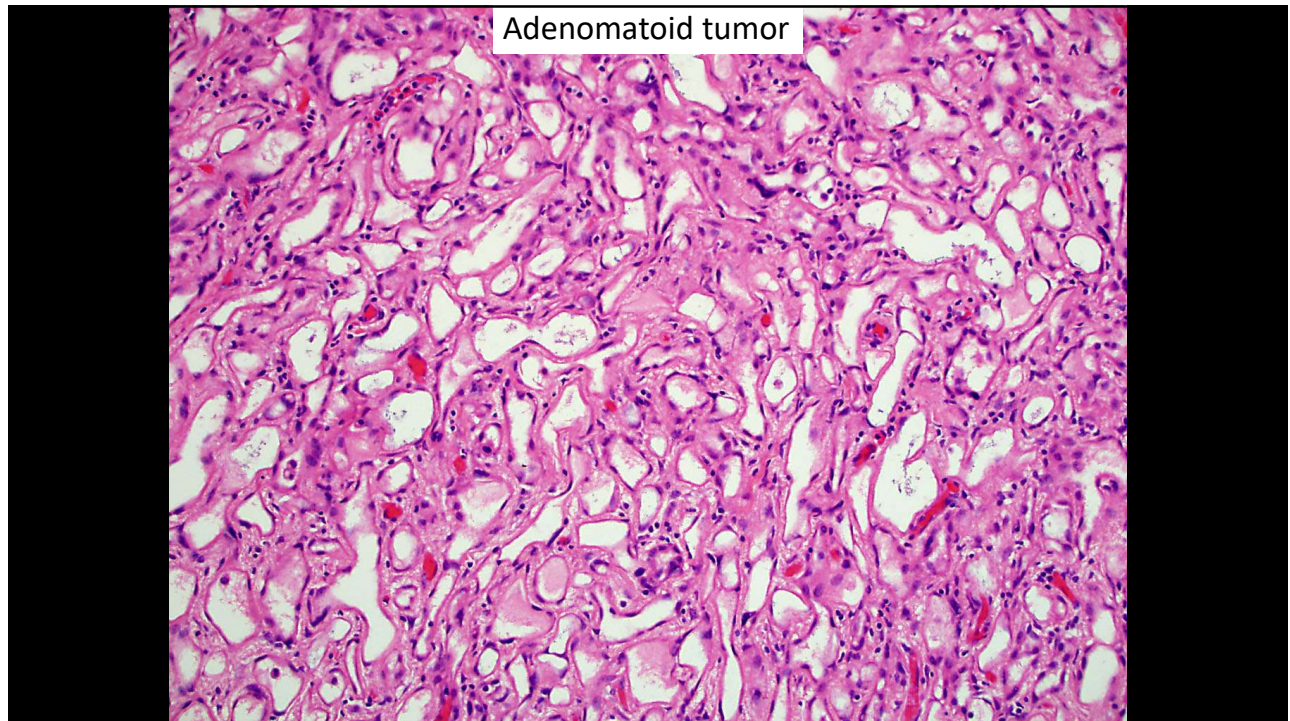
5



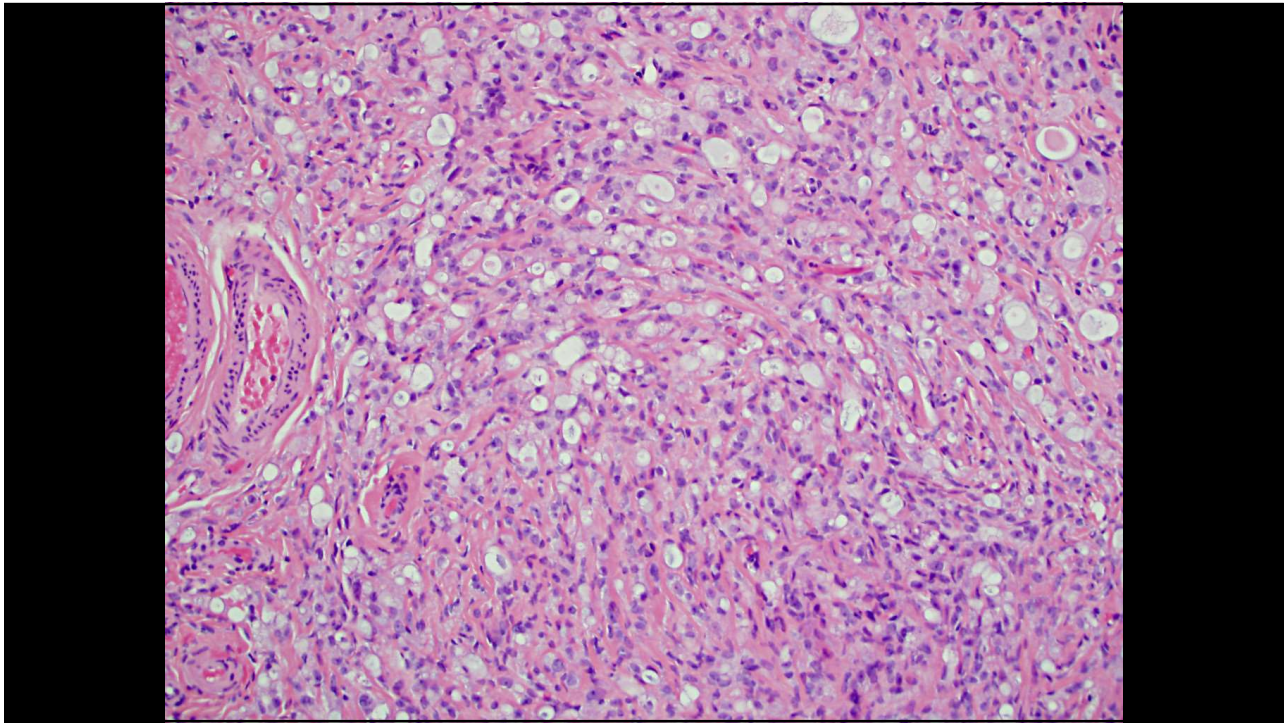
6



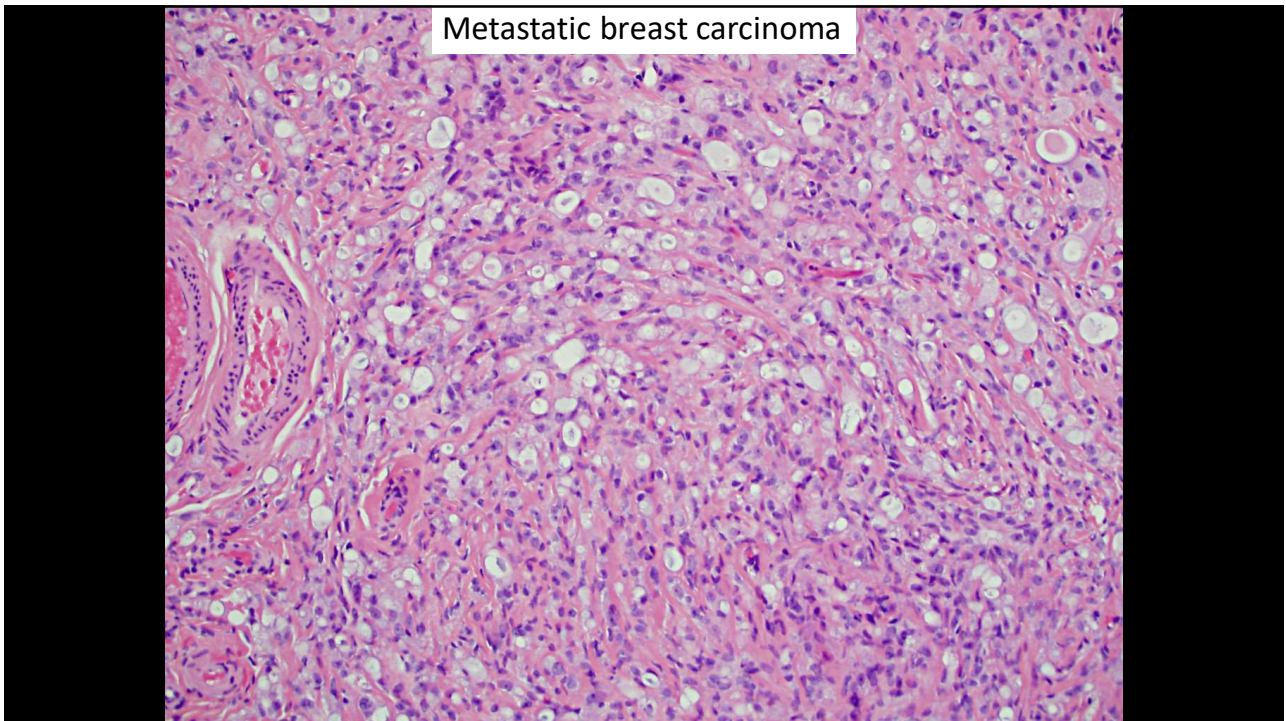
7



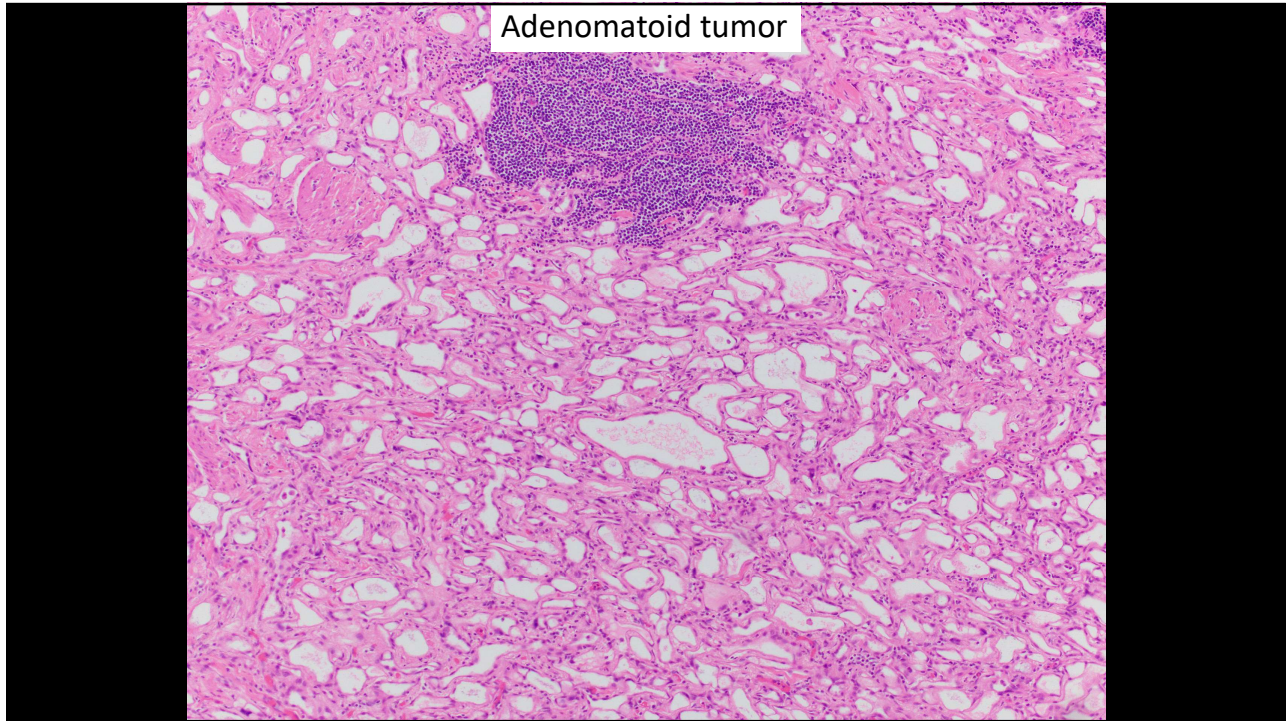
8



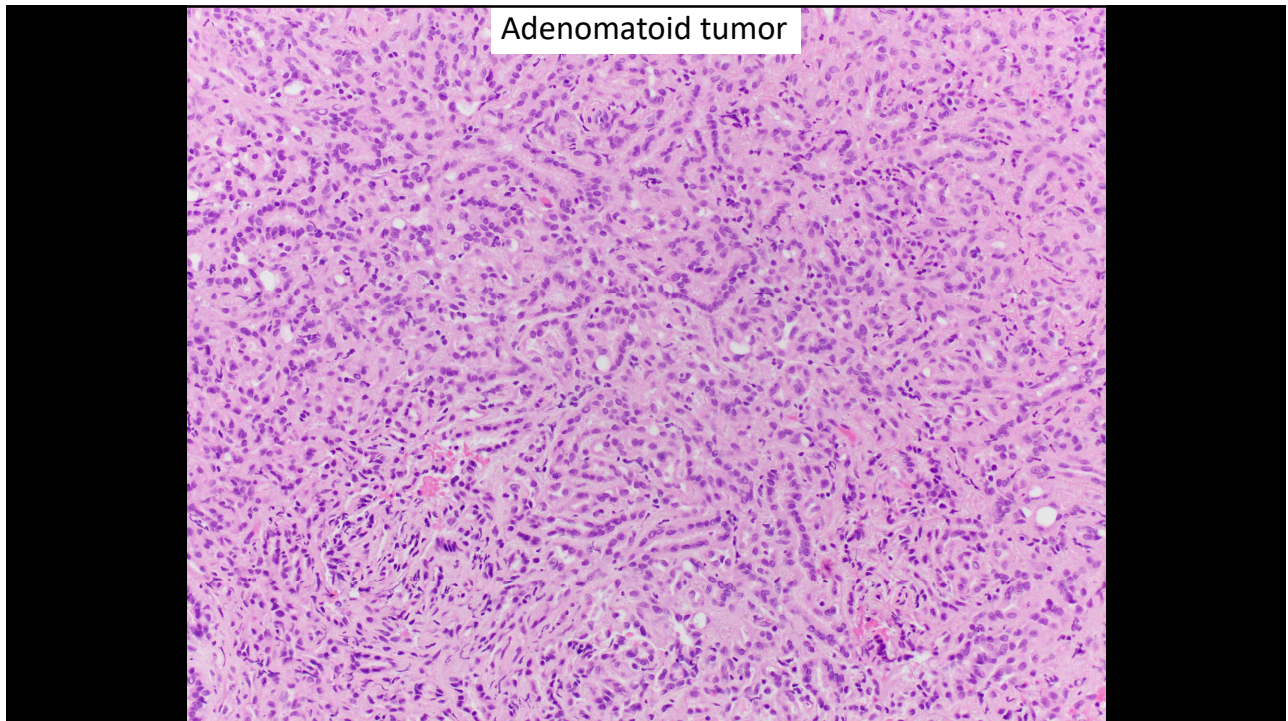
9



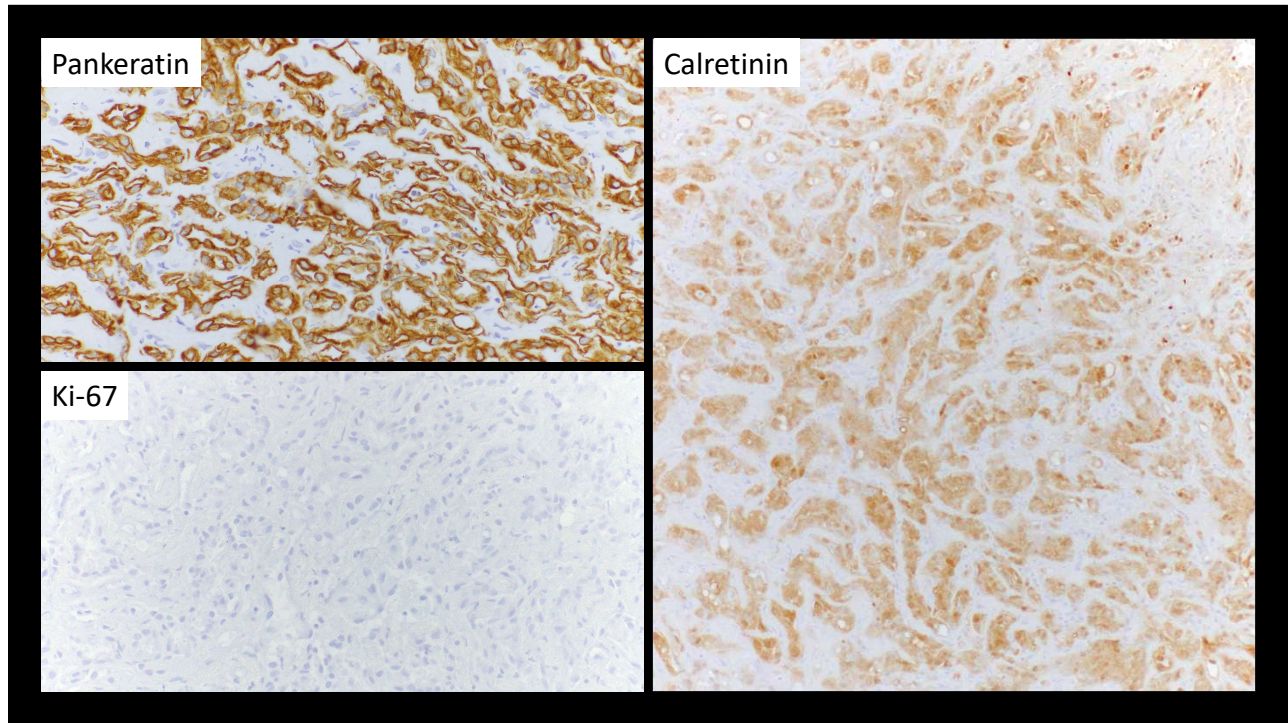
10



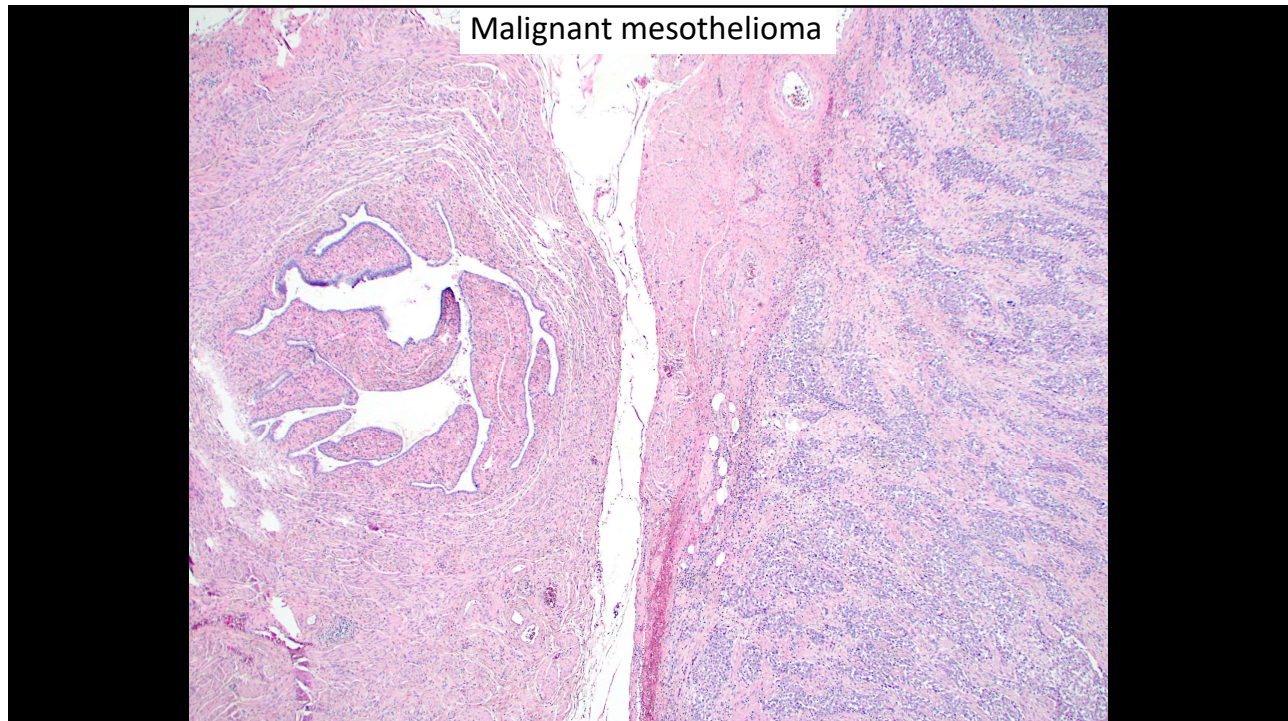
11



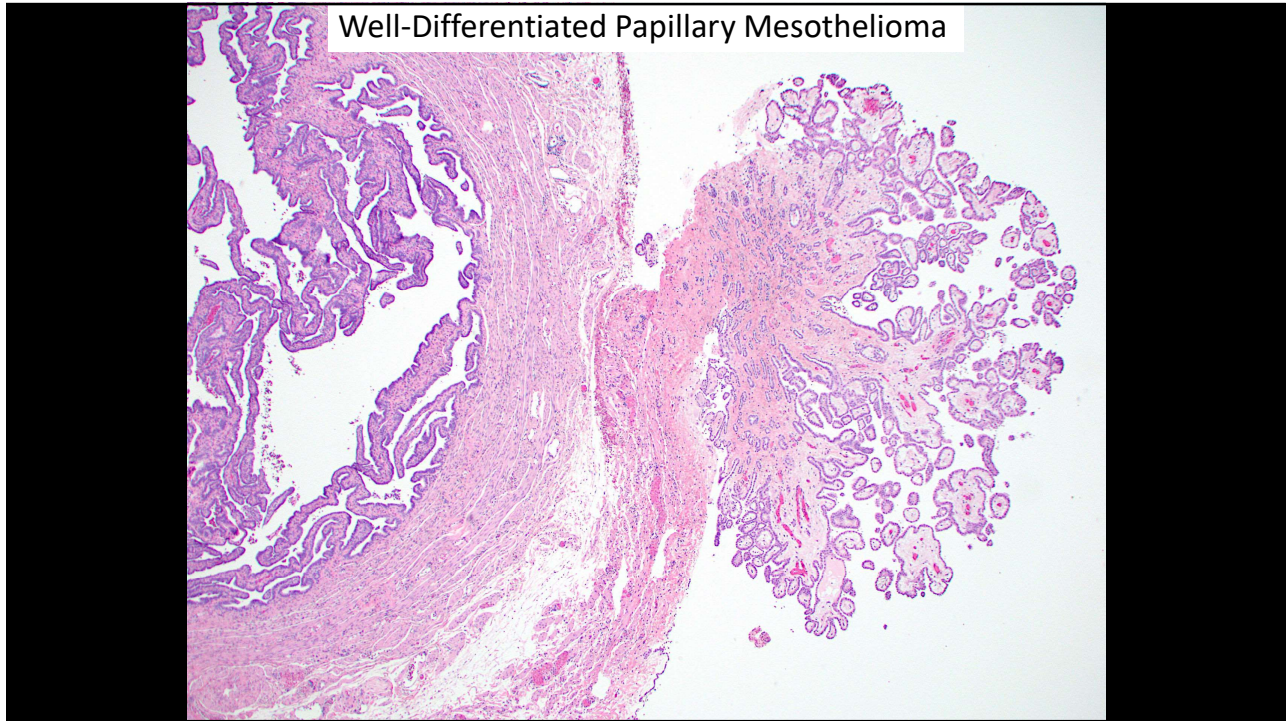
12



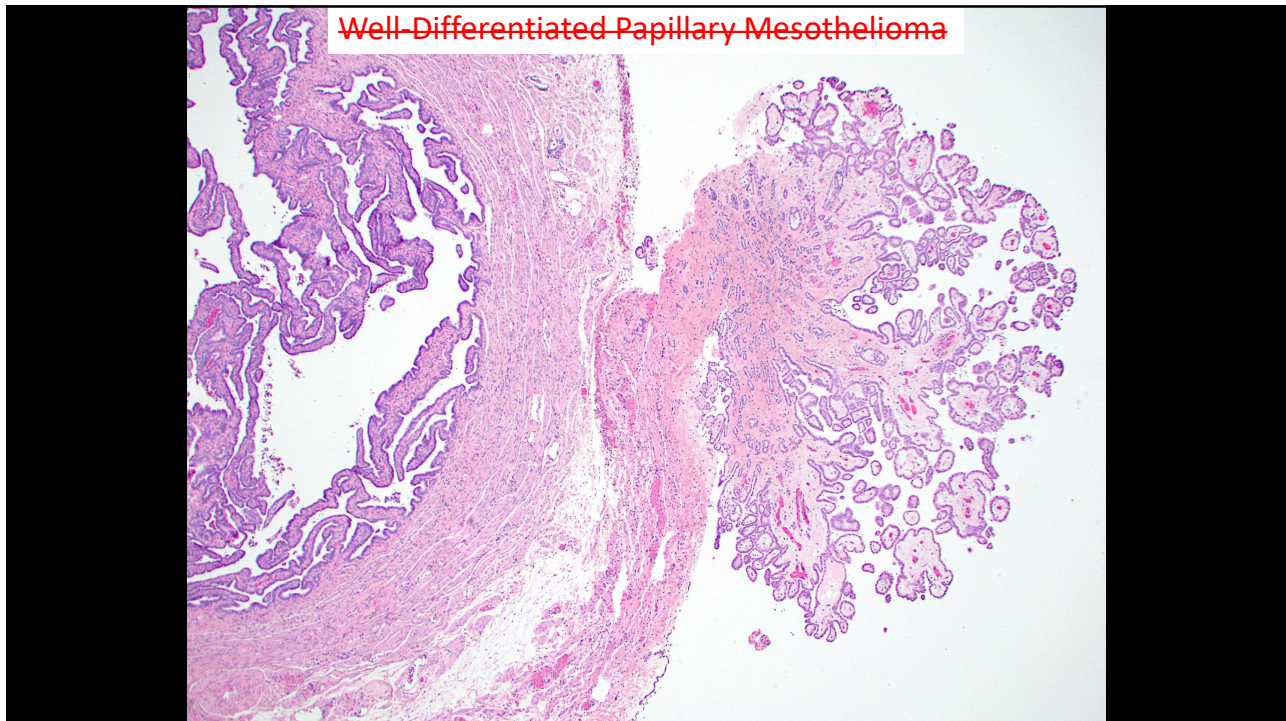
13



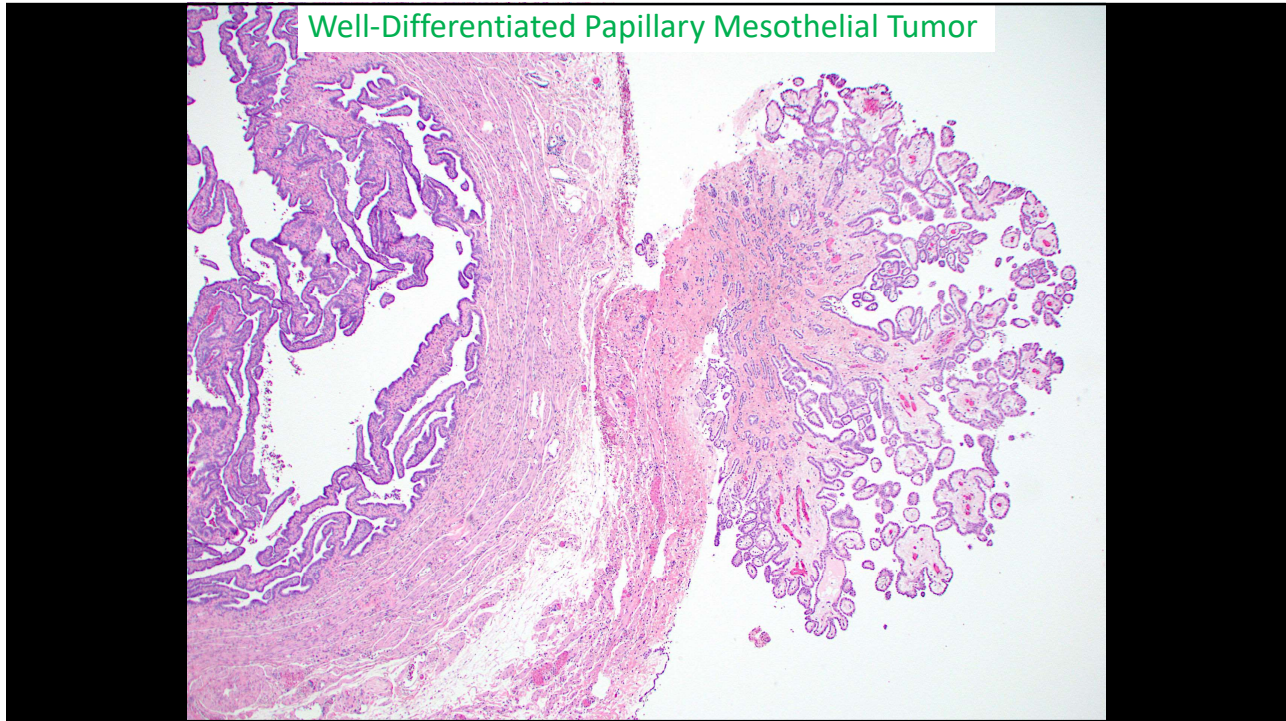
14



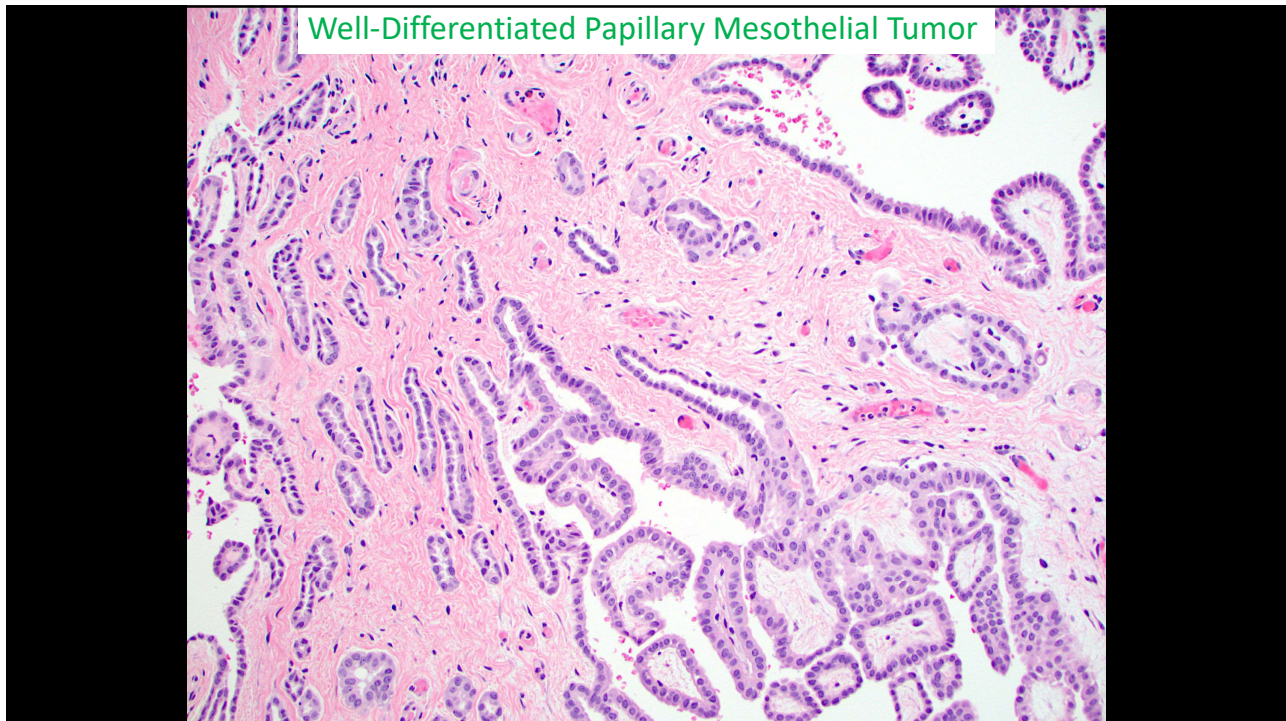
15



16



17



18

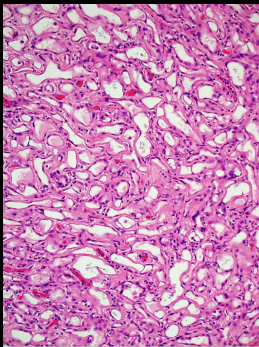
Well-differentiated papillary mesothelial tumor

- Incidentally found in middle aged women
- Involves peritoneum, omentum
- Single or multiple
- Architecture: Papillary, less common: glands/tubules, nests
- Bland cytology
- No invasion
- *TRAF7* or *CDC42* mutations
- IHC: +WT-1, calretinin, L1CAM, BAP1 (intact)
- Benign (may recur if incompletely excised)

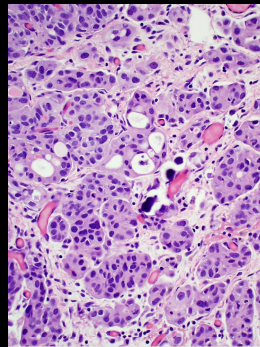
Stevens et al, Mod Path. 2019;32:88-99.

19

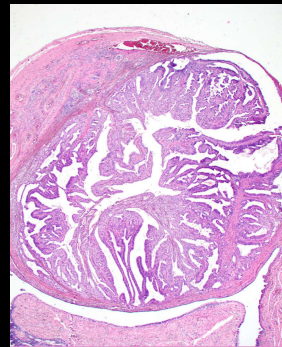
Outline



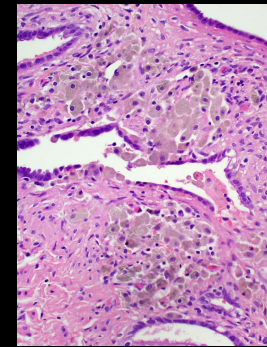
Mesothelial
neoplasia



Serous
neoplasia

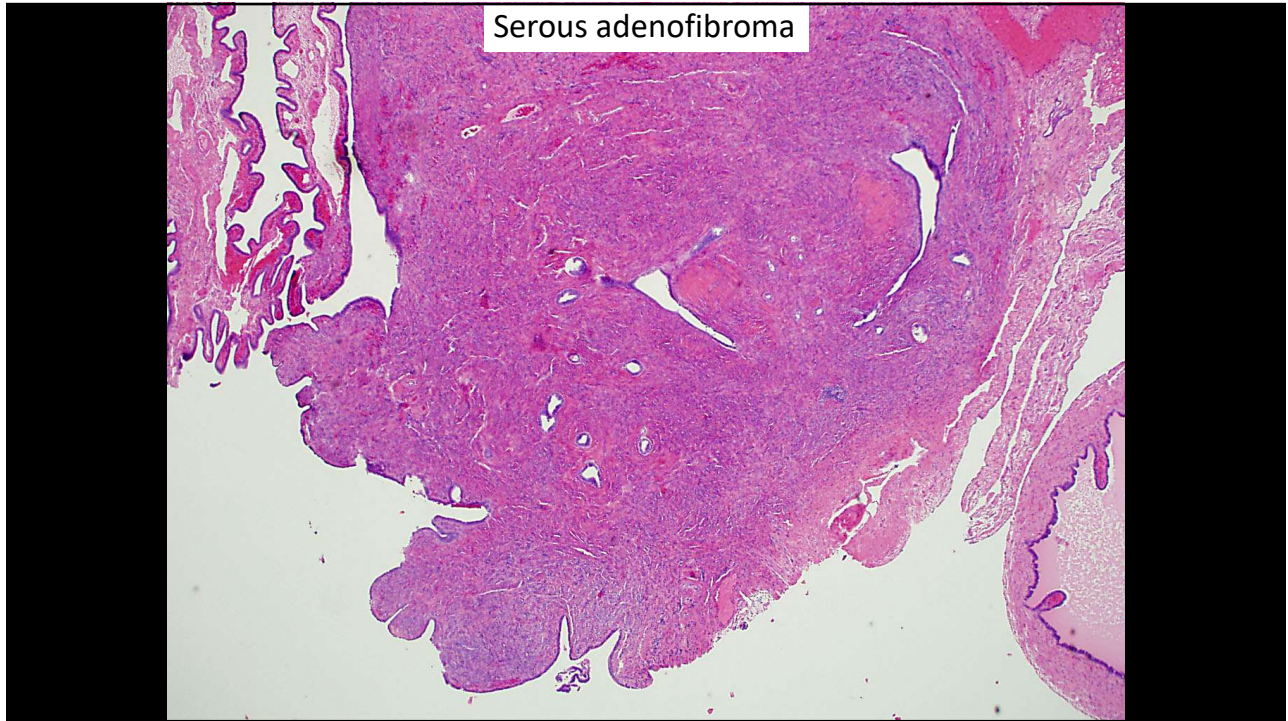


Endometrioid
neoplasia

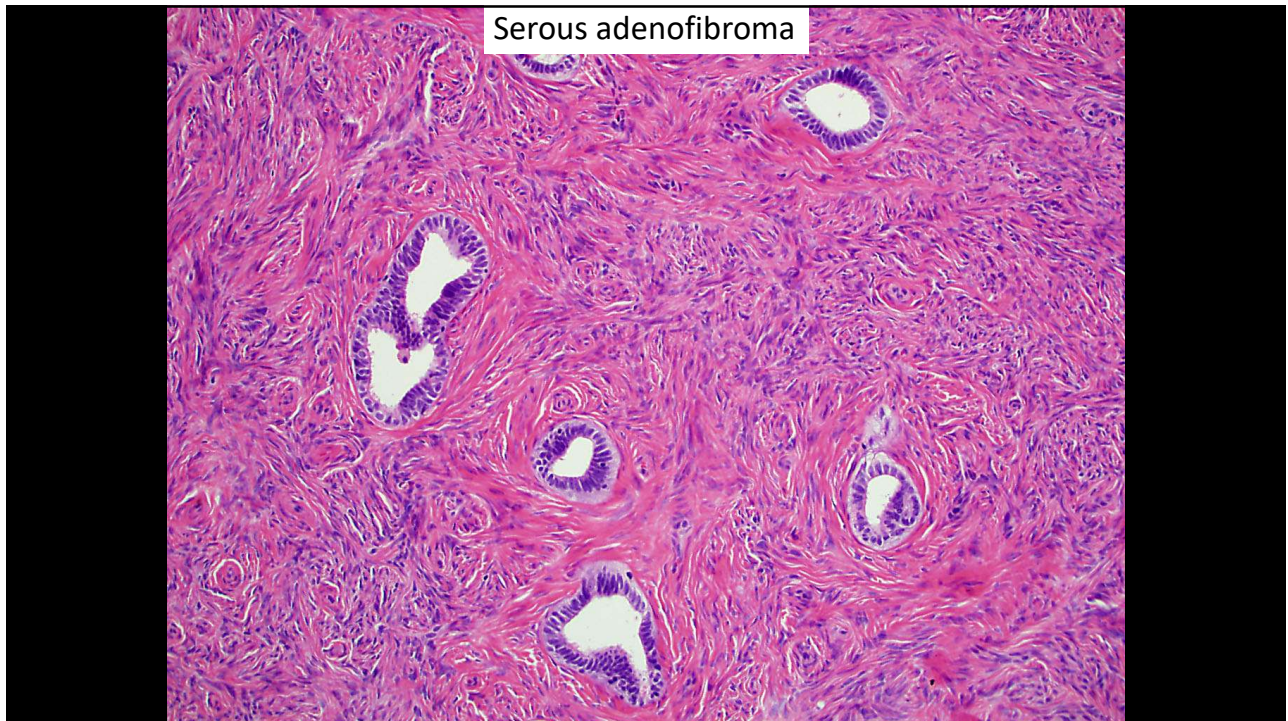


Tubal doodads:
infectious,
inflammatory,
and other

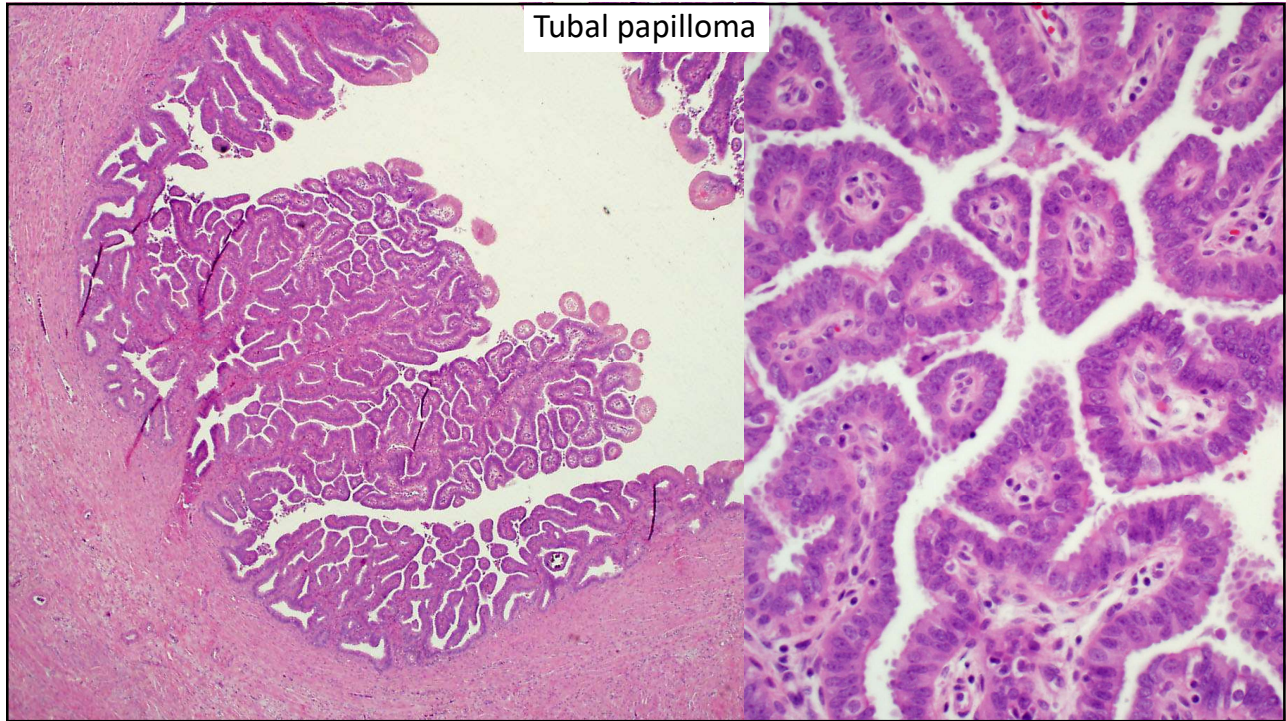
20



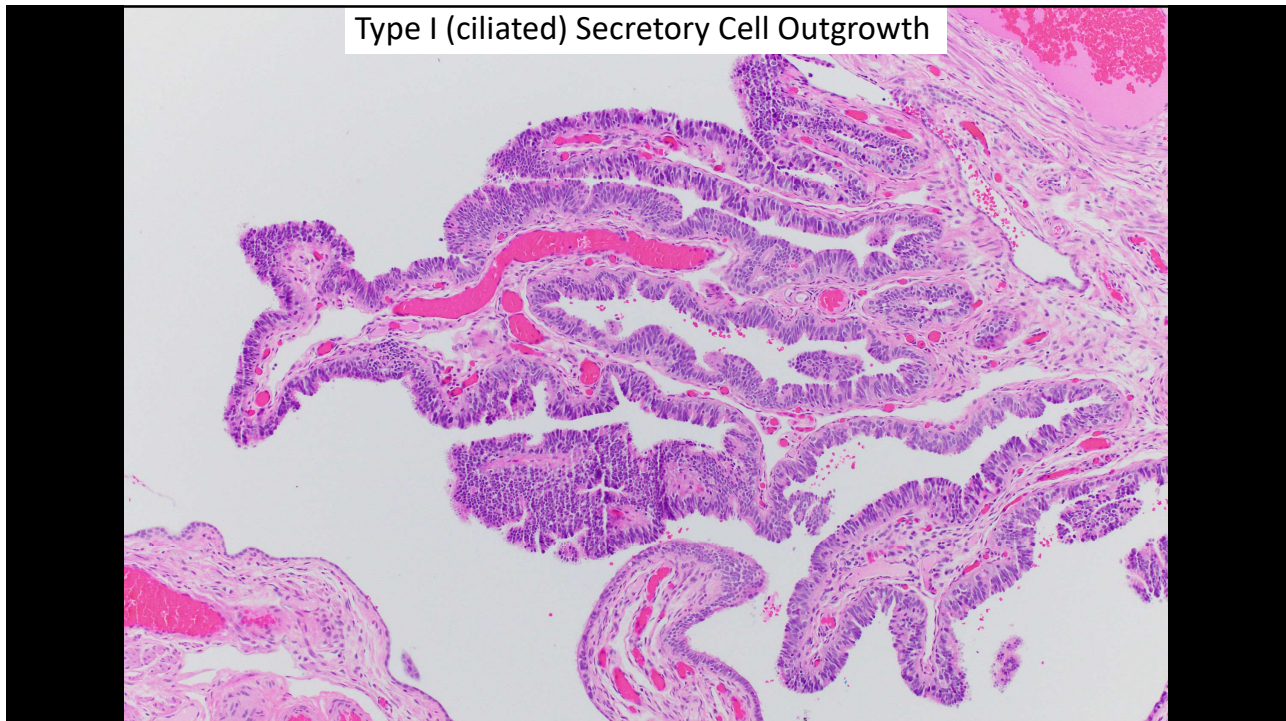
21



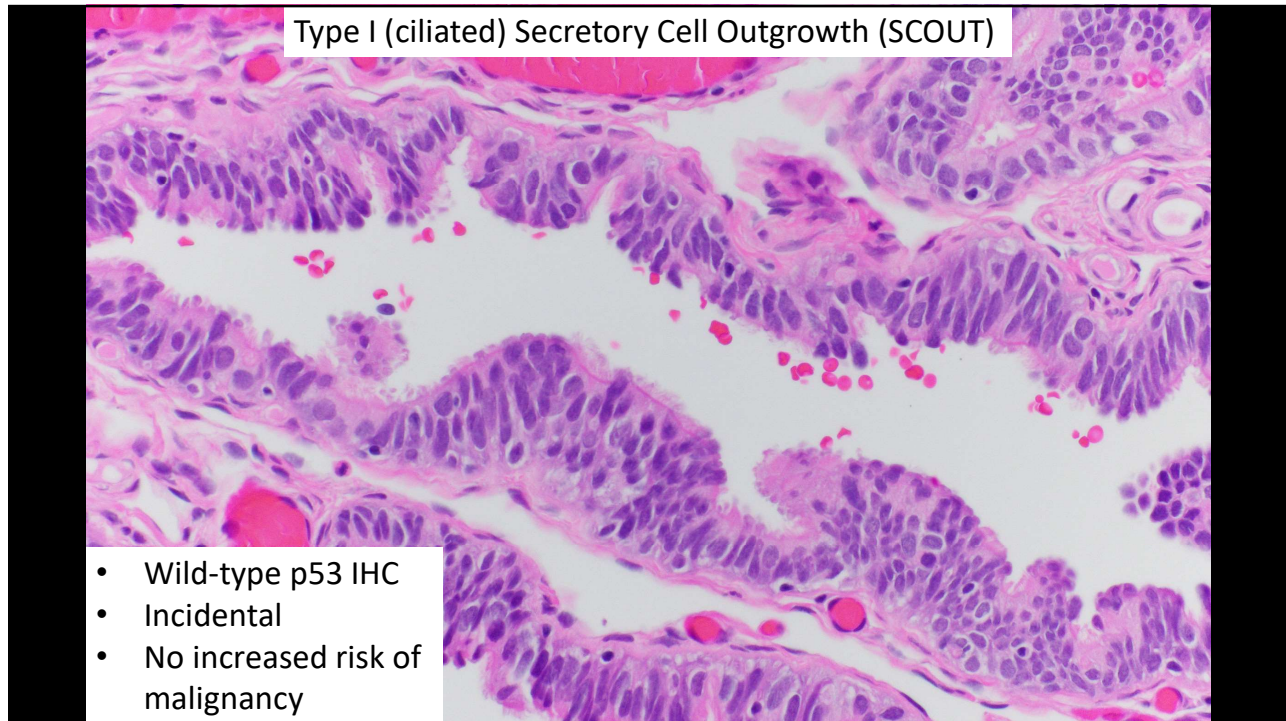
22



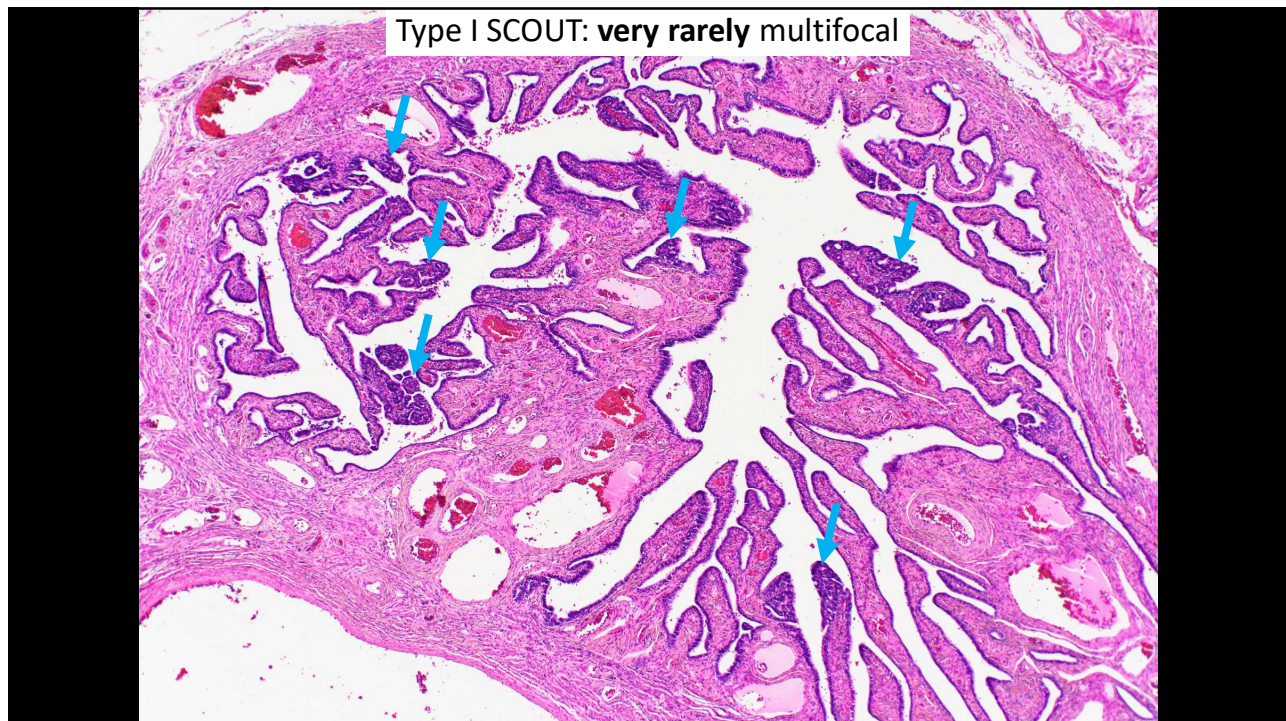
23



24

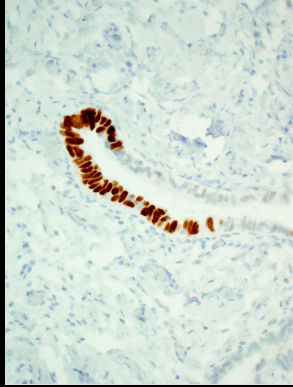

25

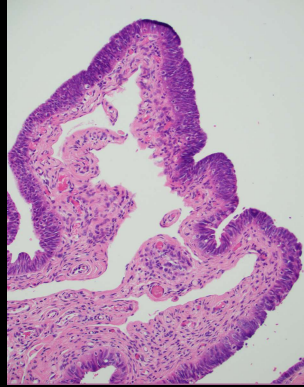


26

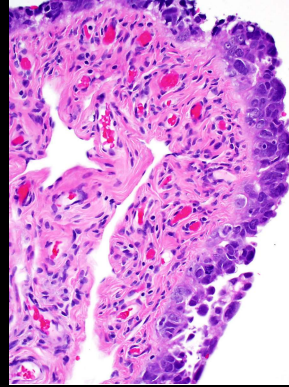
Spectrum of serous intraepithelial neoplasia



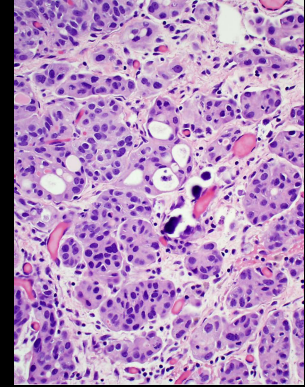
p53 signature



Serous tubal
intraepithelial
lesion (of uncertain
significance)



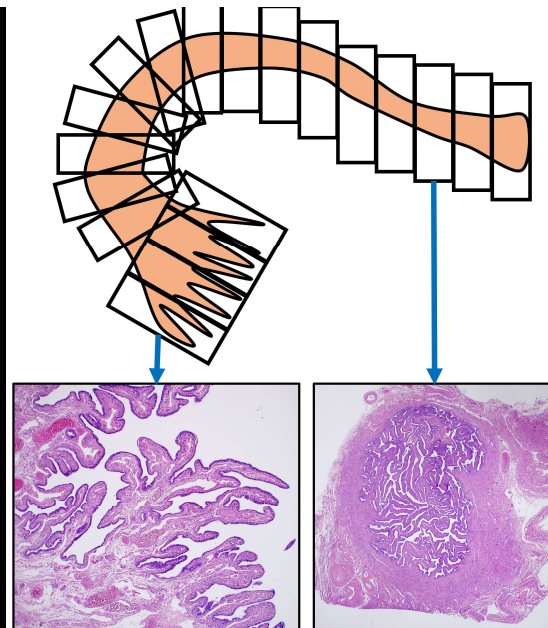
Serous tubal
intraepithelial
carcinoma



High grade
serous
carcinoma

27

Sectioning and Extensively Examining the FIMbriated End (SEE-FIM) Protocol



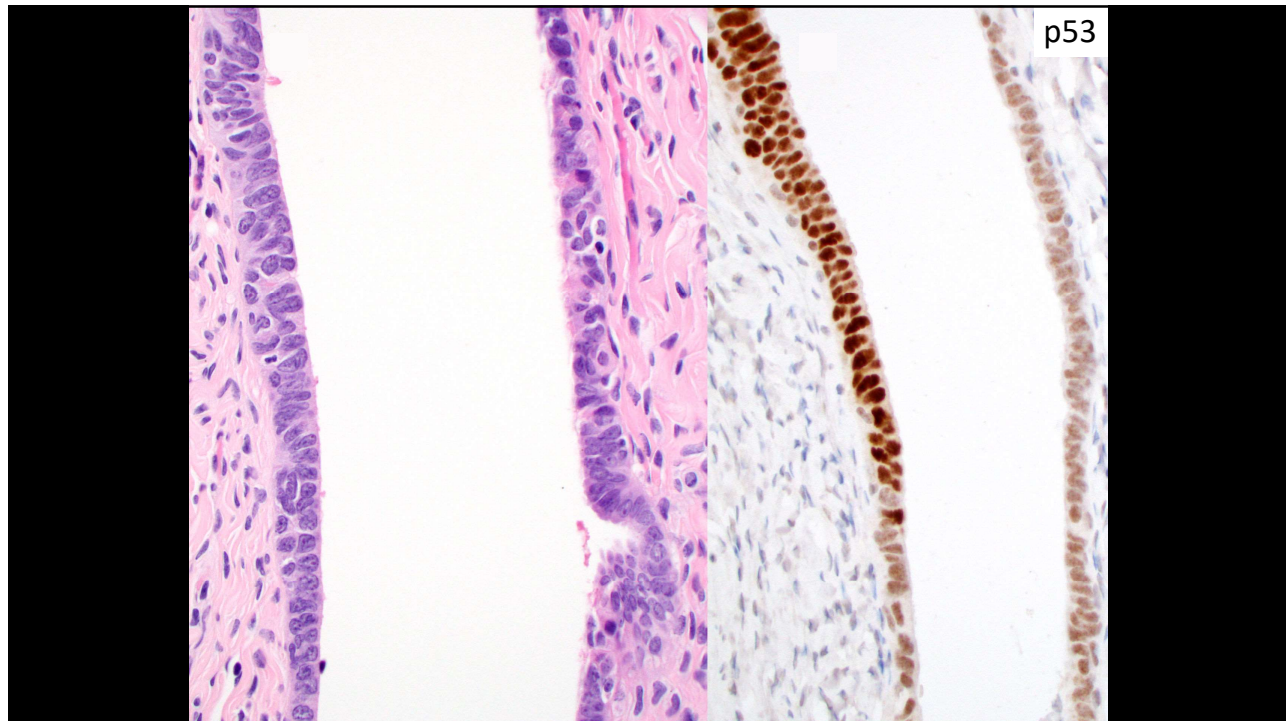
Medeiros et al. AJSP,
2006;30(2):230-6.

28

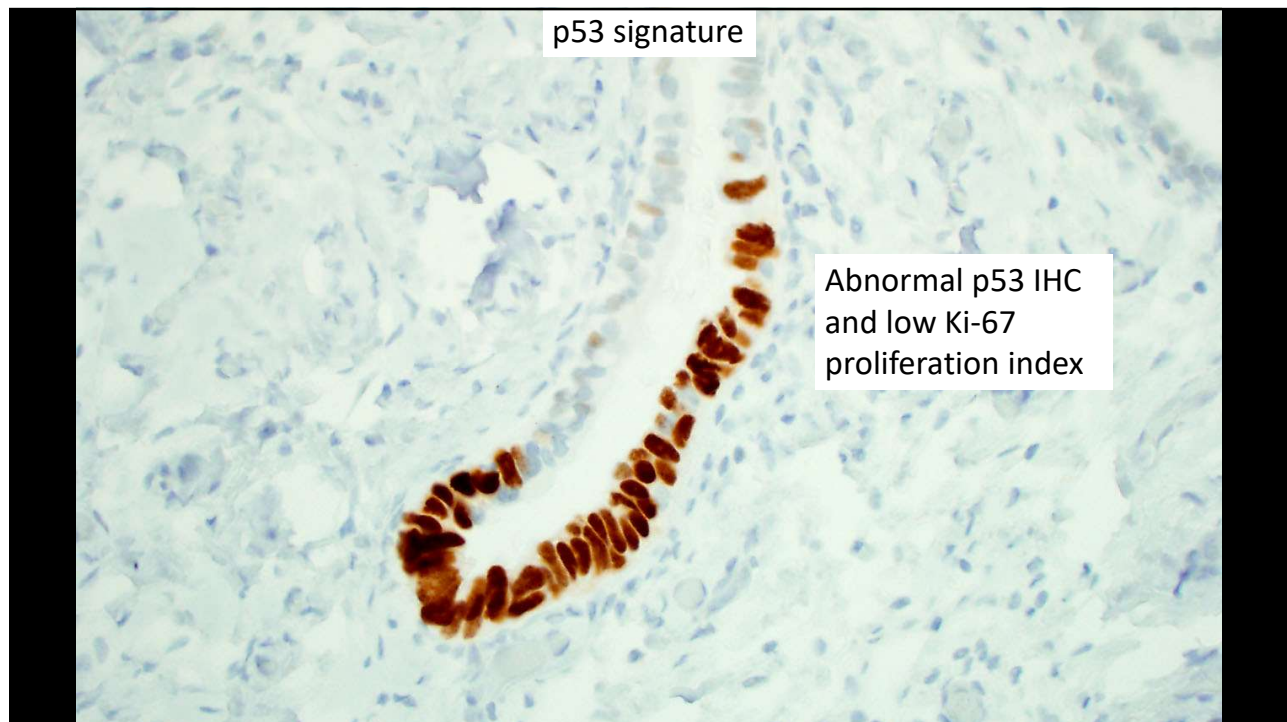
p53 signatures

- Common: 30-50% of tubes
- Most frequently in the fimbria
- Non-obligate precursors of serous carcinoma
- Evidence of early precursors of serous carcinoma
 - often found adjacent to a STIC
 - identical *TP53* mutations with concomitant STICs
 - Share risk factors with ovarian carcinoma (lower parity and older age at first childbirth)
- No clinical significance, usually not reported
- Pts with Li-Fraumeni have abundant p53 signatures, but no increased risk of ovarian ca

29



30

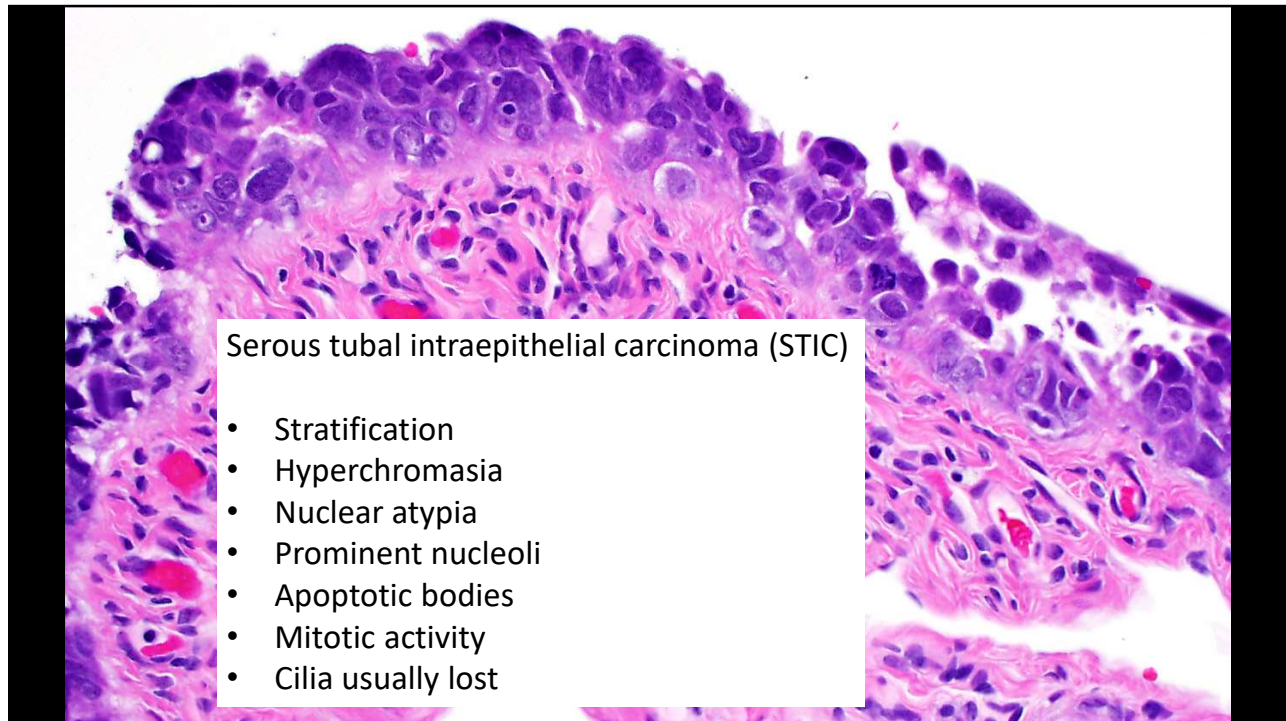


31

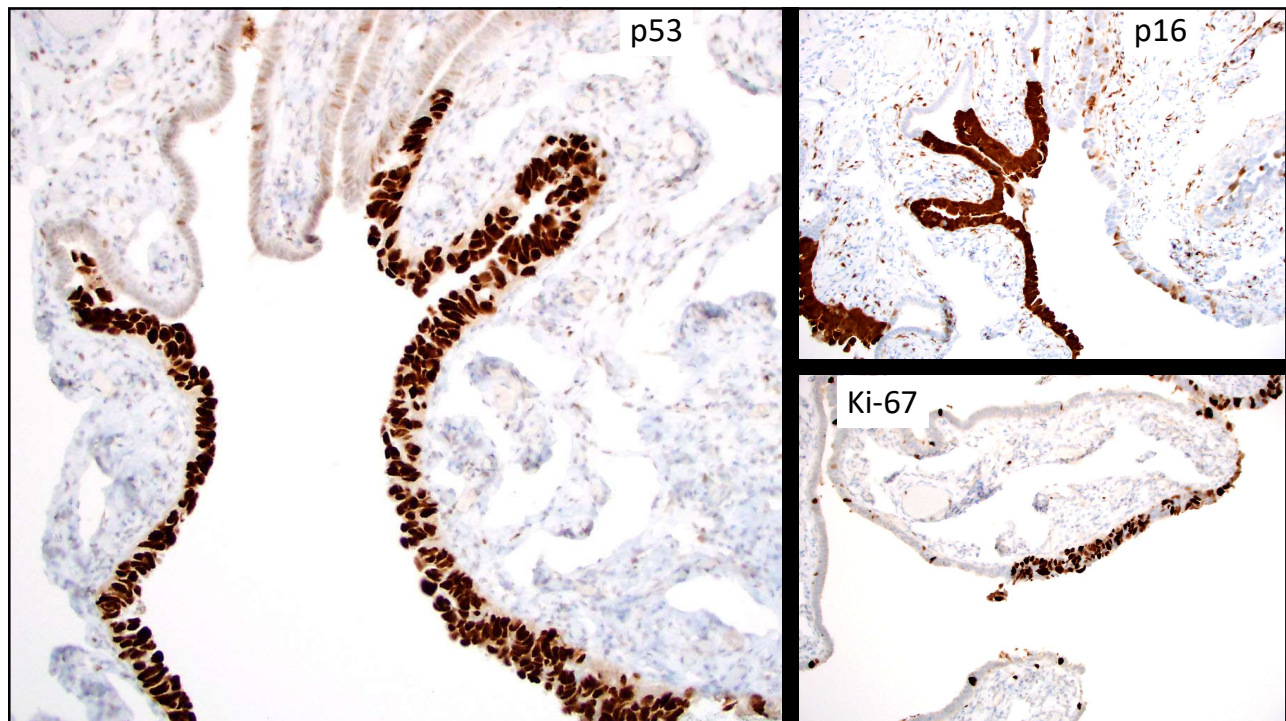
Serous tubal intraepithelial carcinoma

- Precursor of tubo-ovarian HGSC
- 22-67% of cases of HGSC have STIC
- 90% in fimbria
- 5-8% of risk reducing salpingo-oophorectomies (vs ~0.5% incidental)
- 4-11% will go on to develop HGSC later
 - Observation vs chemo?
 - Complete staging?

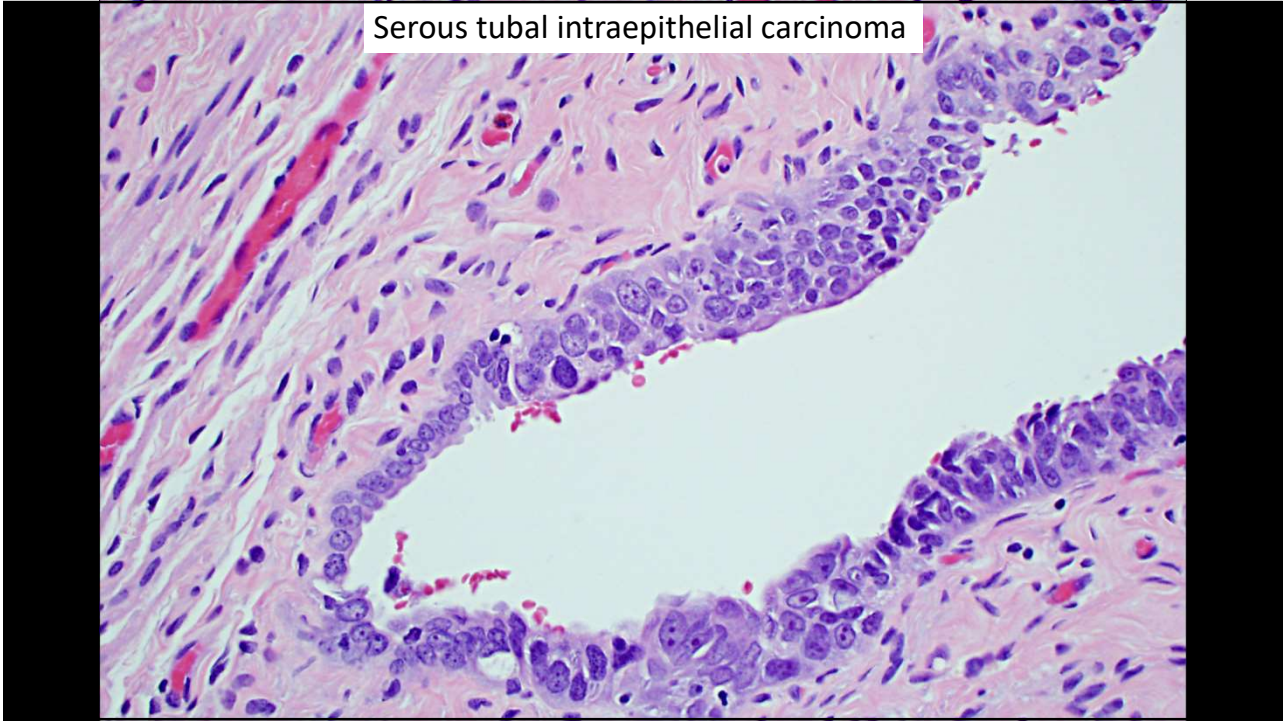
32



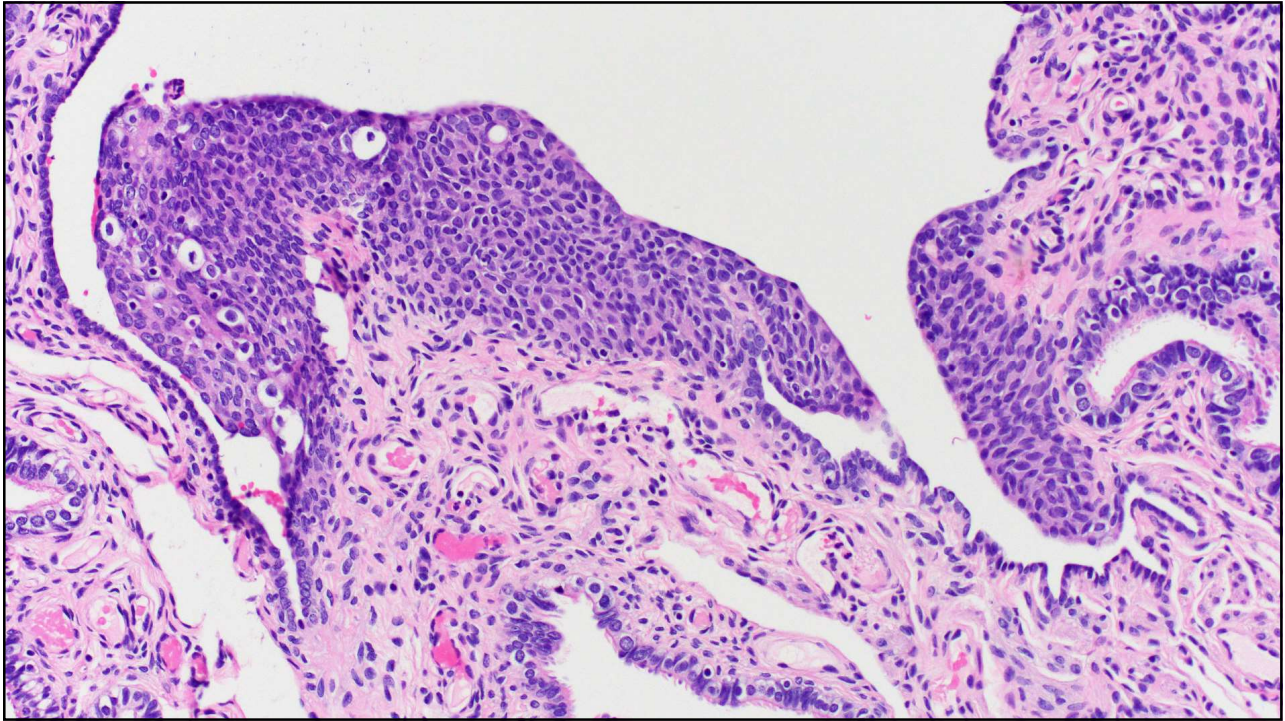
33



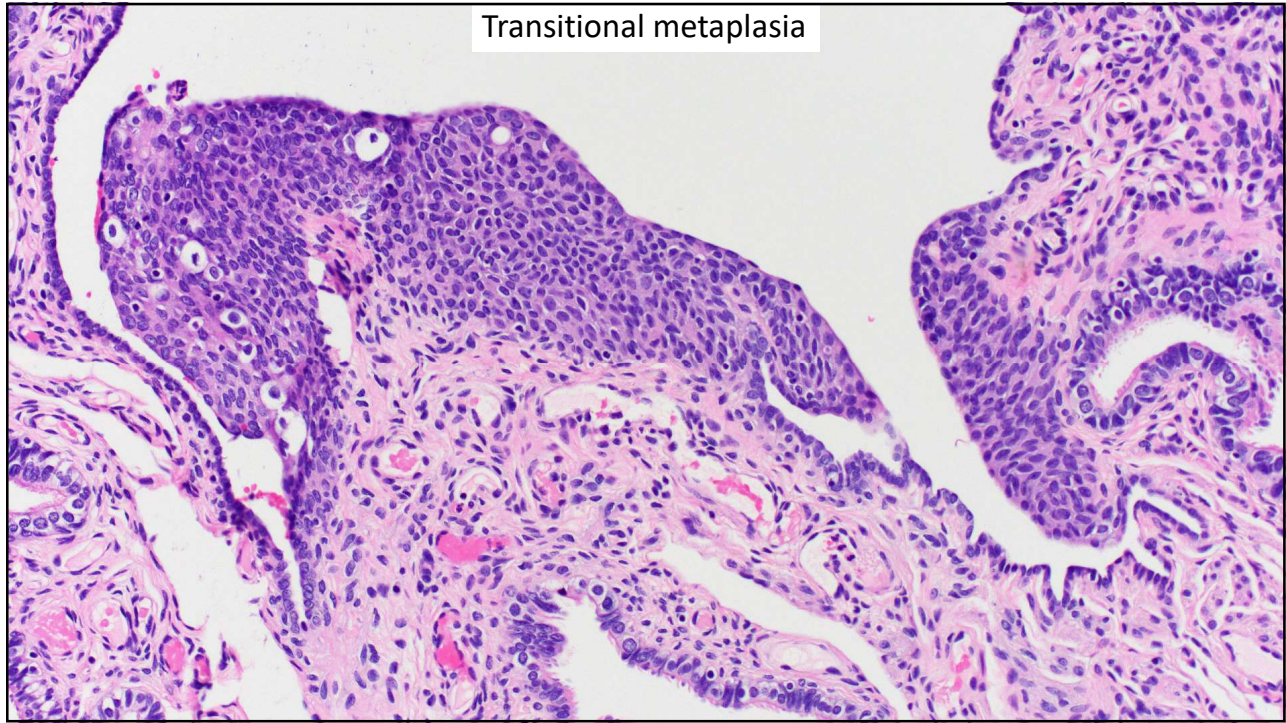
34



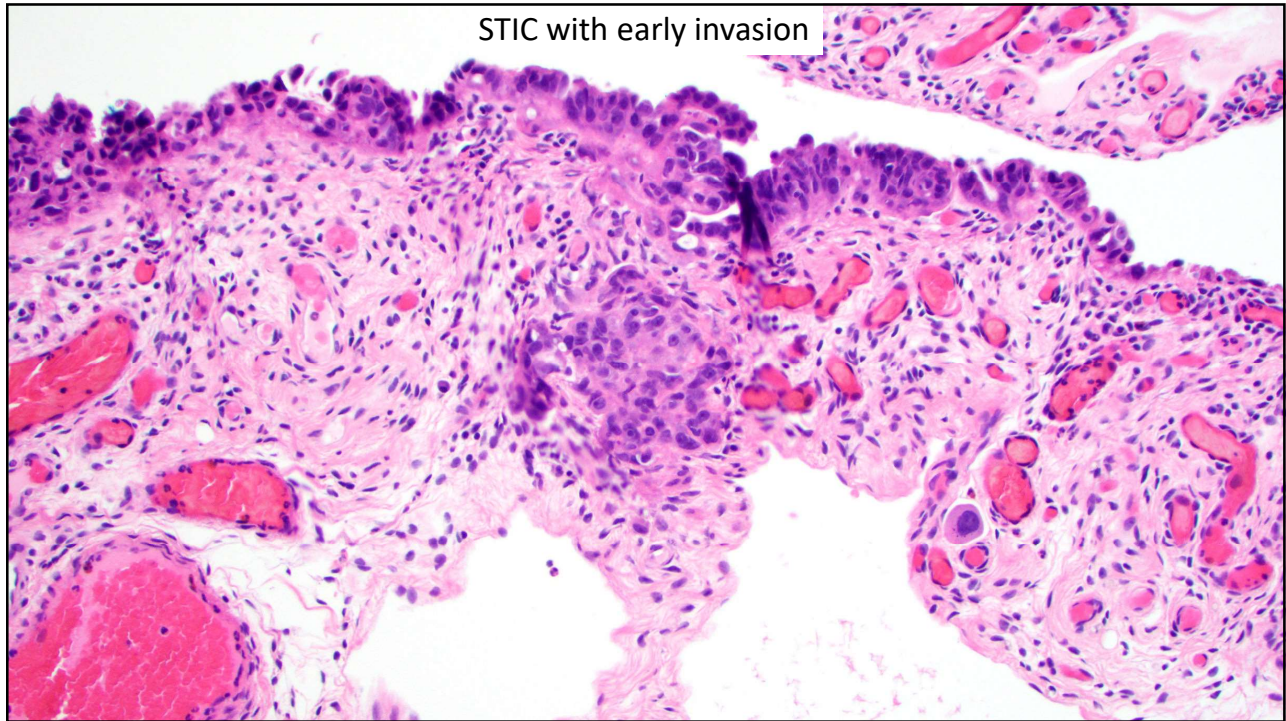
35



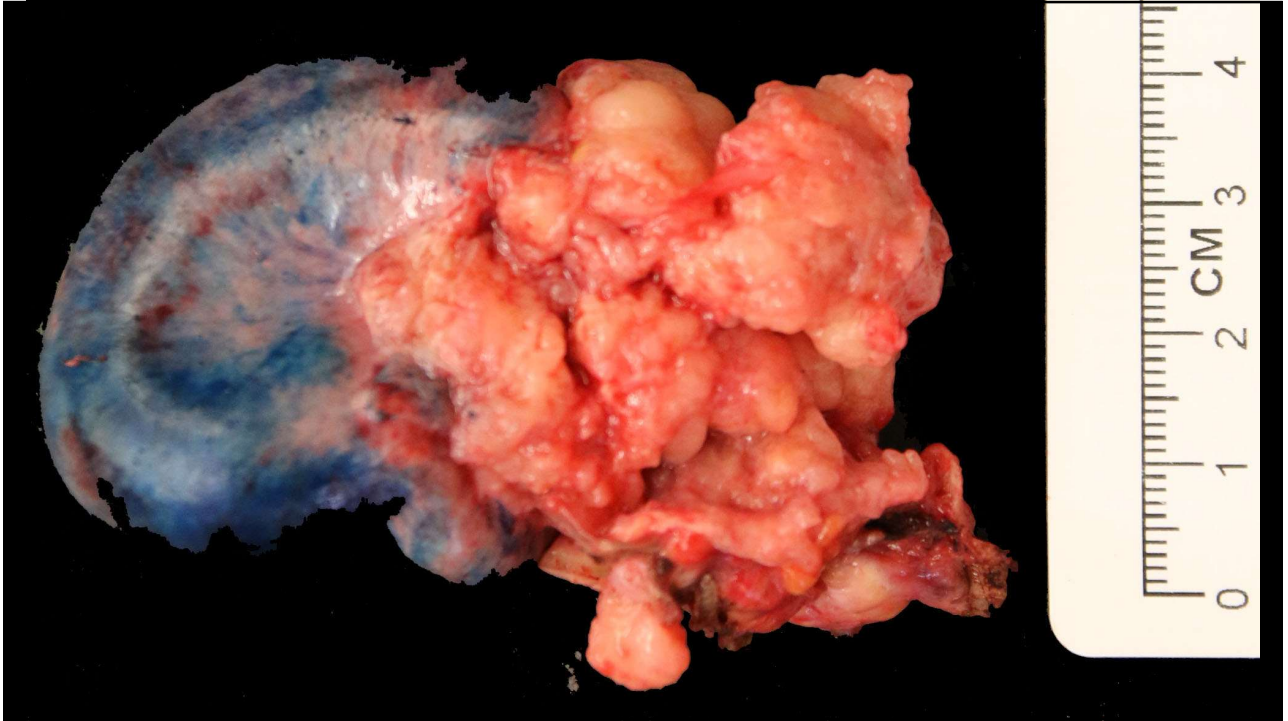
36



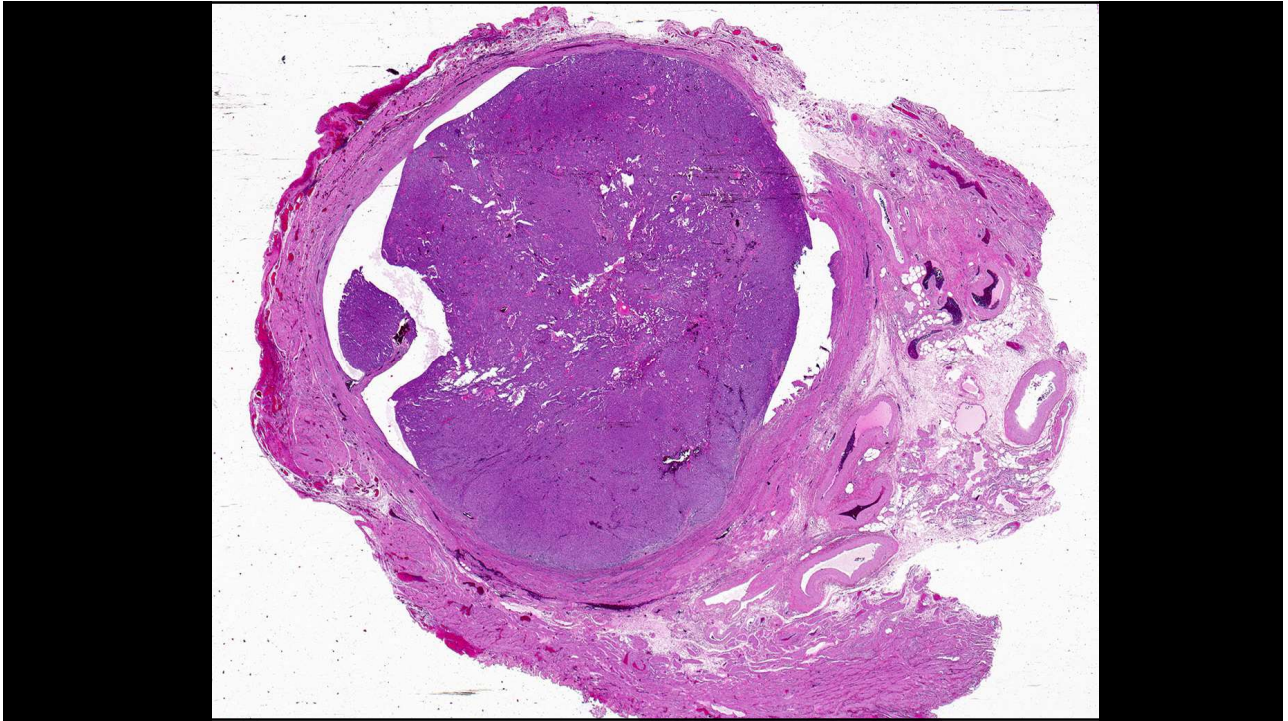
37



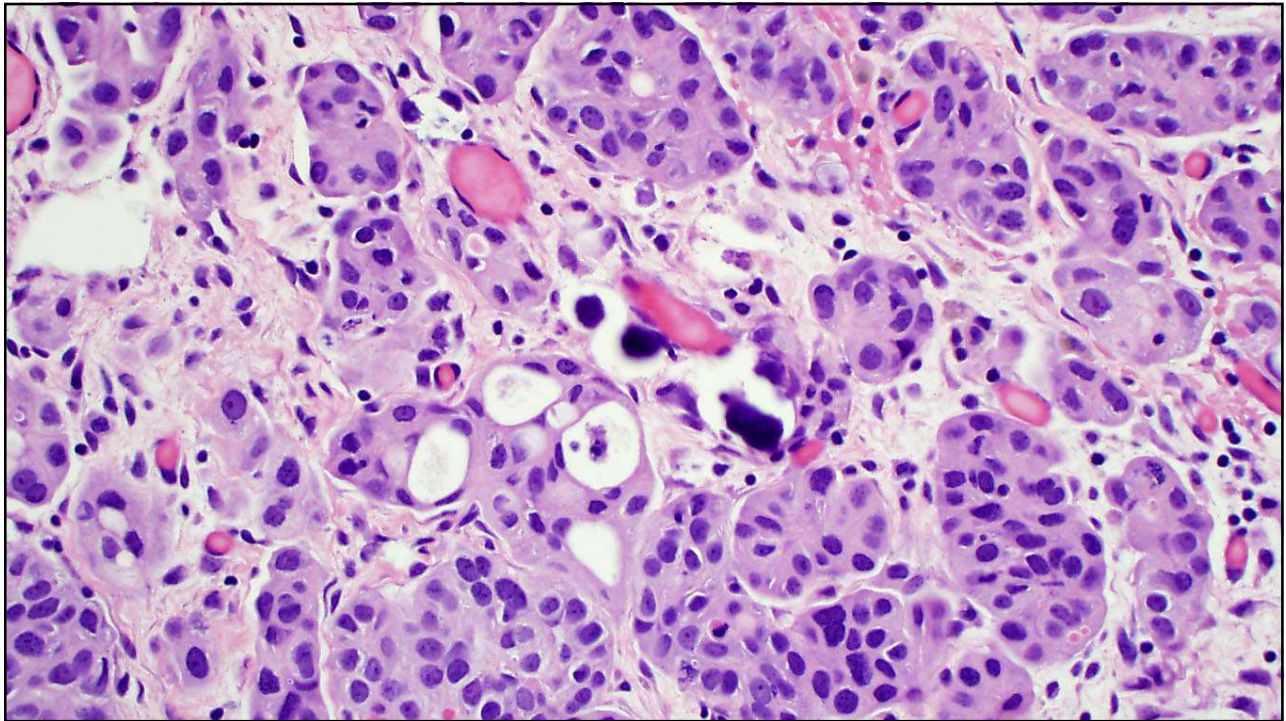
38



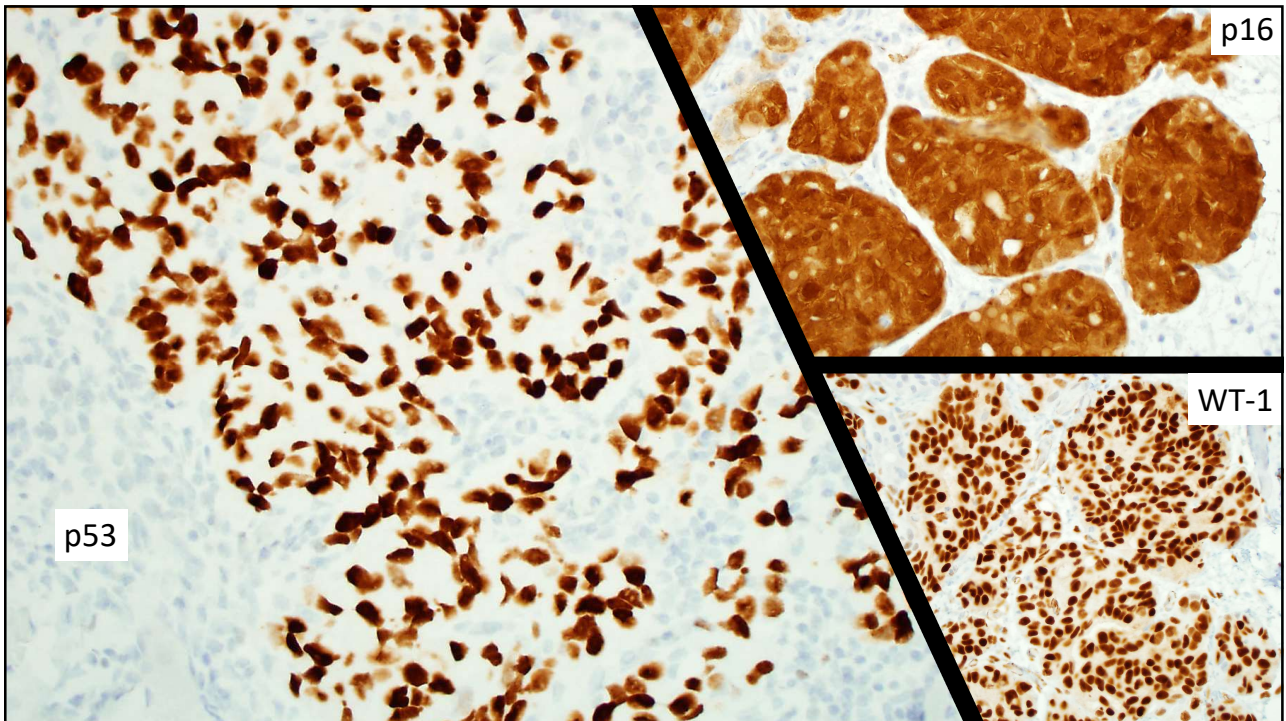
39



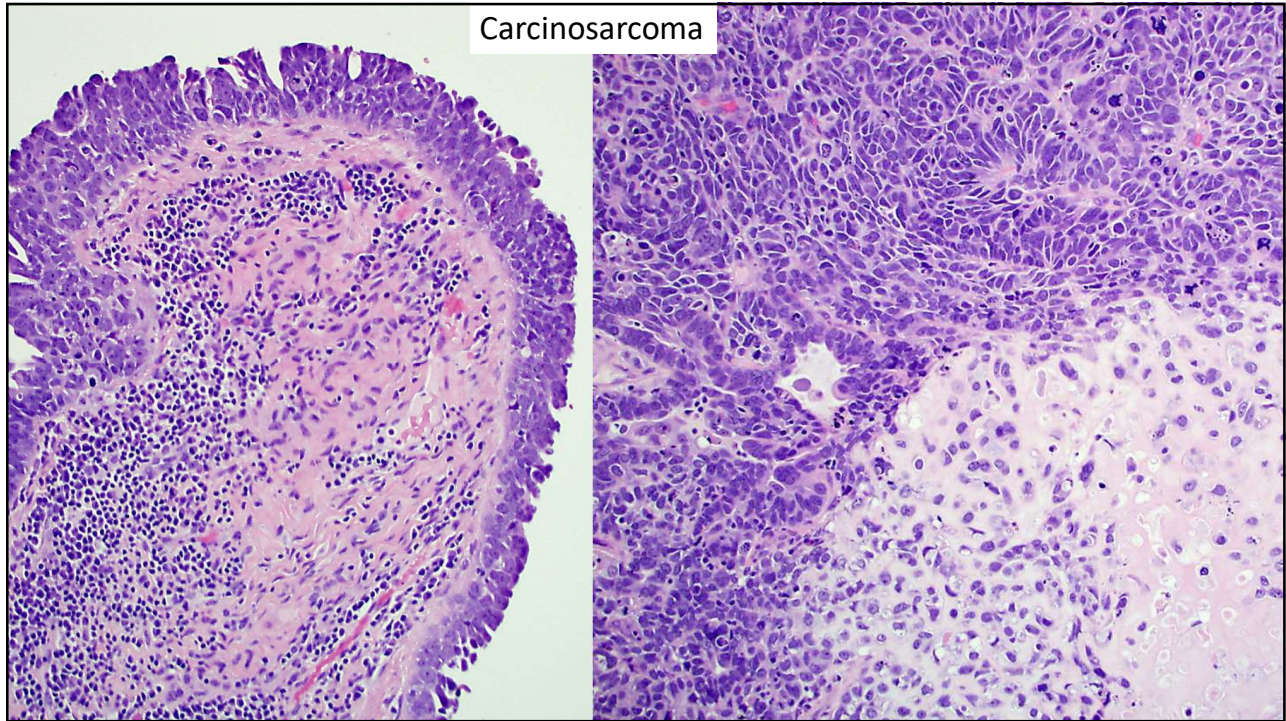
40



41



42



43

Outline

Mesothelial tumors

Serous neoplasia

Endometrioid neoplasia

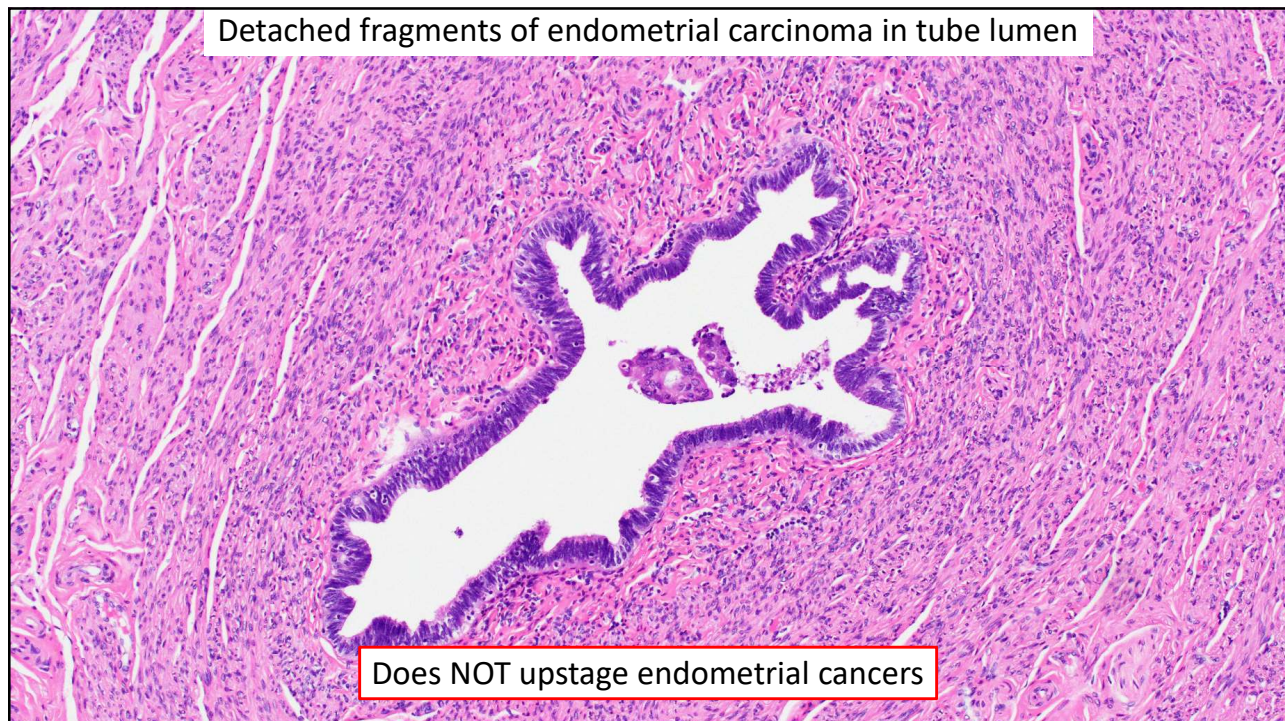
Tubal doodads: infectious, inflammatory, and other

44

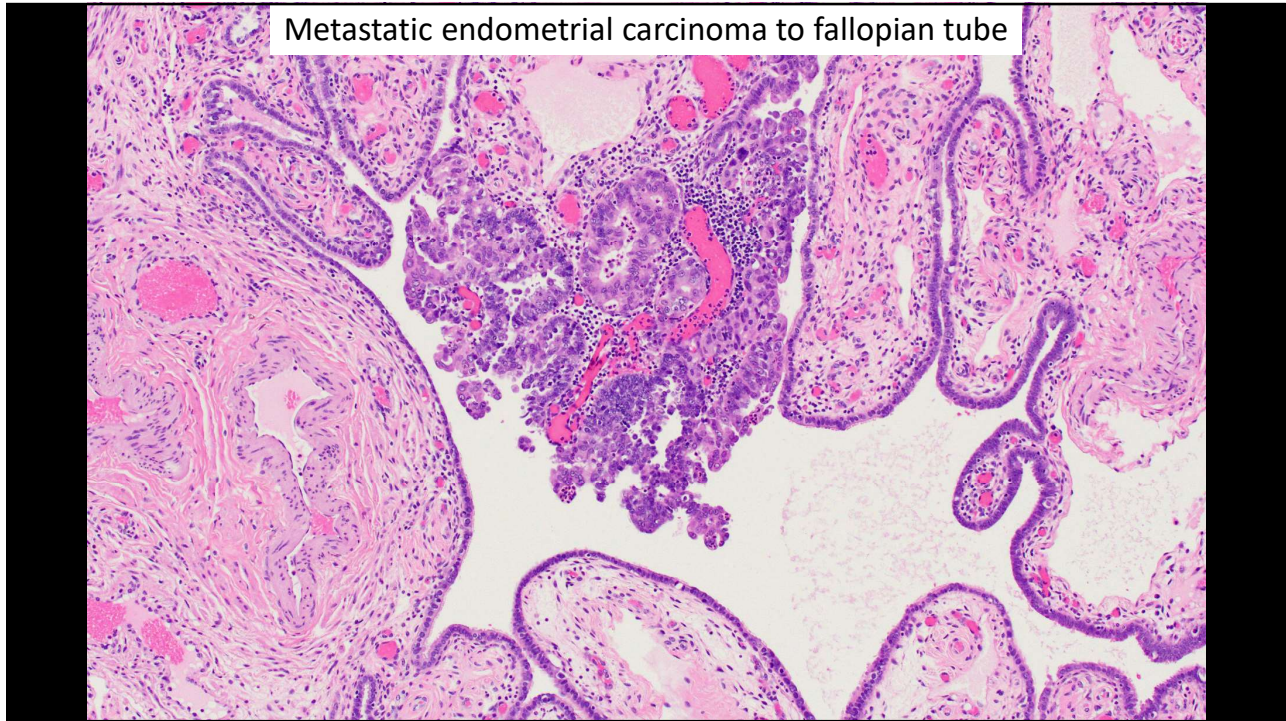
Endometrioid carcinomas of the tube

- Metastasis from endometrium or ovary
- Primary to tube
 - Arising in endometriosis
 - Arising from type II SCOUT

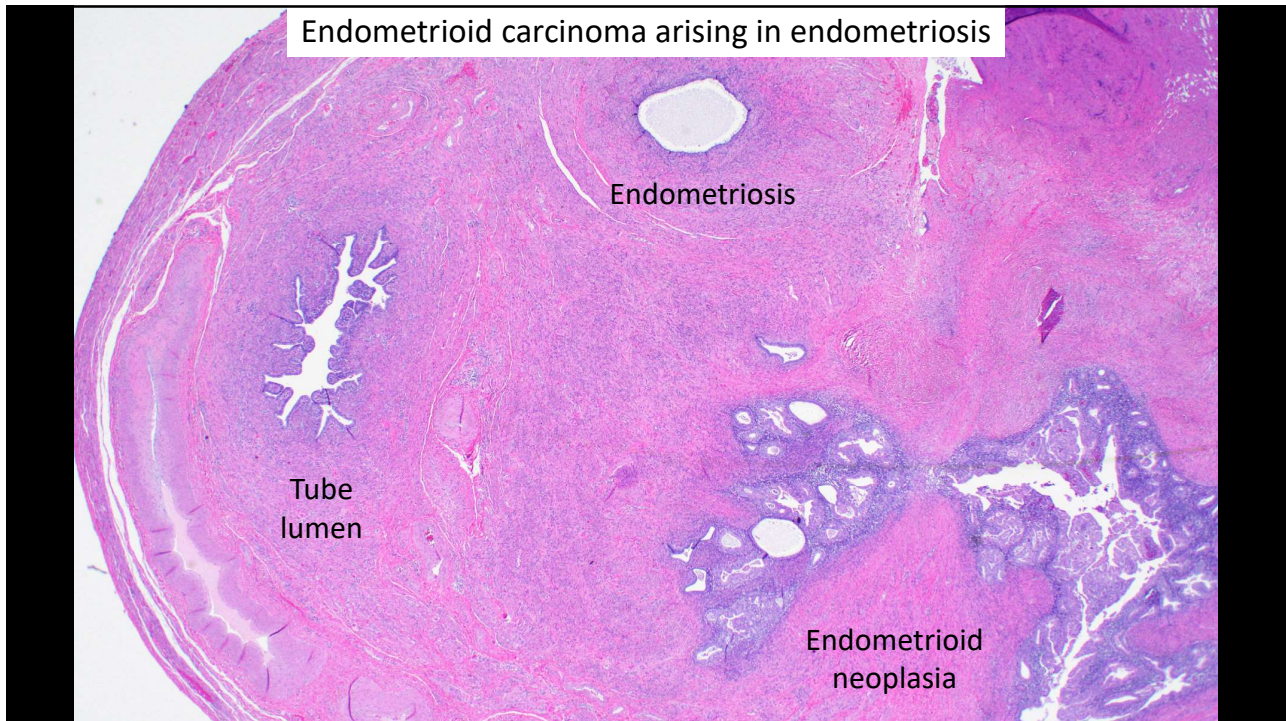
45



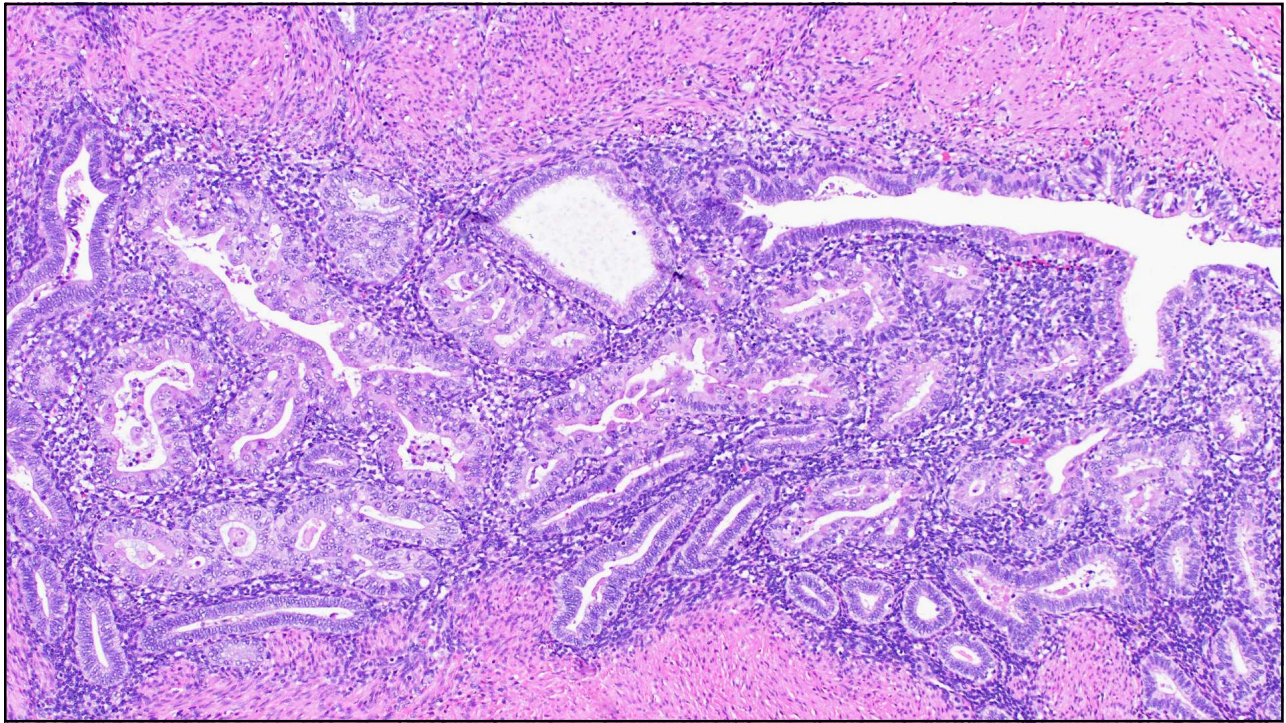
46



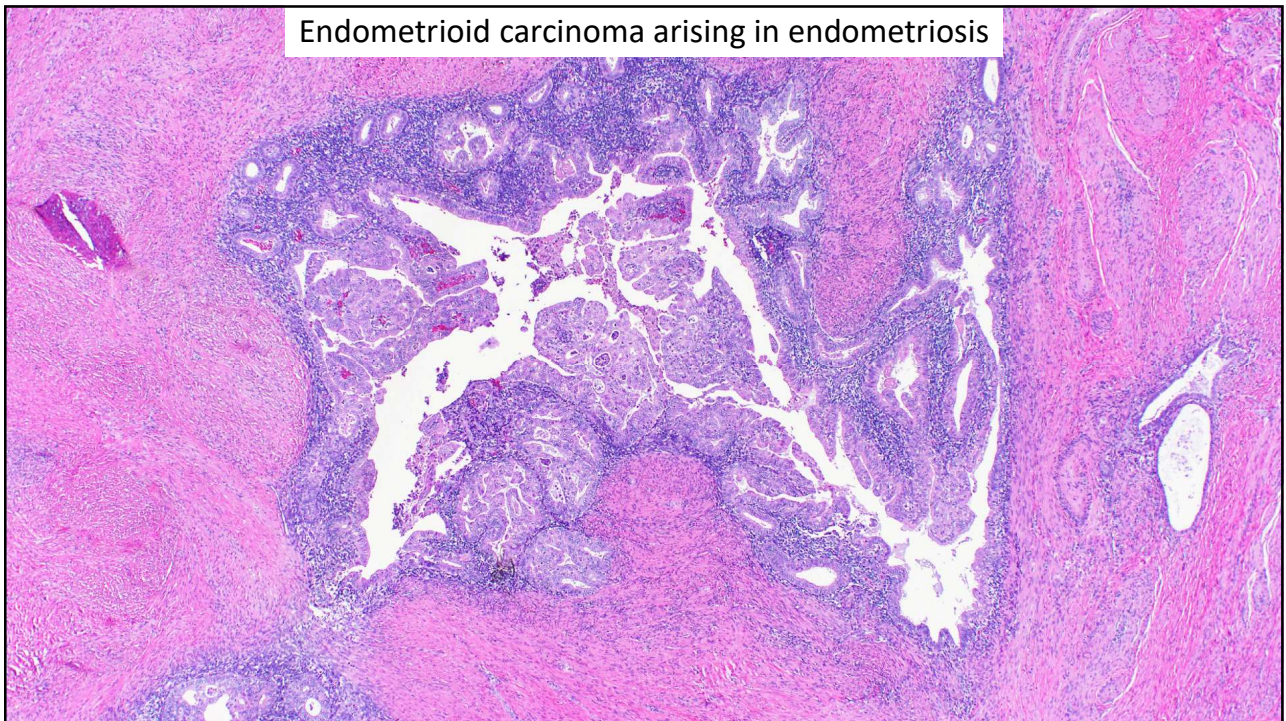
47



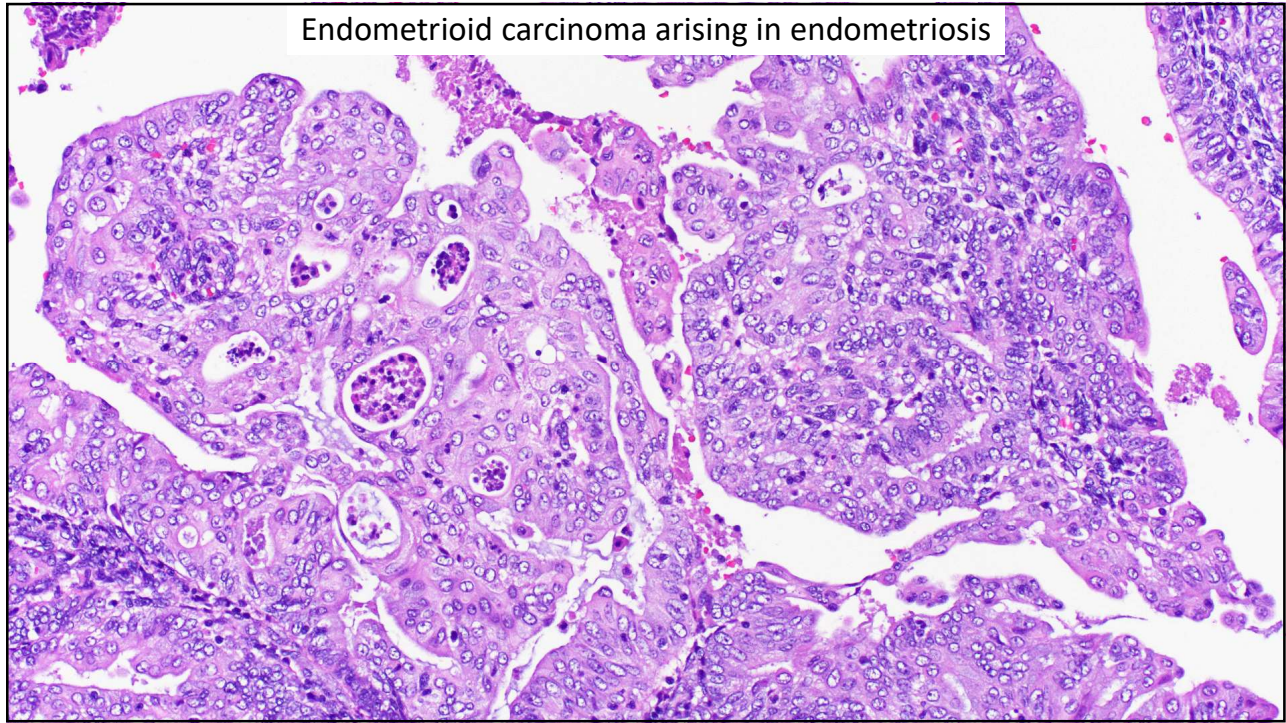
48



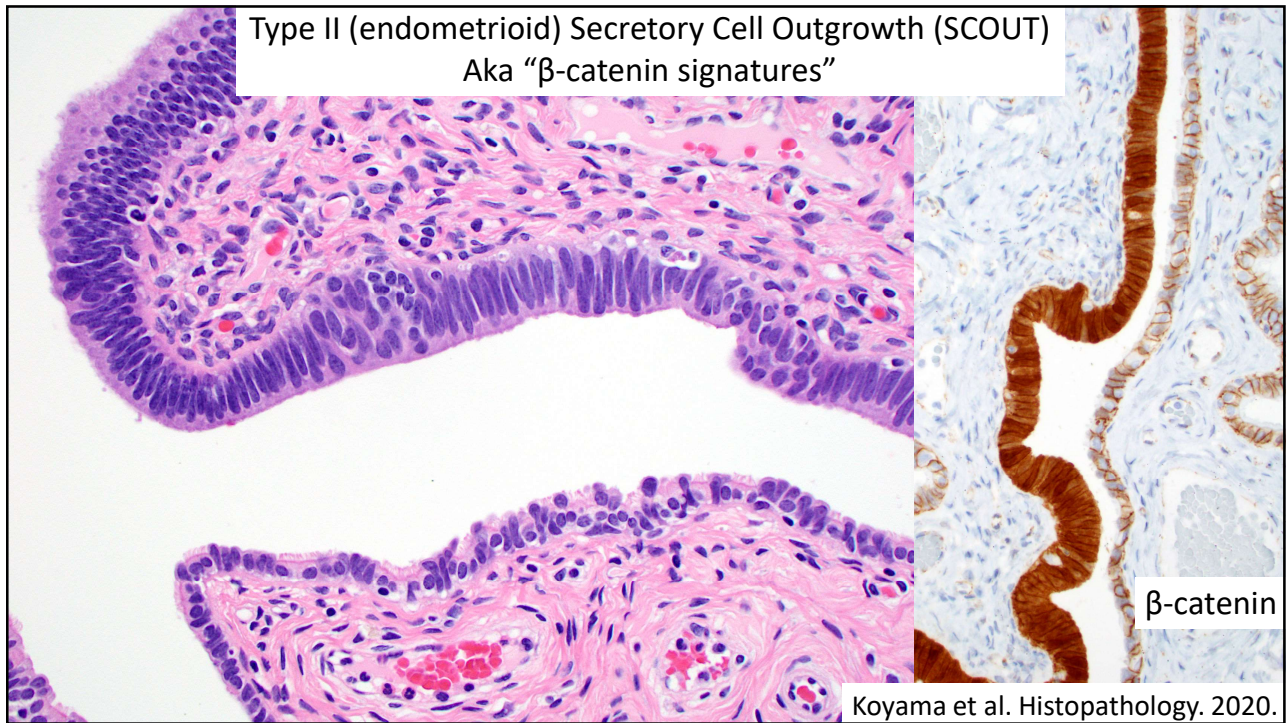
49



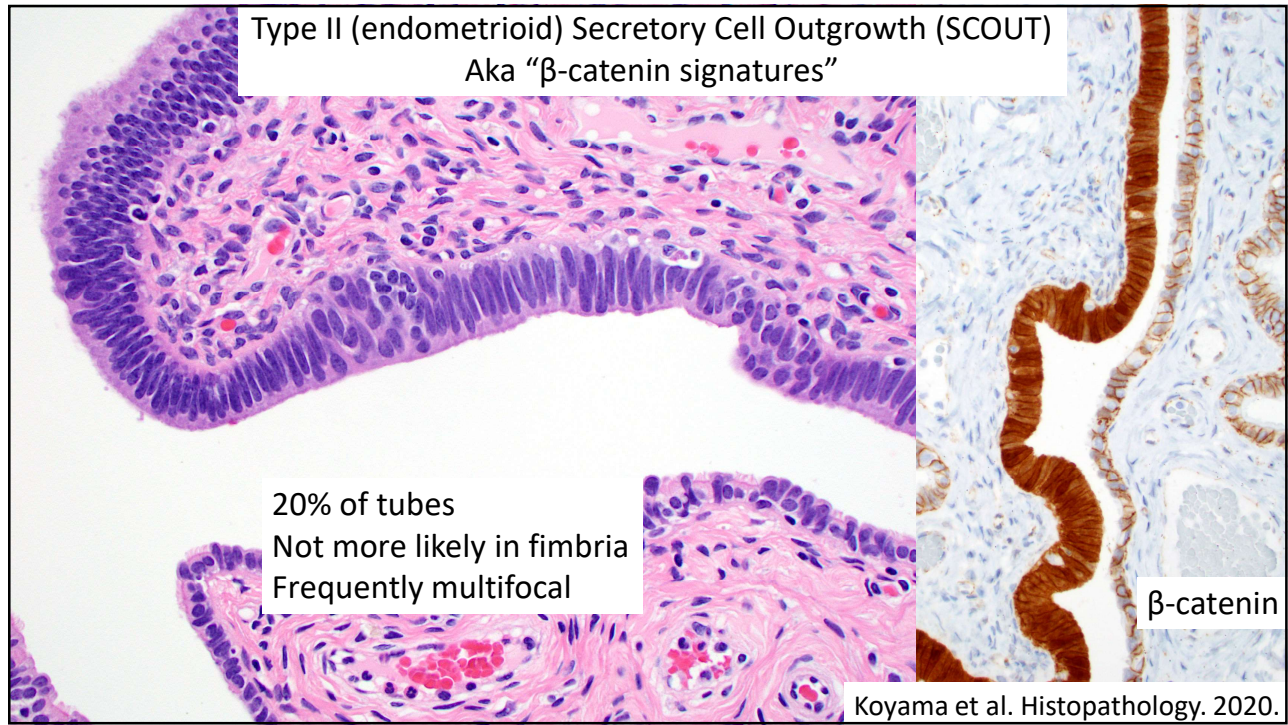
50



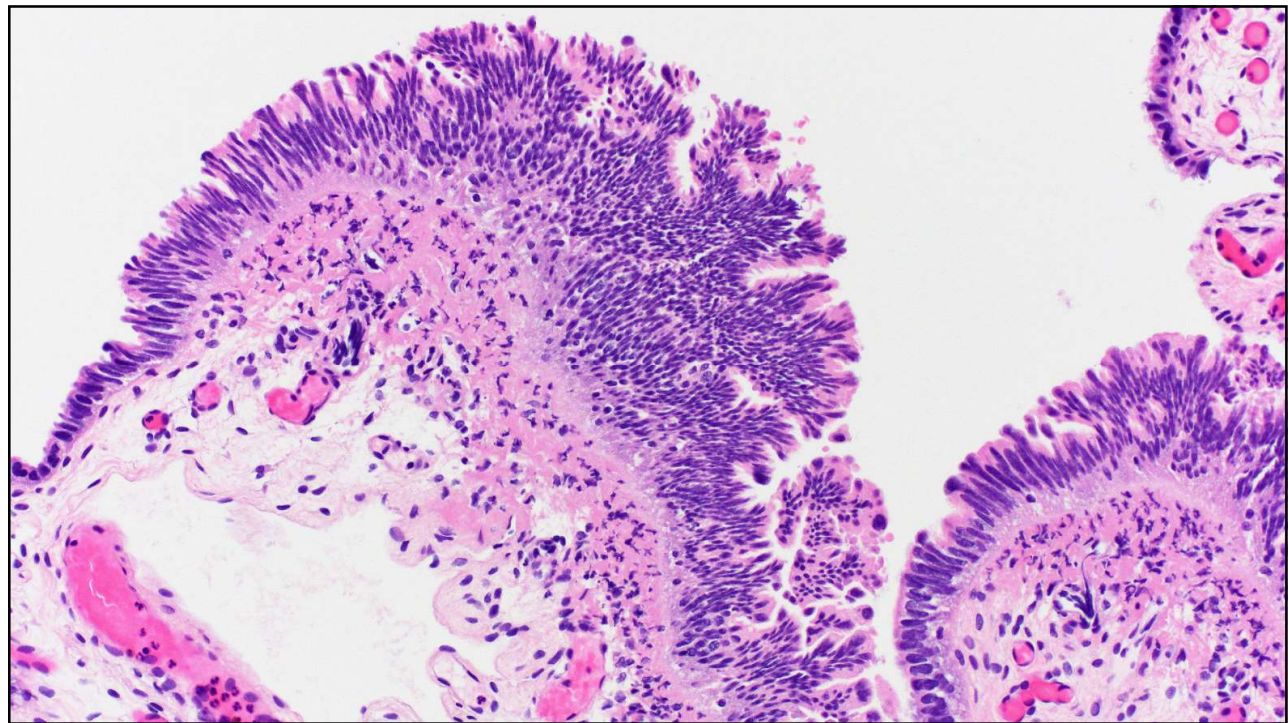
51



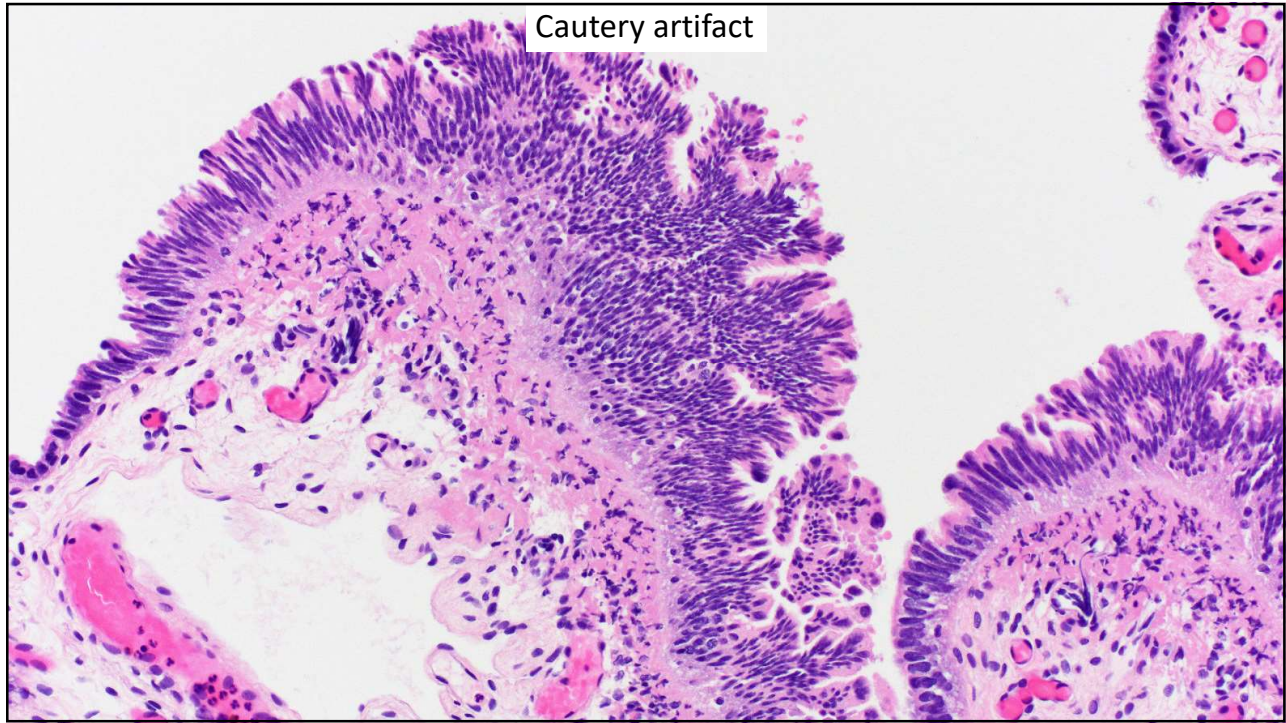
52



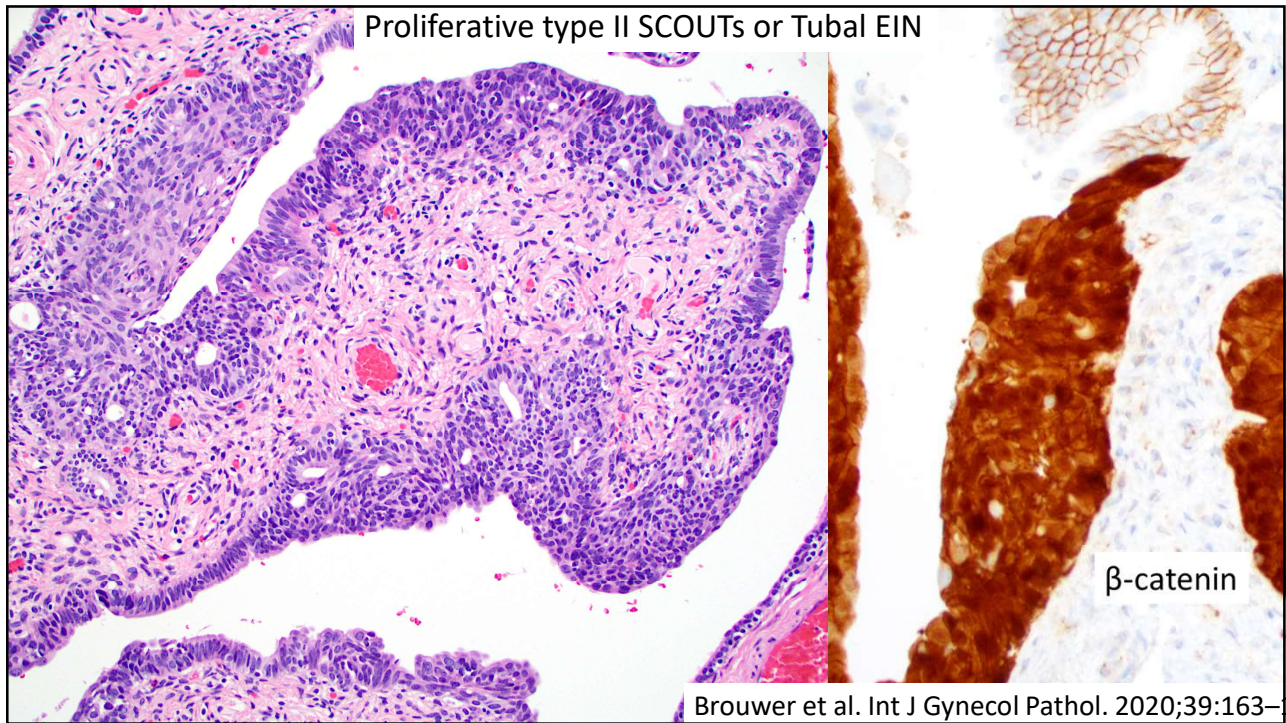
53



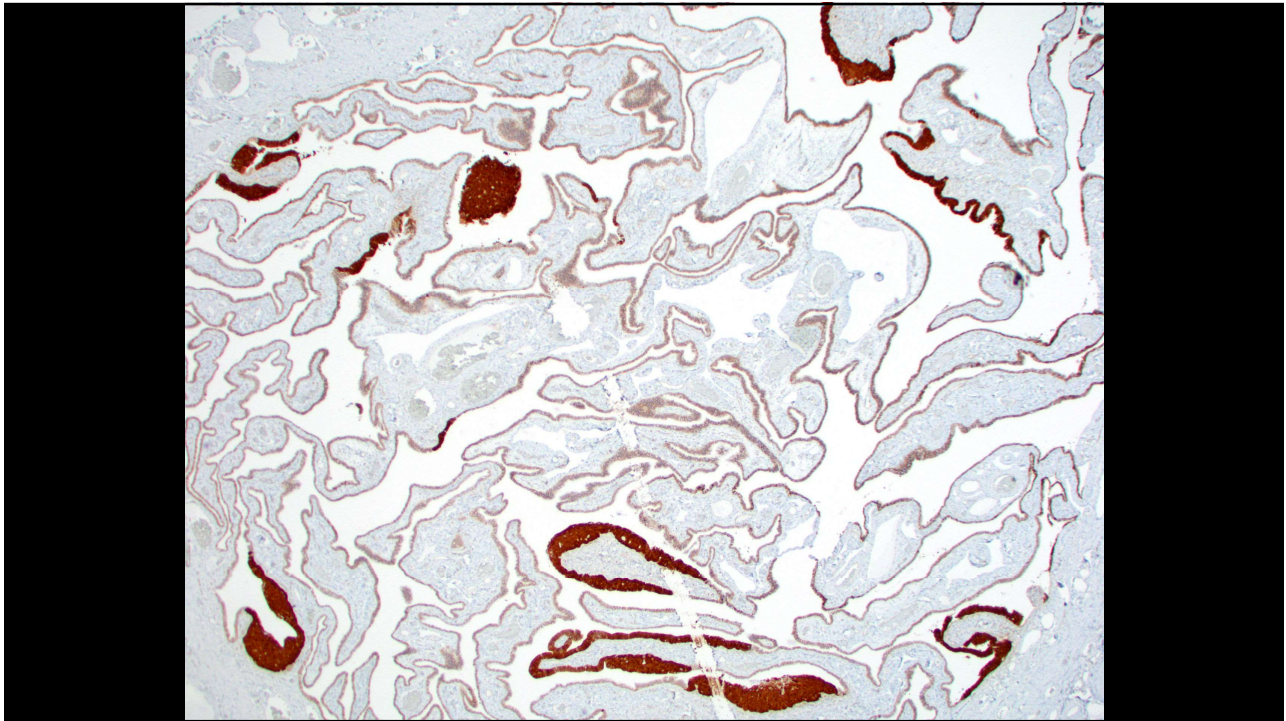
54



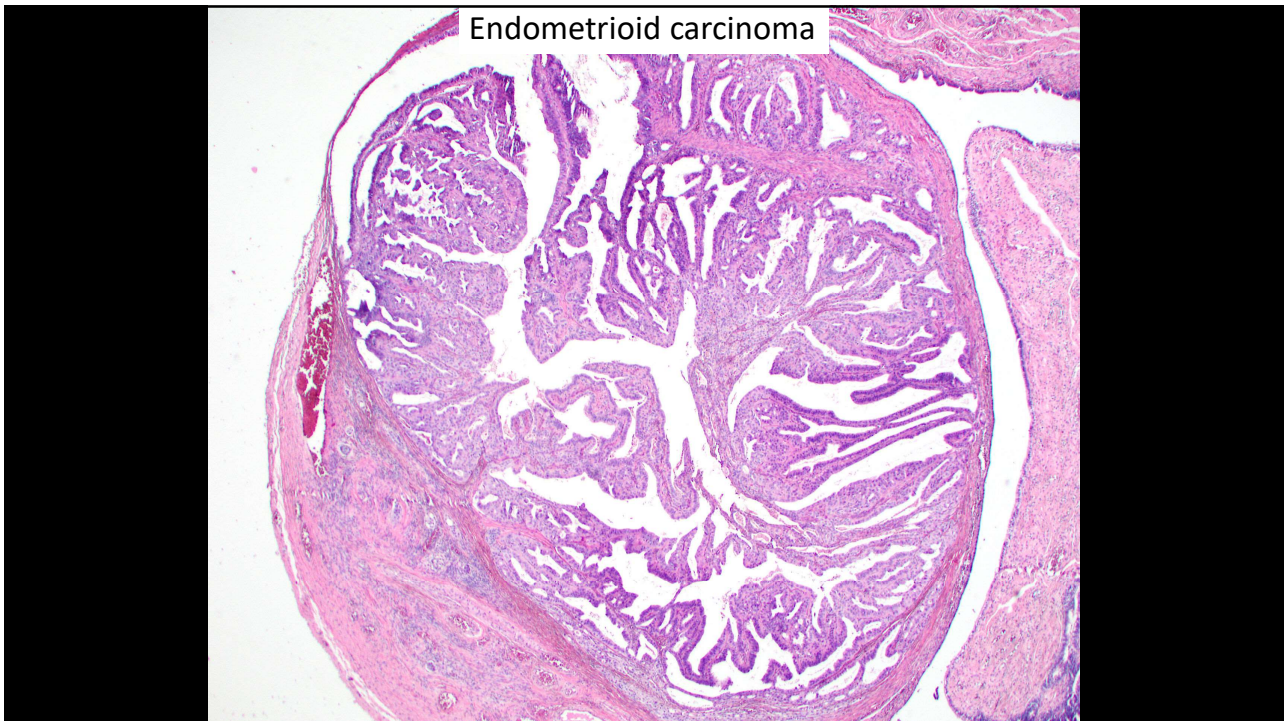
55



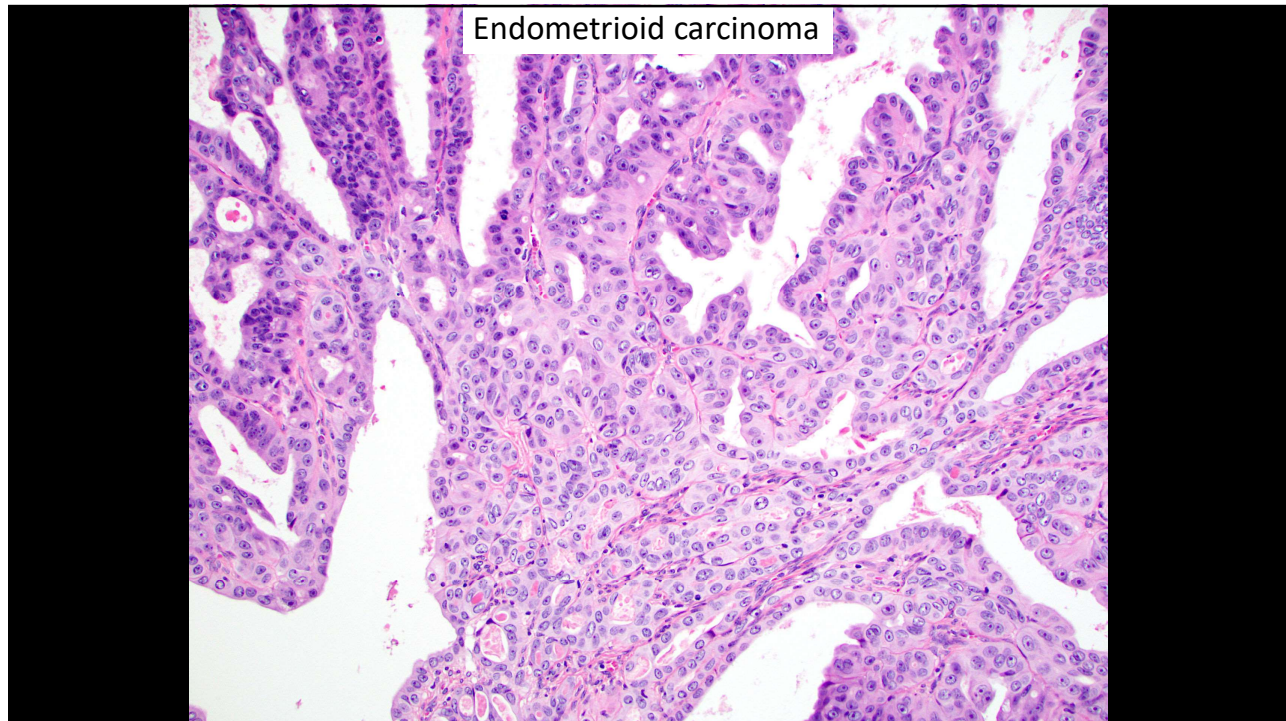
56



57



58



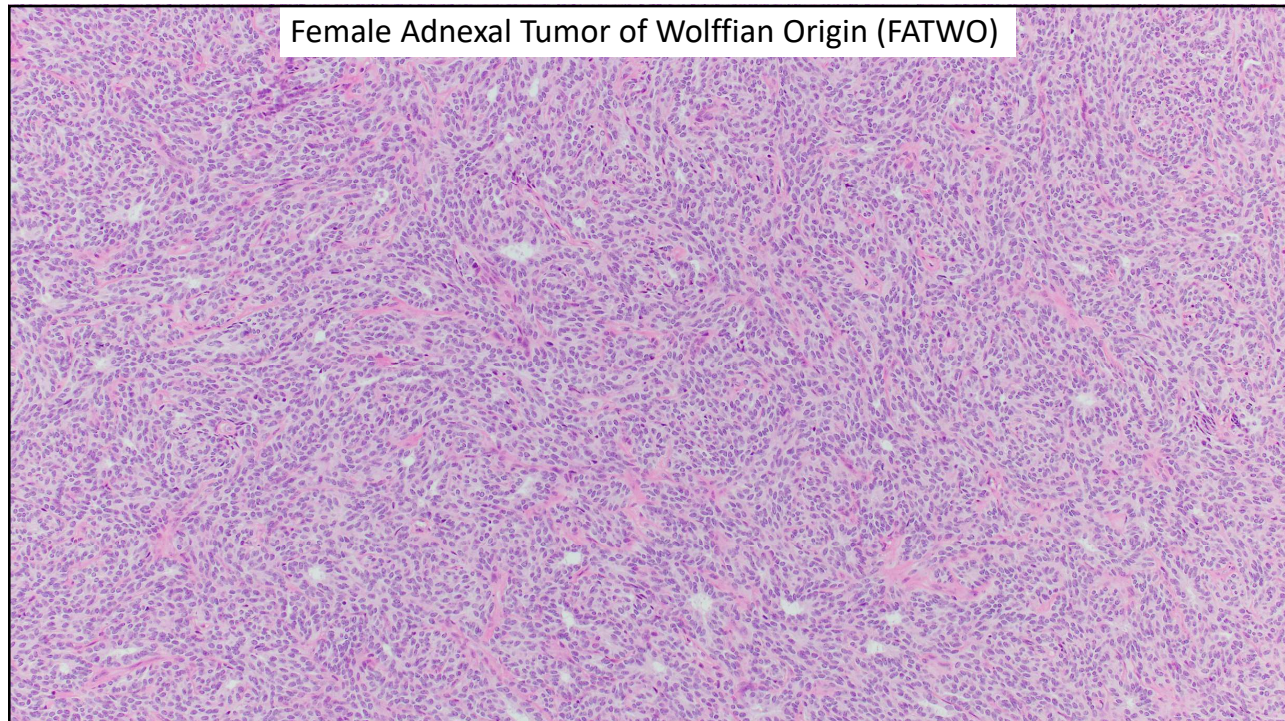
59

Female Adnexal Tumor of Wolffian Origin (FATWO)

- Broad ligament, paratubal
- Wide age range: 15-87 years
- Solid, tubular, sieve-like growth
- Oval/cuboidal cells with low-grade cytology
- Rare mitotic figures
- IHC
 - Positive: calretinin, CD10, variable CK7, EMA, inhibin
 - Negative: PAX8, GATA3
- No recurrent, defining, molecular features (?*KMT2D*, *STK11*)
- Low malignant potential, may recur

Mirkovic et al, Int J Gyn Path. 2019;38(6):543-551.
Bennett et al, Mod Path. 2020;33:734-747.

60



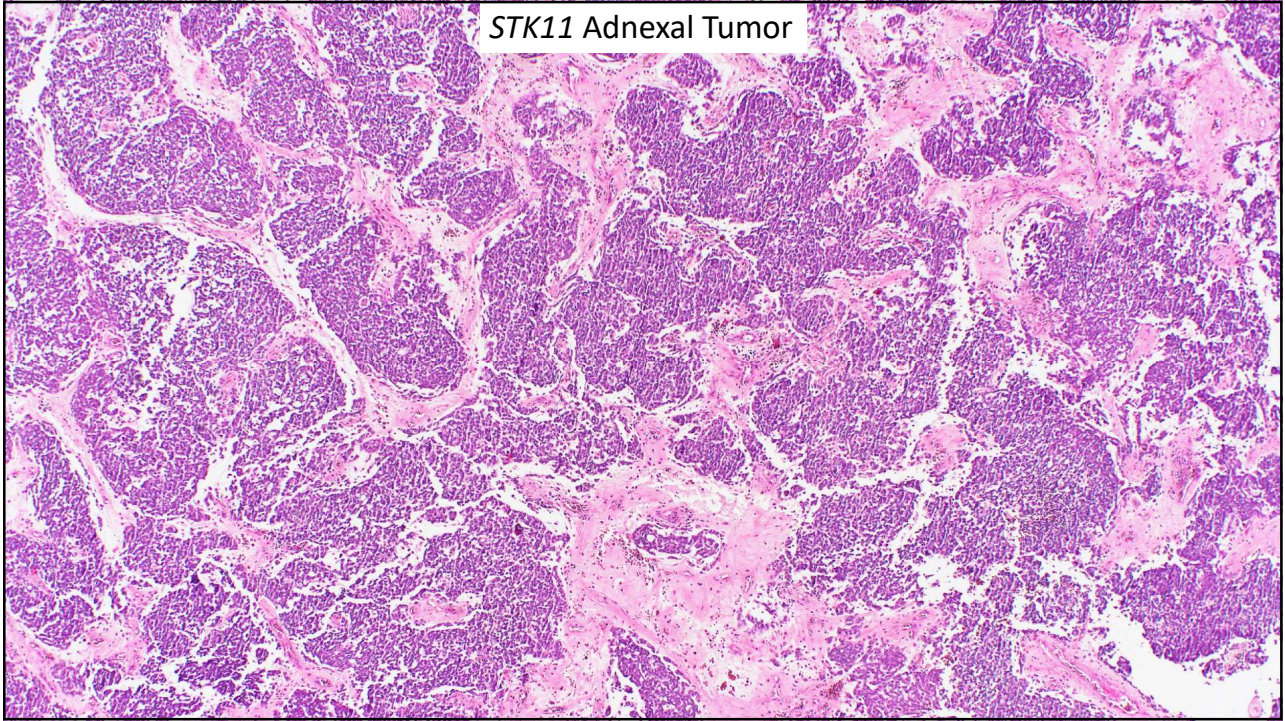
61

STK11 Adnexal Tumor

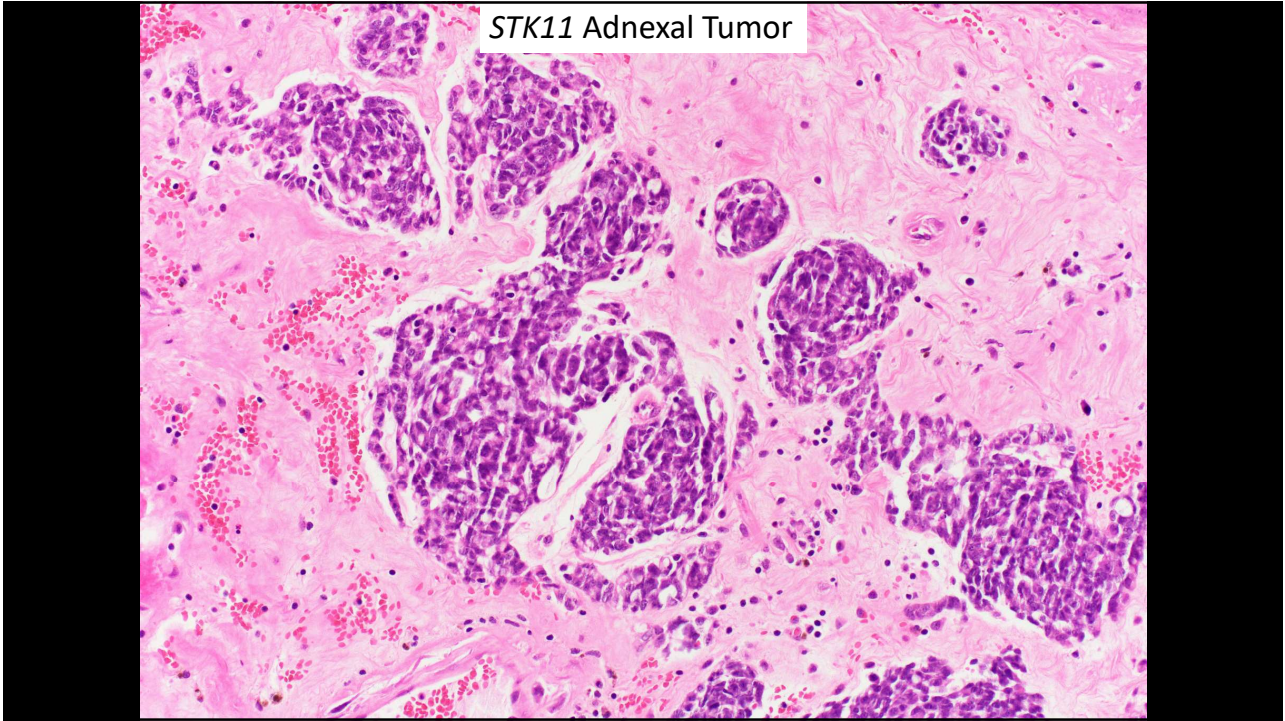
- *STK11* mutations
- Paratubal/adnexal
- Median age: 39 yr (range: 17-66)
- Median size: 11 cm (range 4.5-25.5)
- Association with Peutz-Jeghers in ~50%
- Highly variable morphology: cords, trabeculae, cystic, cribriform, microacinar, nested
- Positive: Cam5.2, AE1/AE3, inhibin, calretinin, WT-1, ER/PR
- PAX8 negative to patchy
- Recurrences and metastases common

Bennett et al, AJSP. 2021.

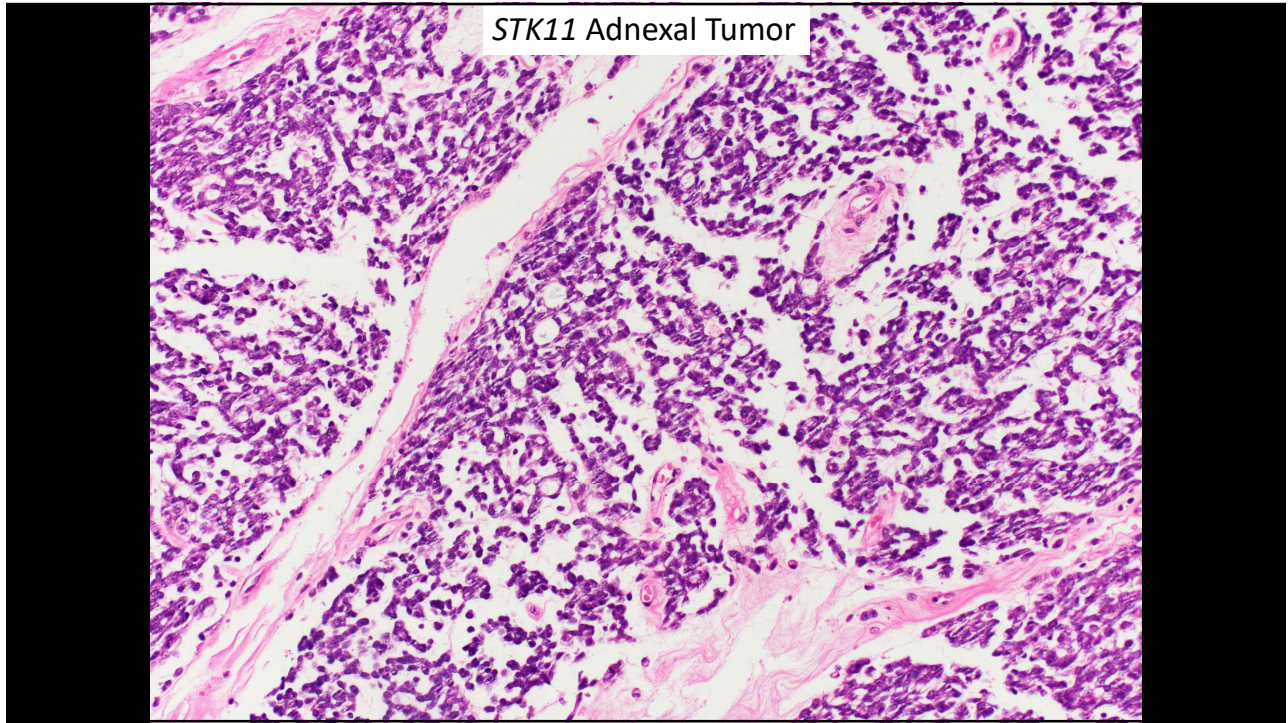
62



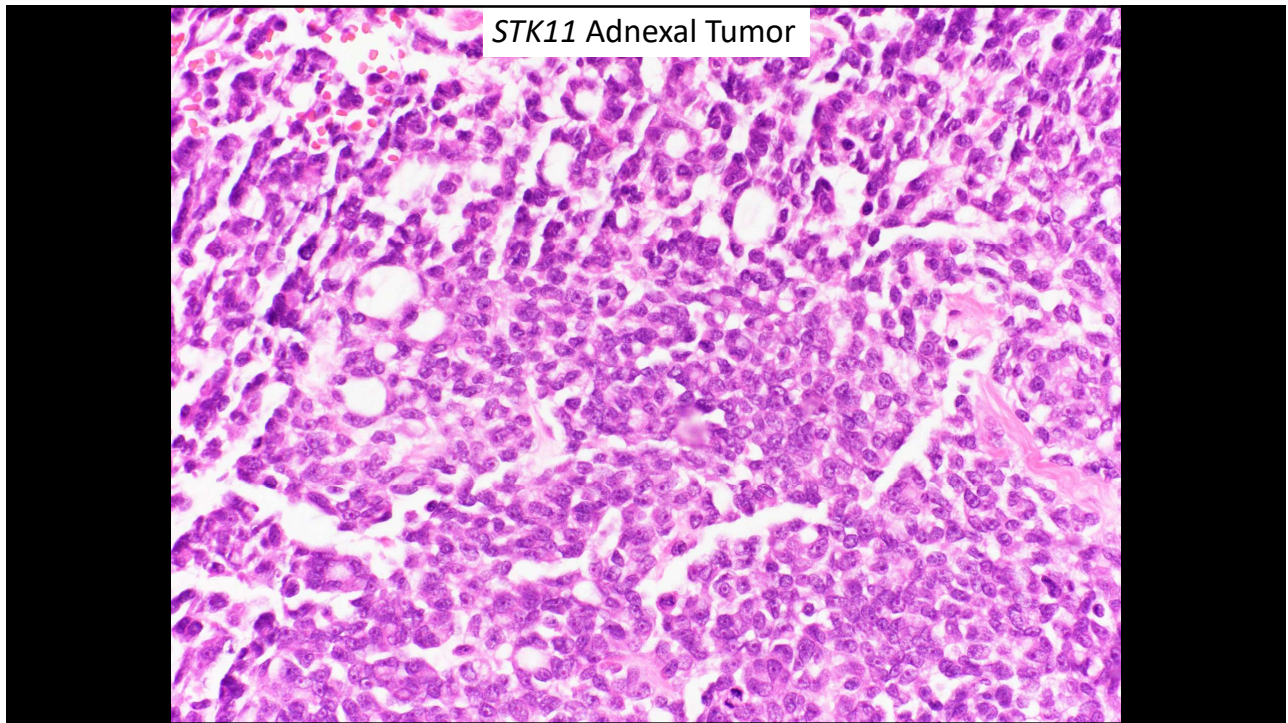
63



64

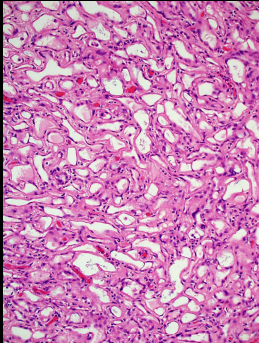


65

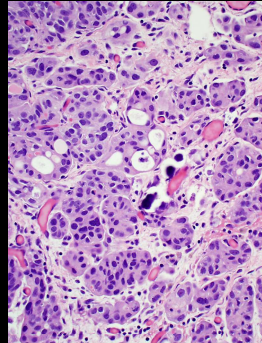


66

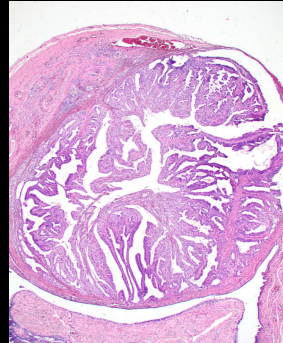
Outline



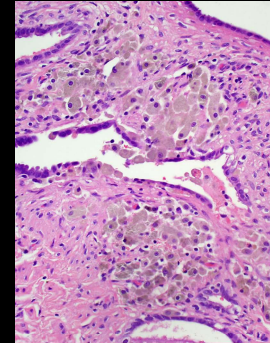
Mesothelial
tumors



Serous
neoplasia



Endometrioid
neoplasia



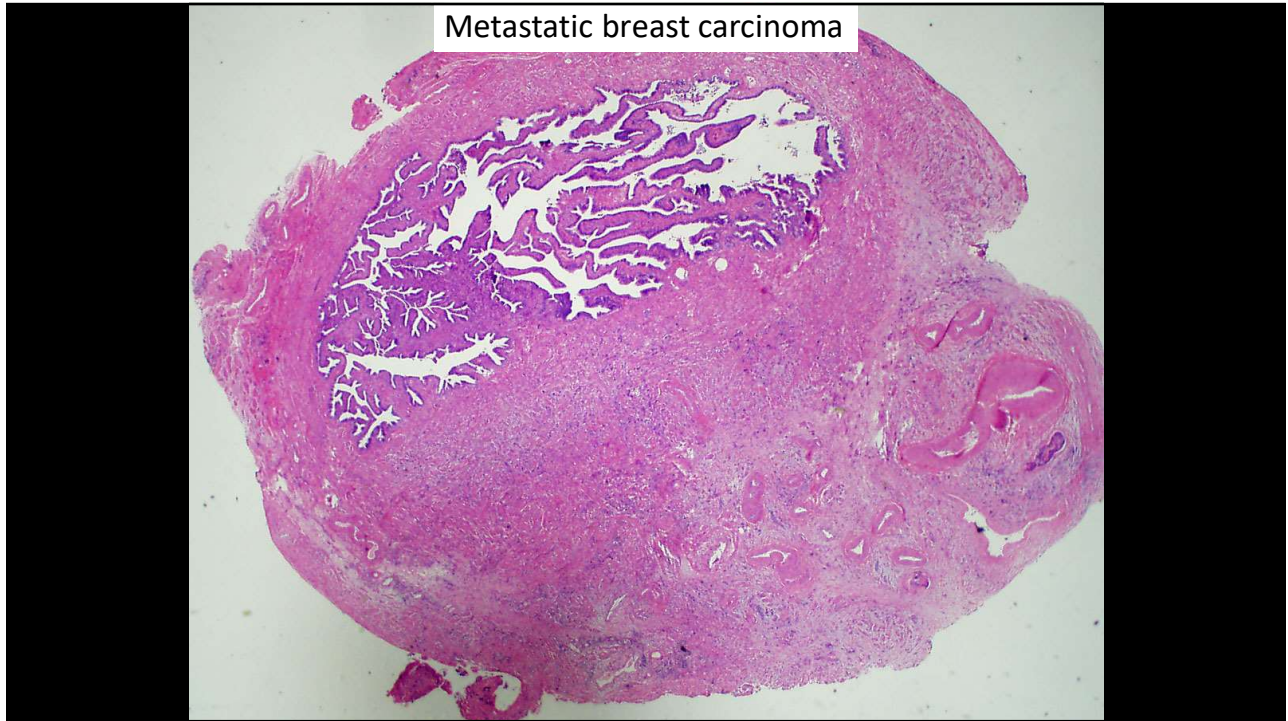
Tubal doodads:
infectious,
inflammatory,
and other

67

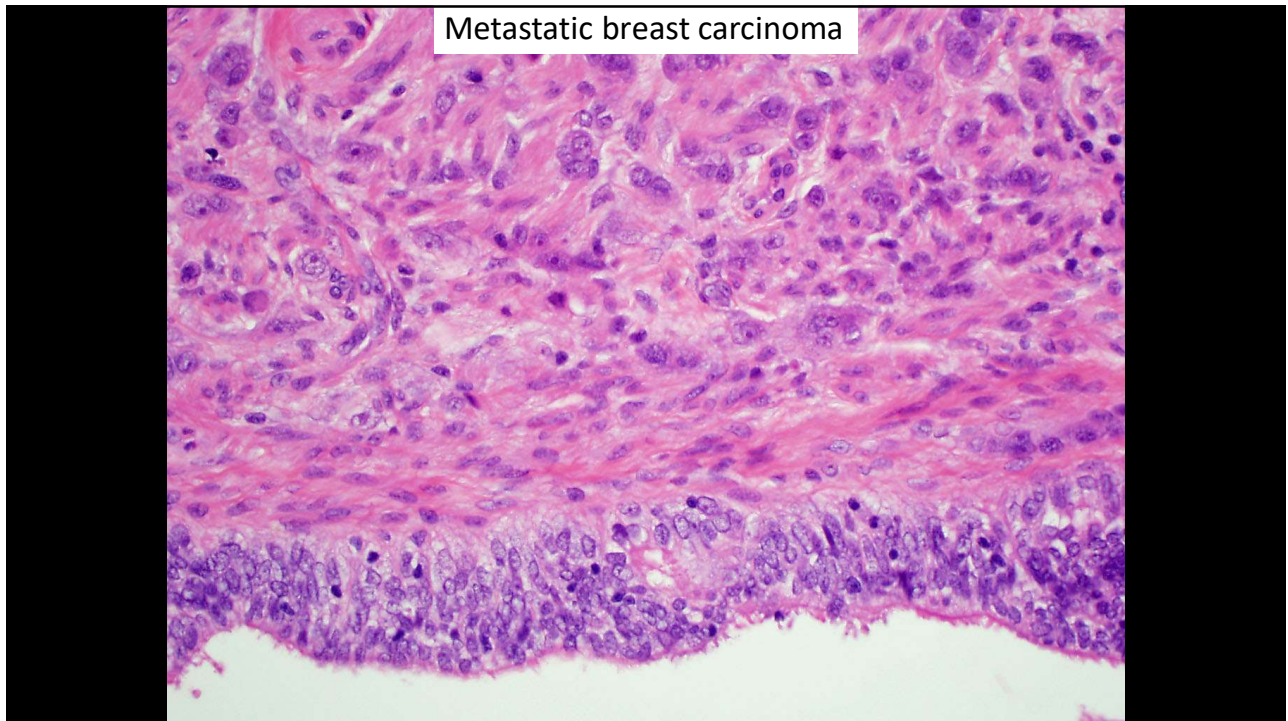
Metastases to the tube

- GYN:
 - endometrial, ovarian
- Non-GYN:
 - Carcinomas of appendix, colon, stomach, biliary system, breast
 - Lymphoma
 - GI neuroendocrine tumors
 - Mesothelioma
- Location: serosal, muscular wall, mucosal, intravascular
- Mucosal mets may mimic STIC!

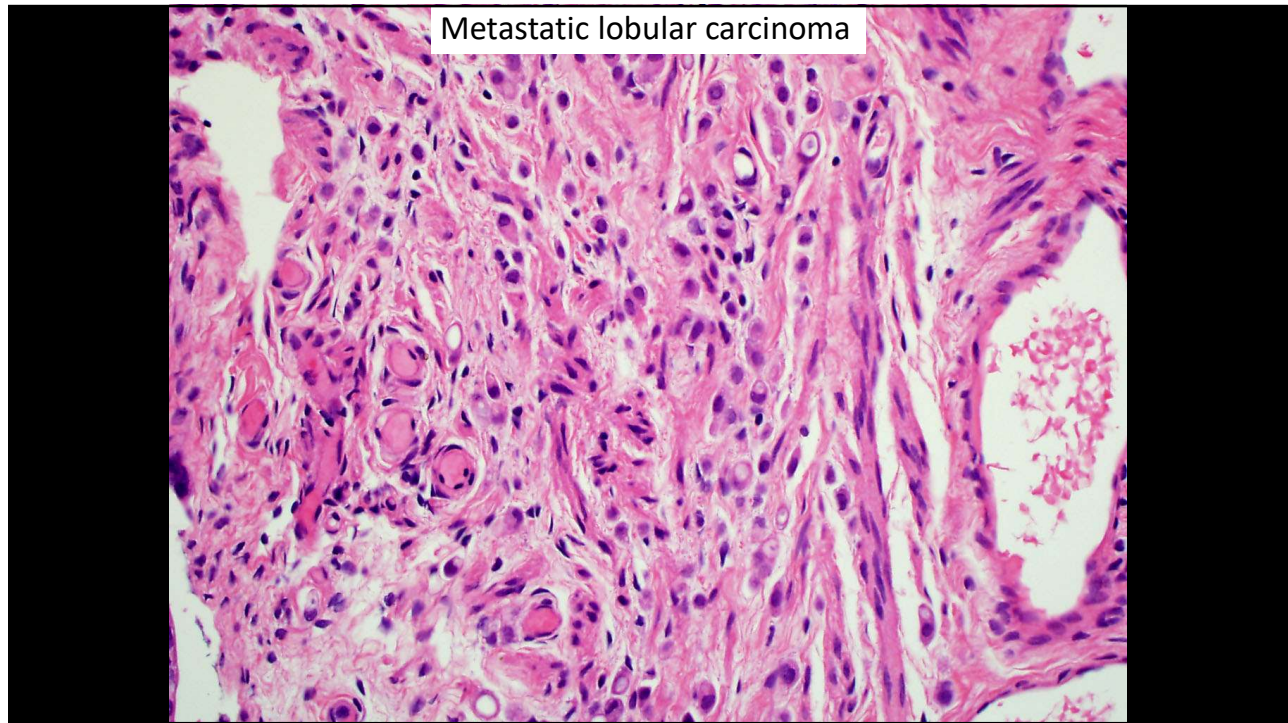
68



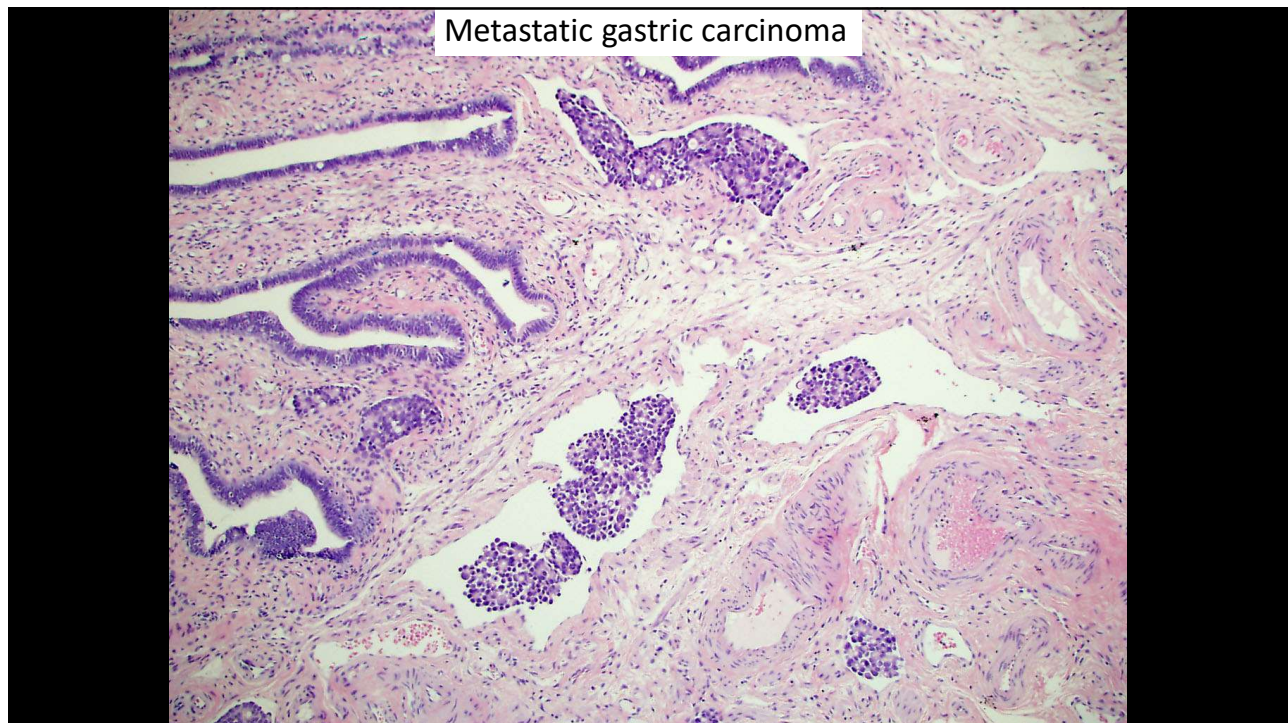
69



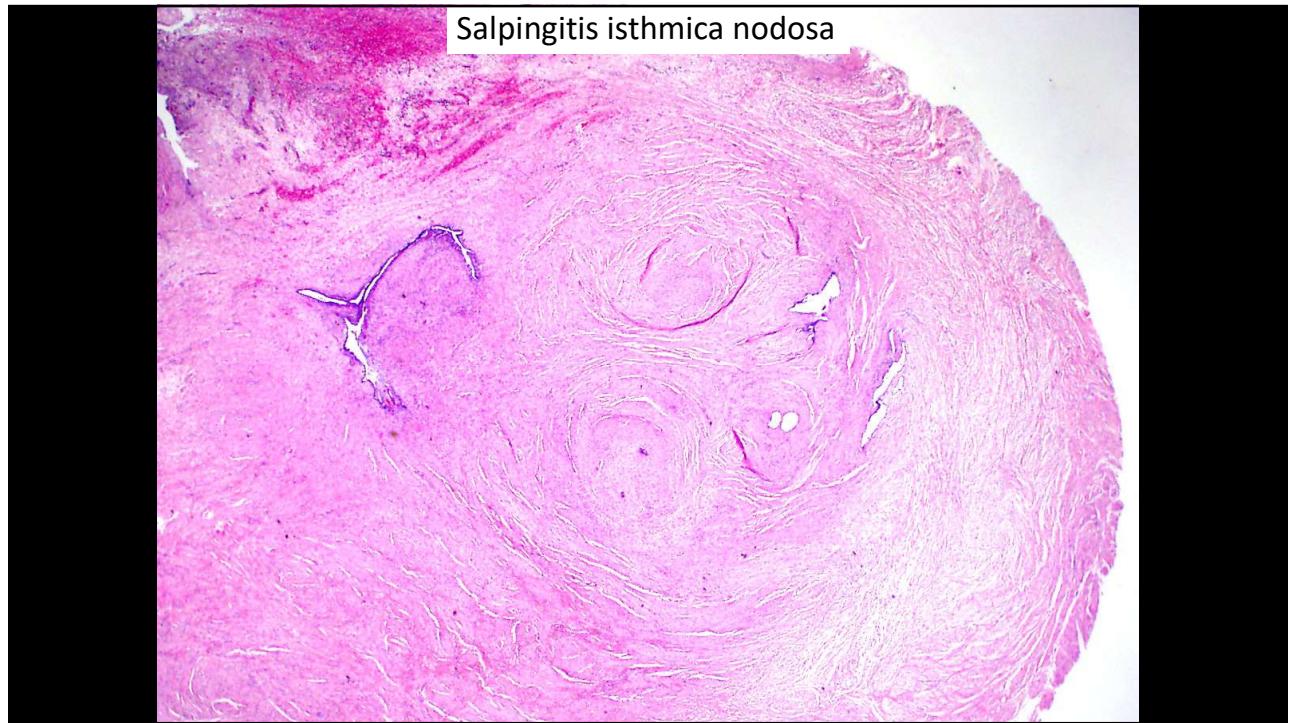
70



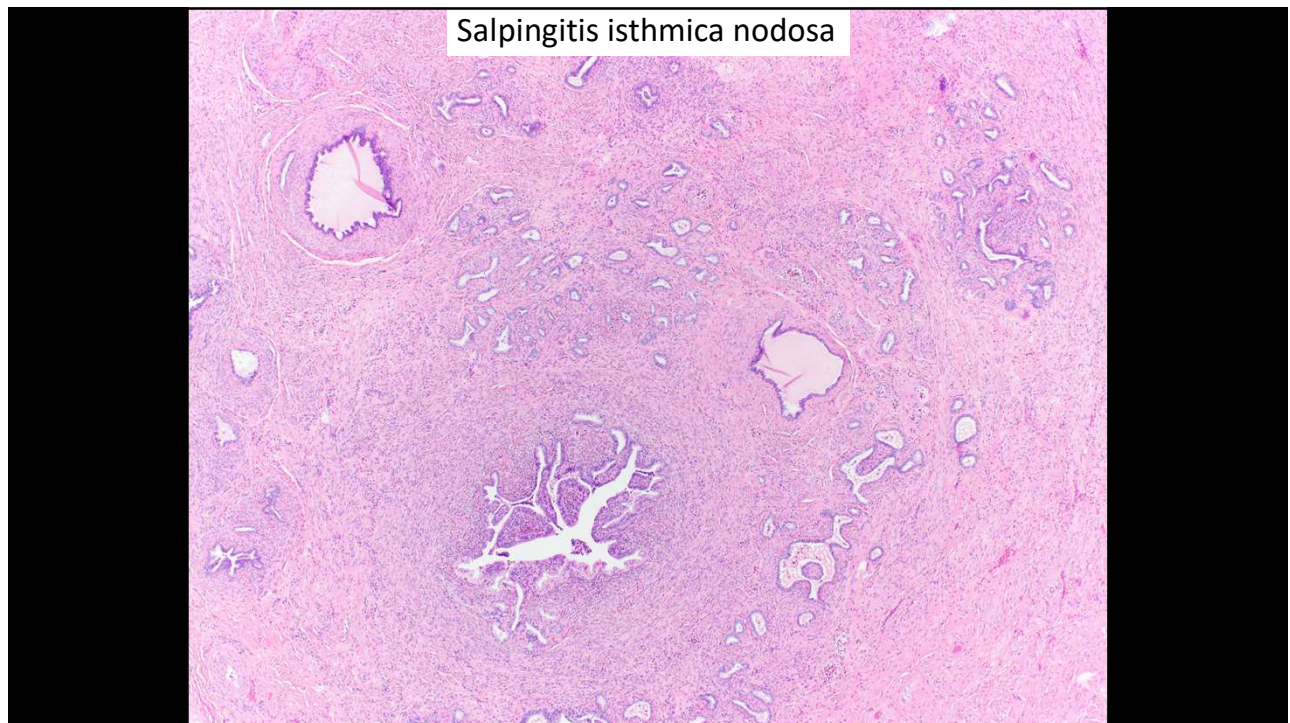
71



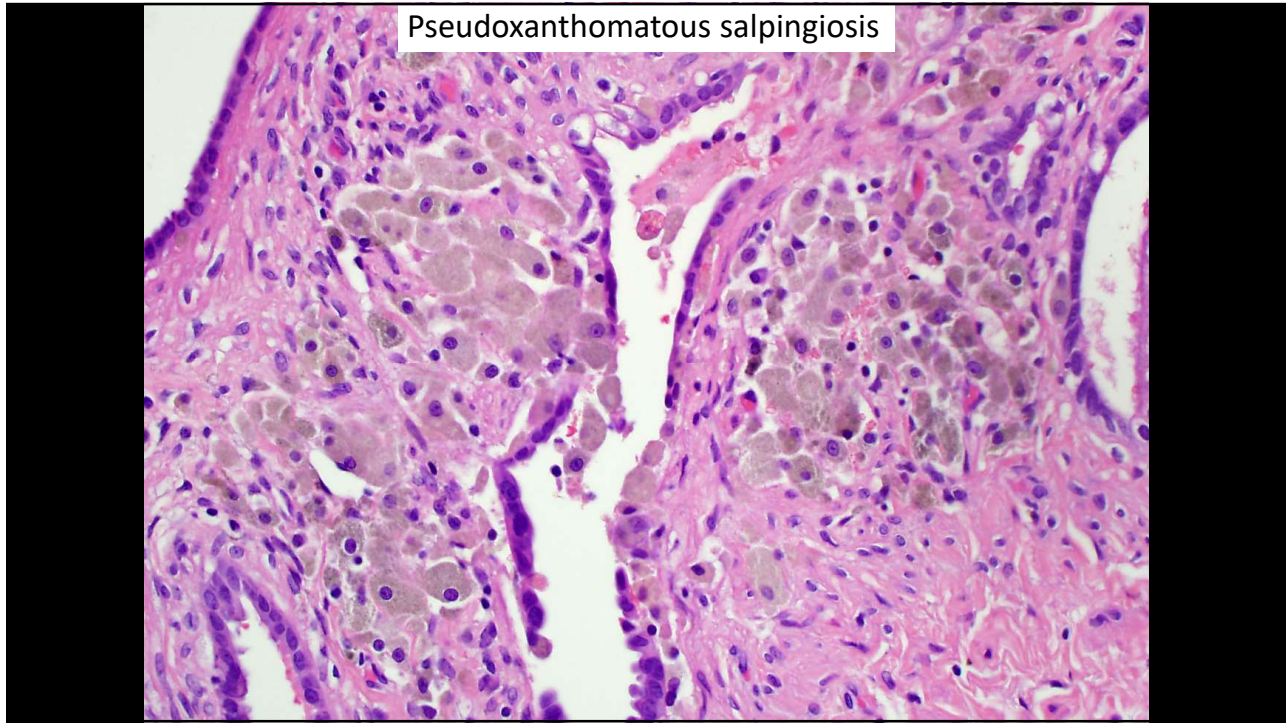
72



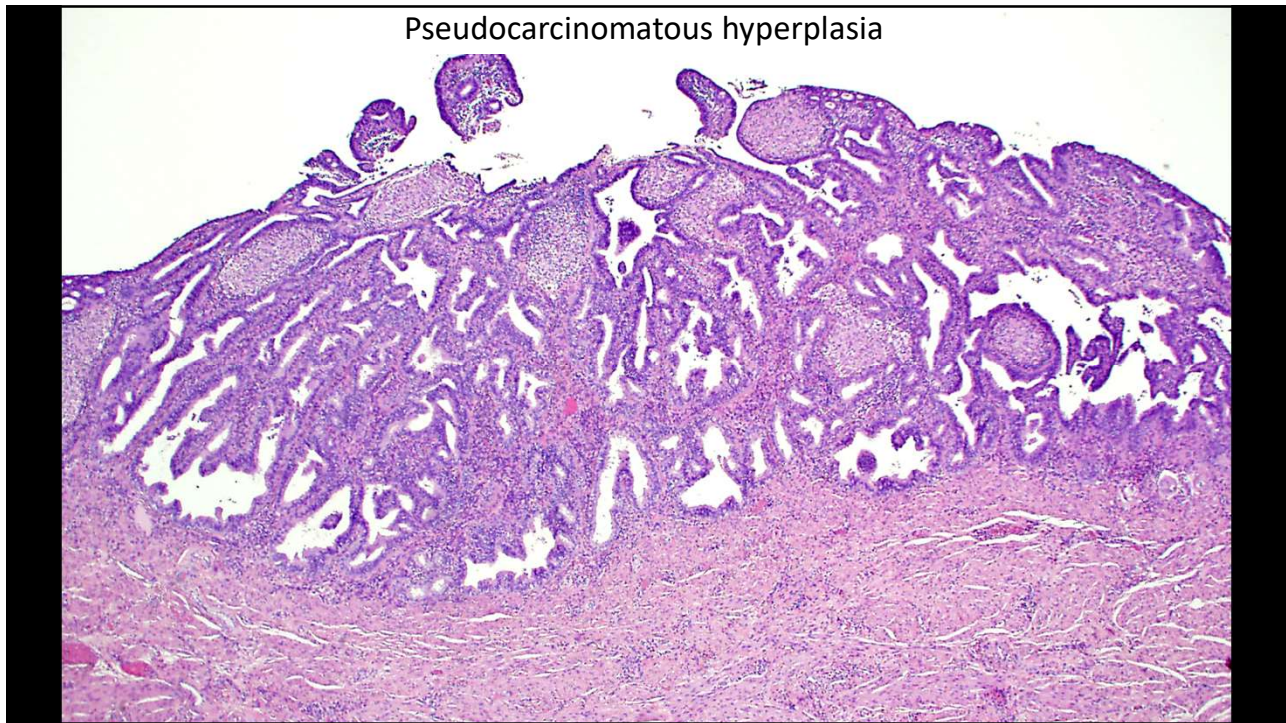
73



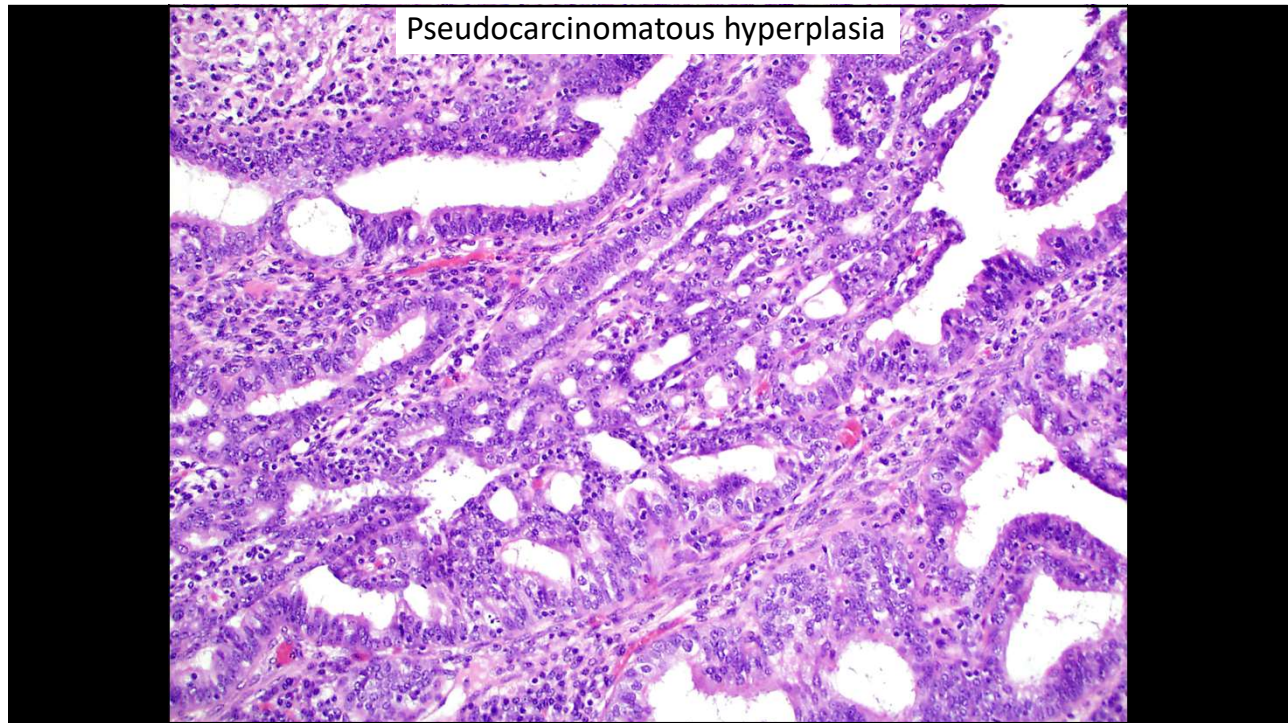
74



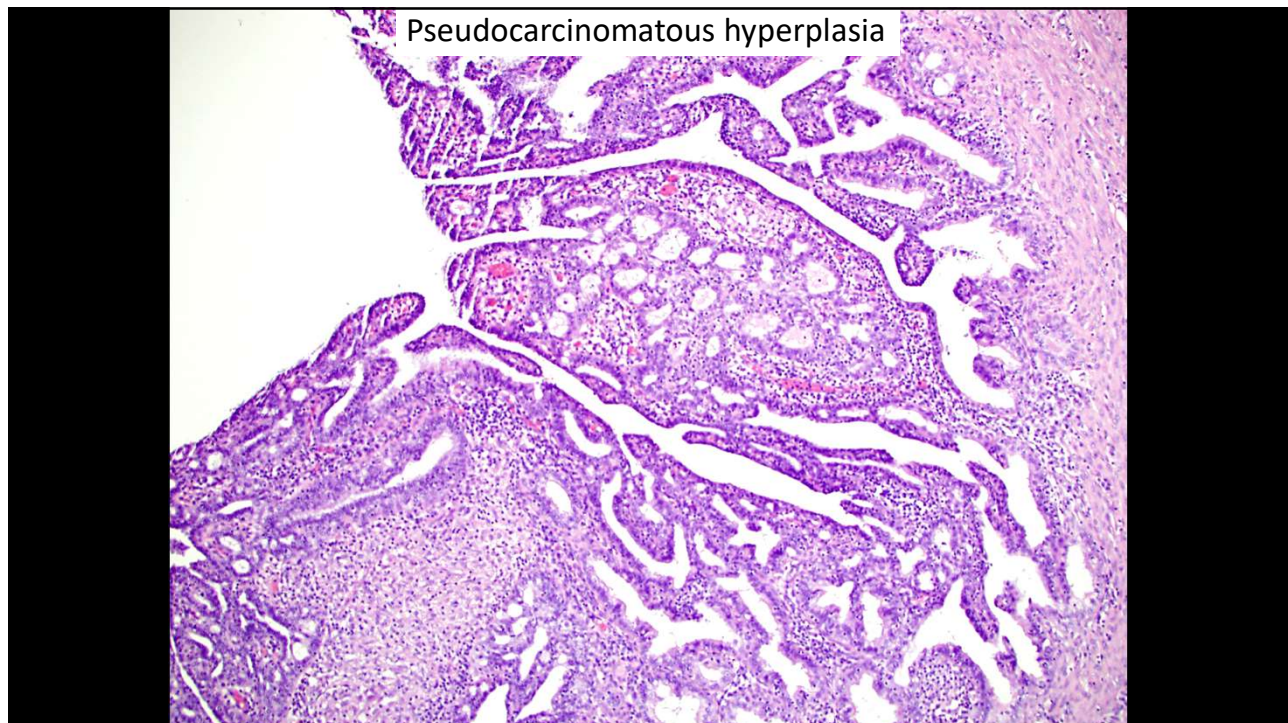
75



76

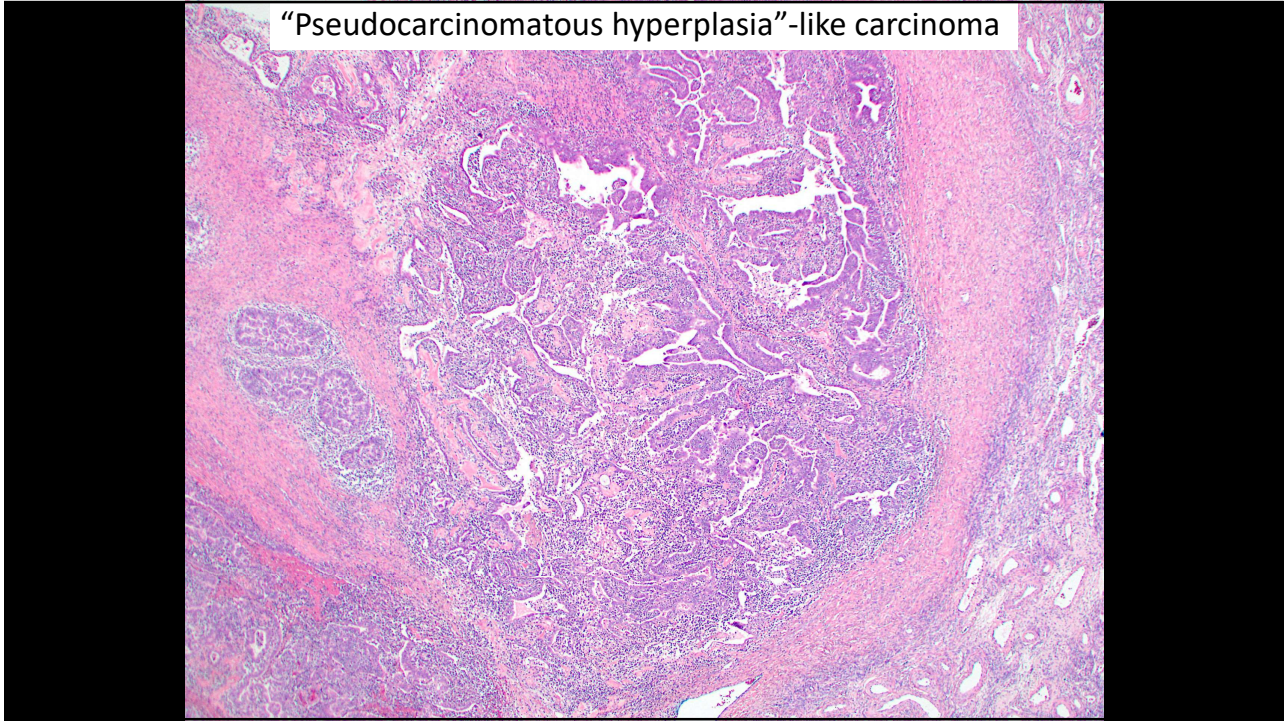


77



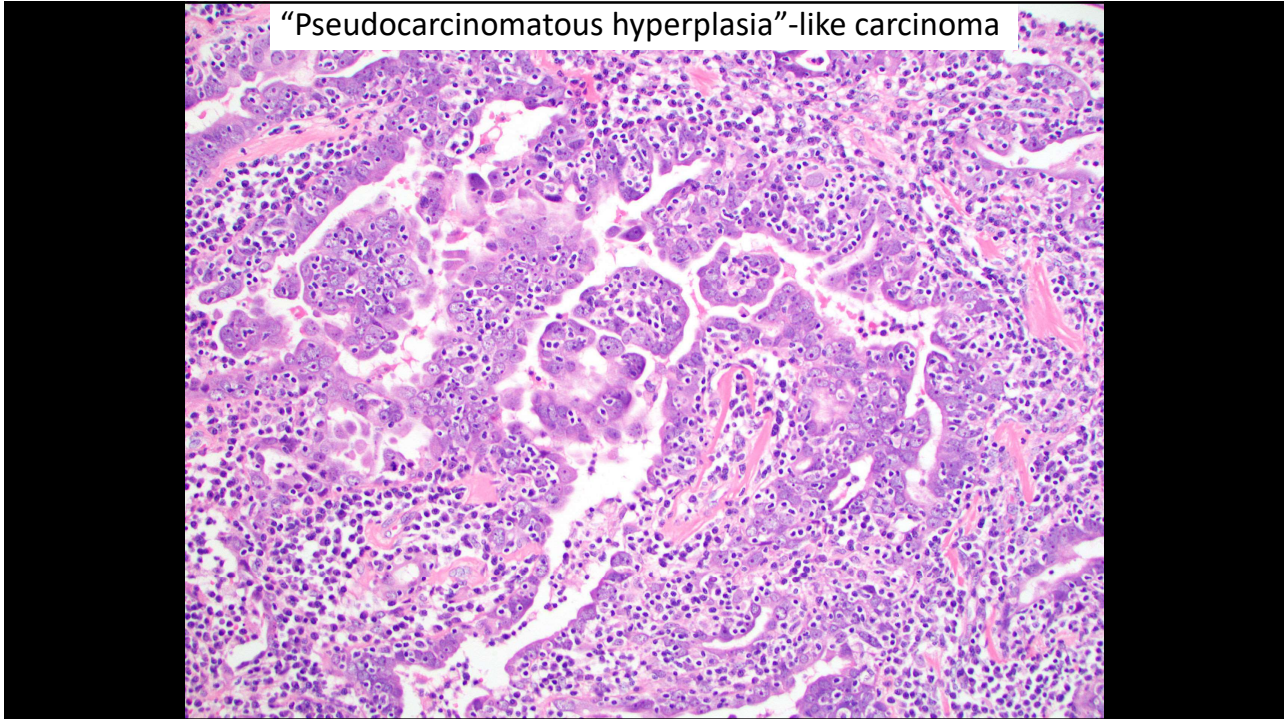
78

"Pseudocarcinomatous hyperplasia"-like carcinoma

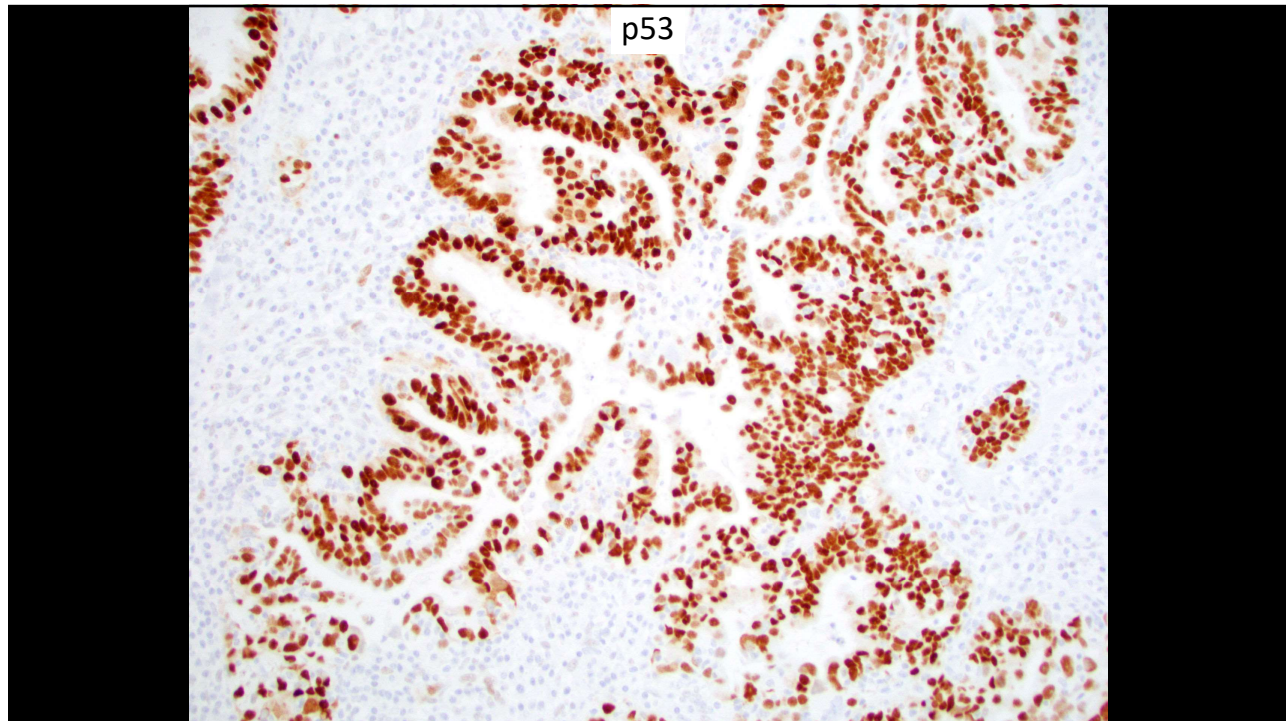


79

"Pseudocarcinomatous hyperplasia"-like carcinoma



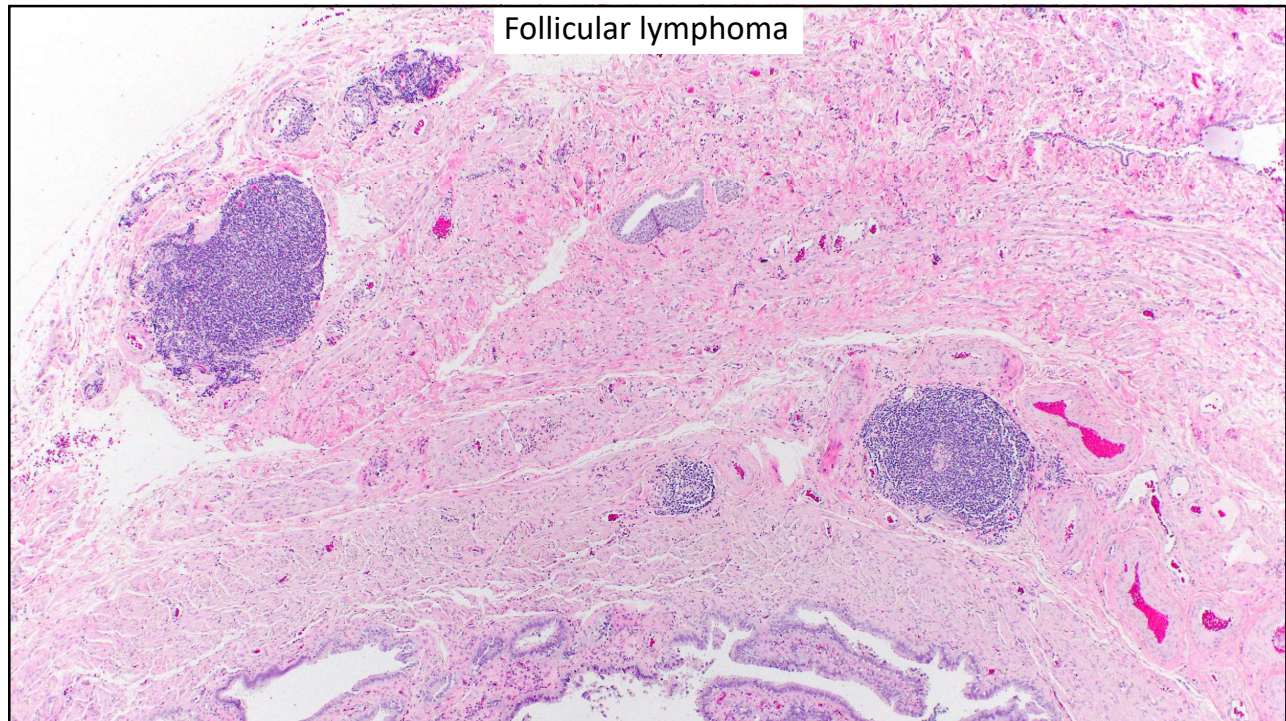
80



81

	Pseudocarcinomatous hyperplasia	High grade serous carcinoma
Age	Premenopausal	Postmenopausal
Atypia	Moderate	Severe
Mitotic figures	Yes, but no atypical forms	+++ , including atypical forms
p53 IHC staining pattern	Wild-type	Mutant
Architecture	No solid growth	May have solid growth

82



83

Granulomatous inflammation

- Infectious:
 - TB
 - Actinomyces
 - Leprosy
 - Schistosomiasis
- Non-infectious:
 - Crohn disease
 - Sarcoidosis
 - Foreign body reactions

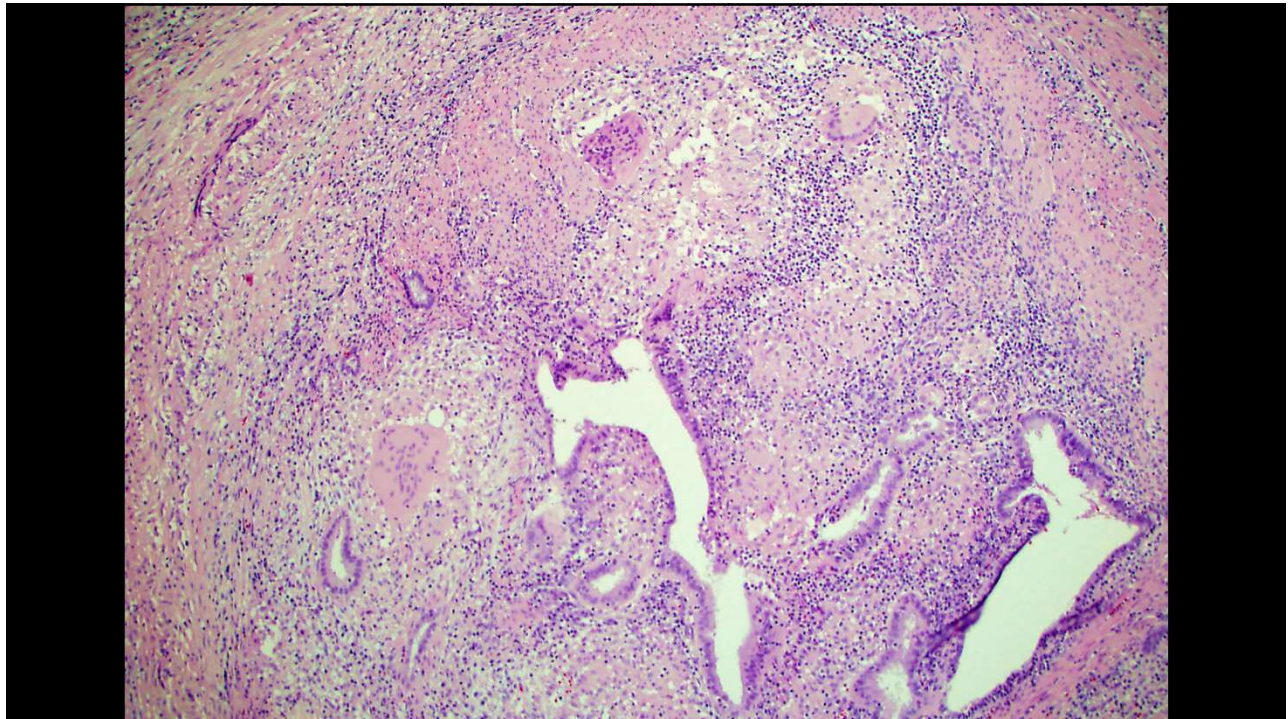
84

Granulomatous inflammation

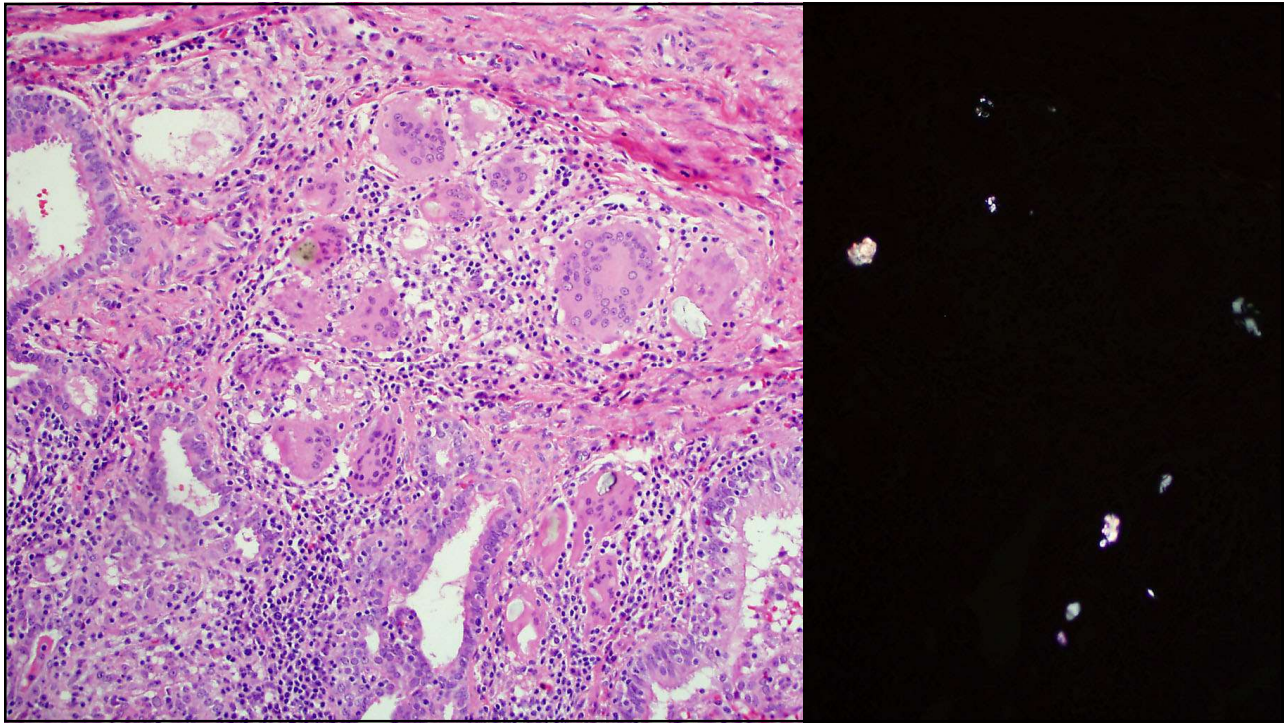
- Infectious:
 - TB
 - Actinomyces
 - Leprosy
 - Schistosomiasis
- Non-infectious:
 - Crohn disease
 - Sarcoidosis
 - Foreign body reactions

Approach:
History
Bug stains
Polarize

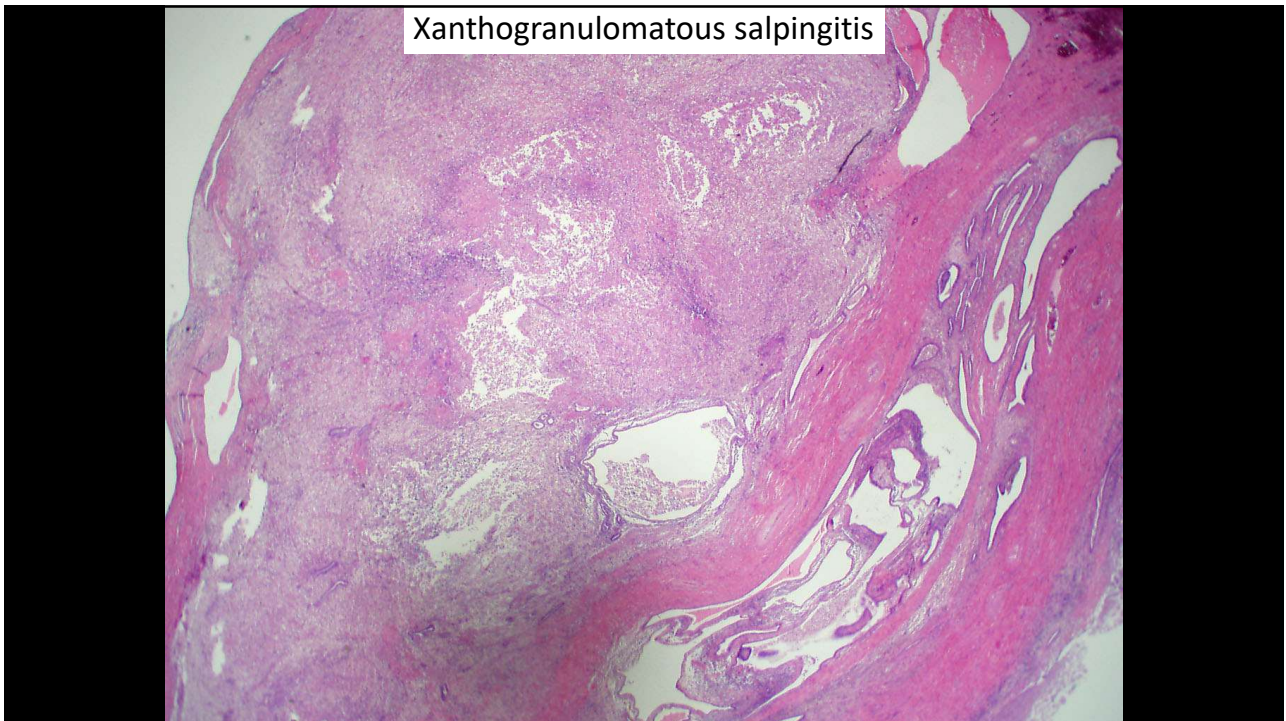
85



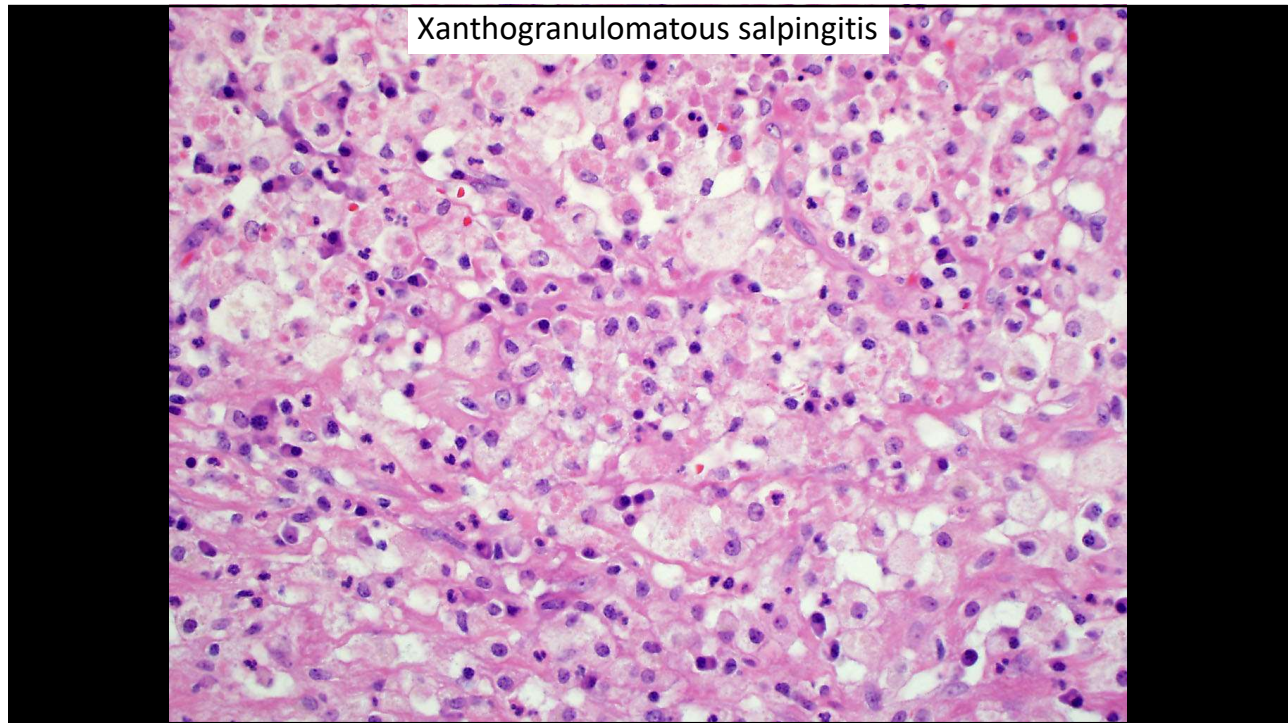
86



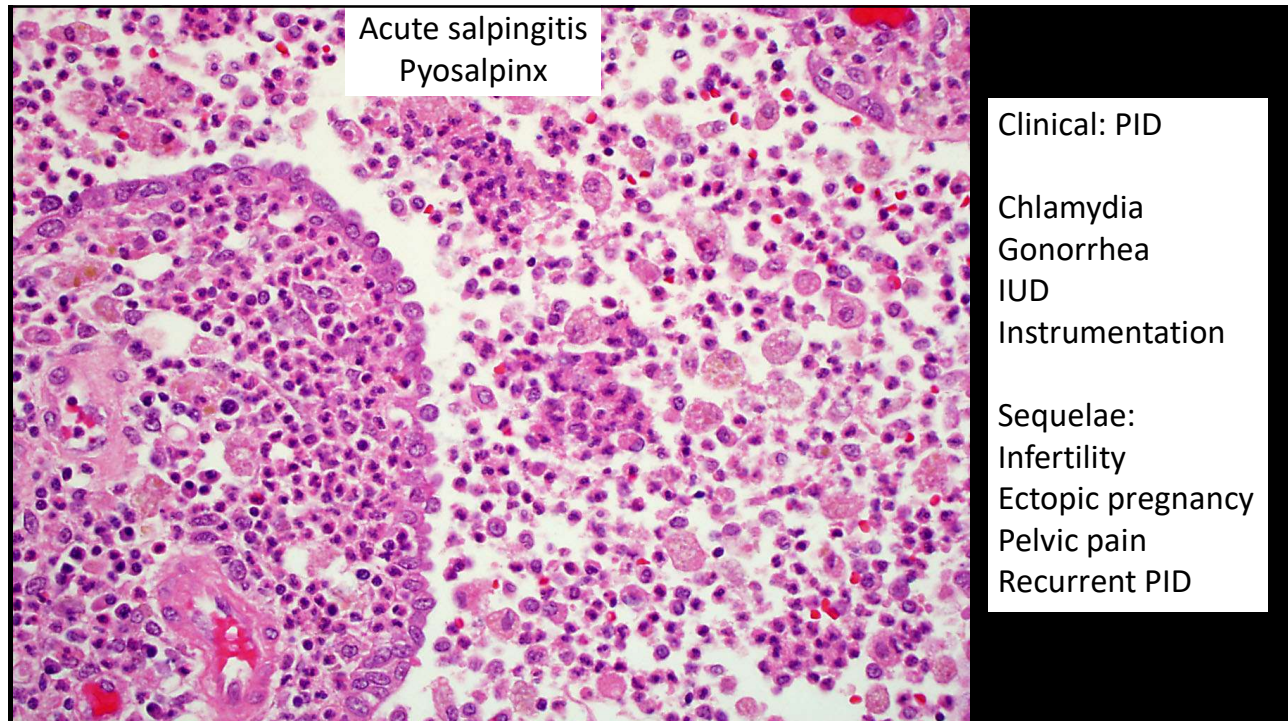
87



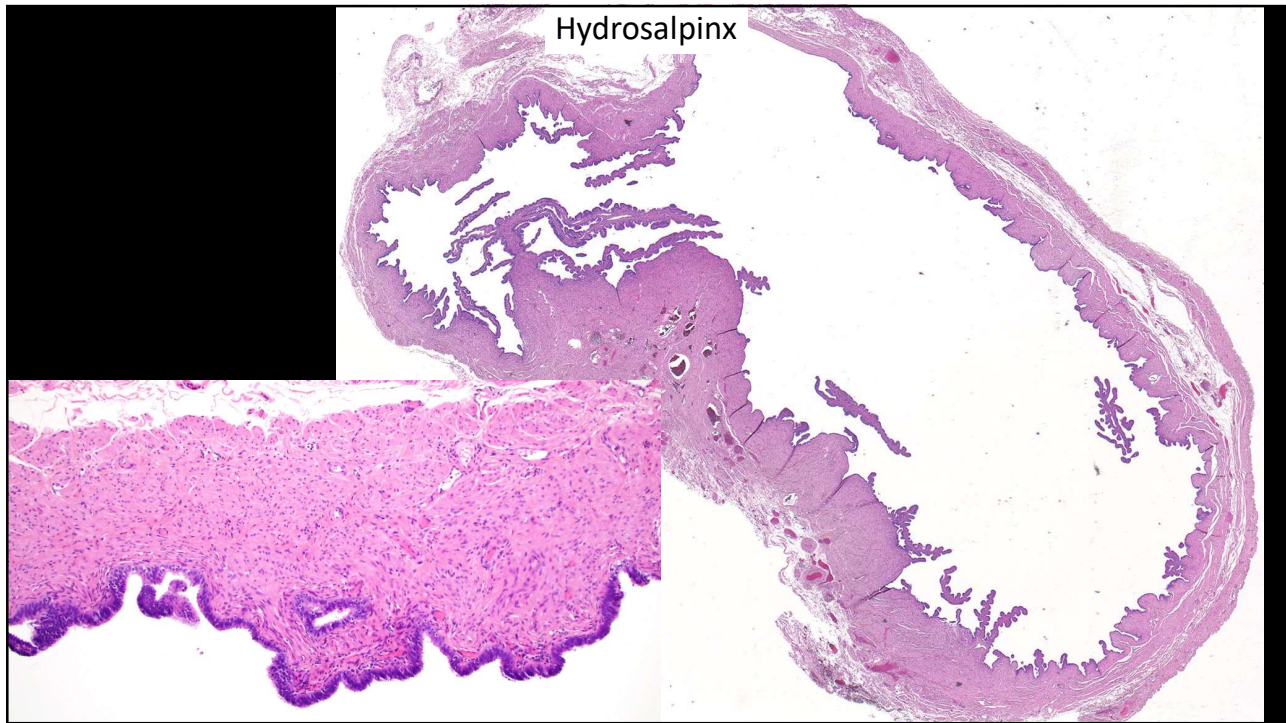
88



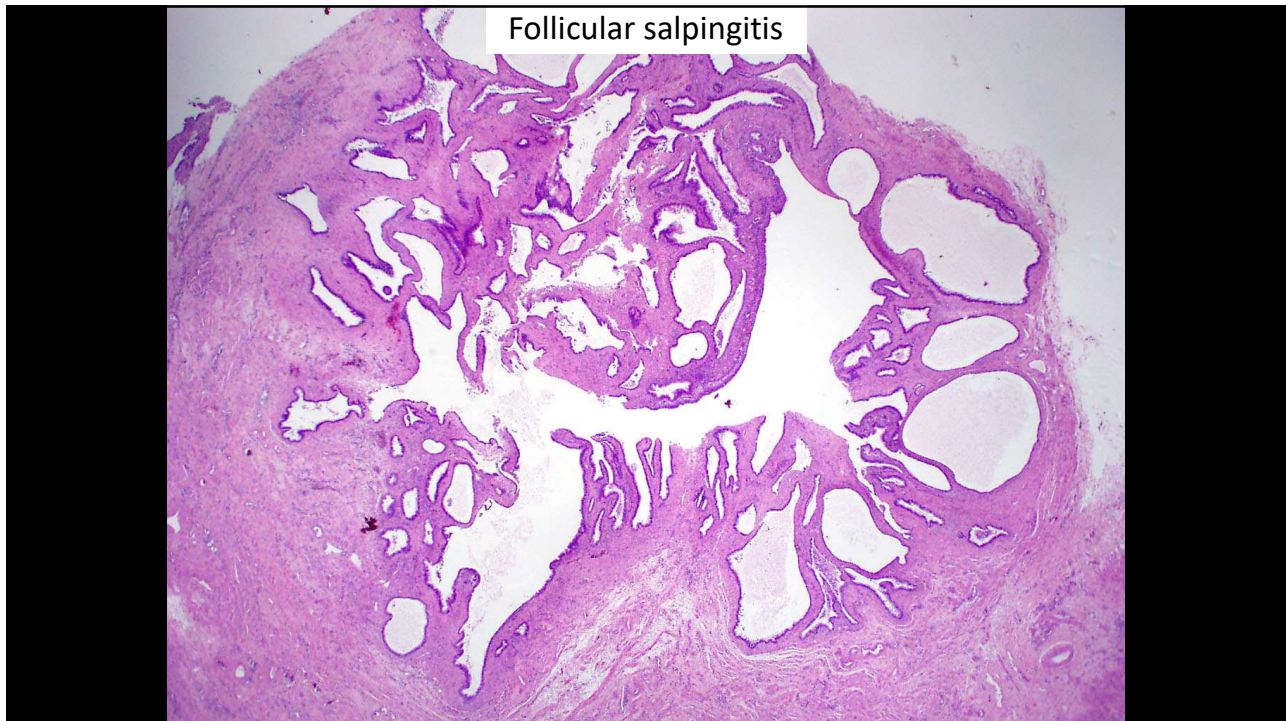89



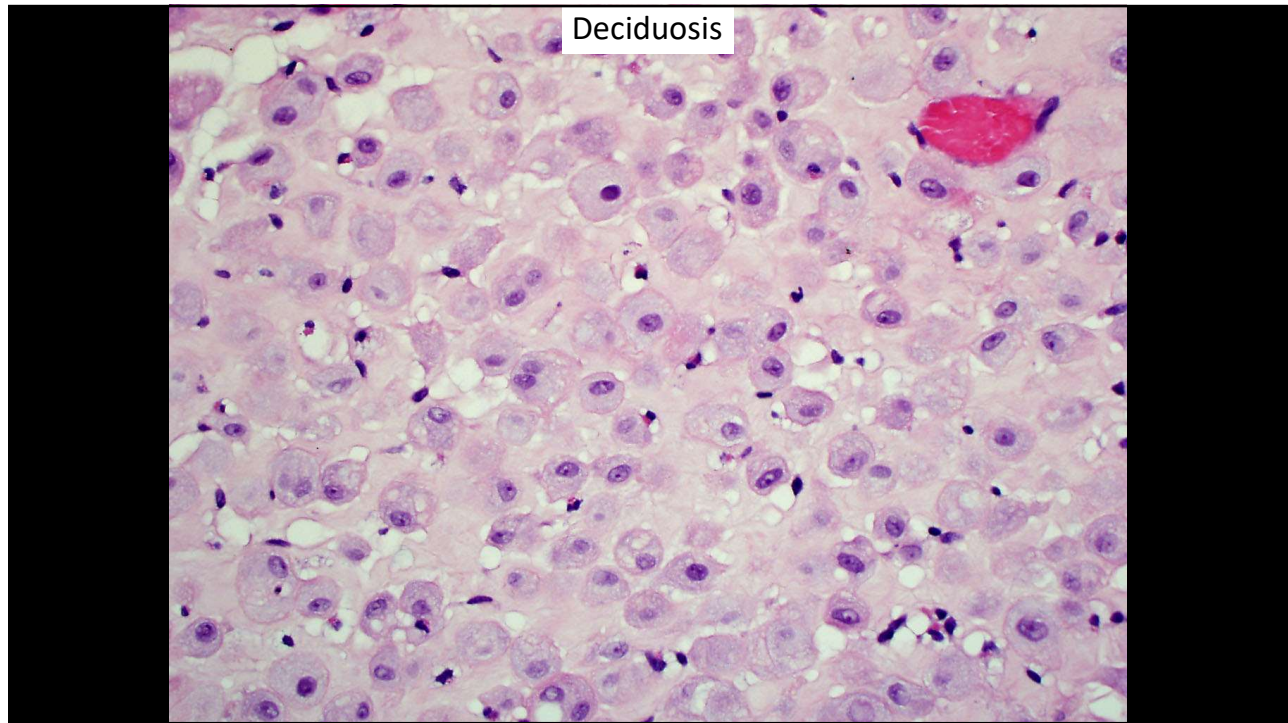
90



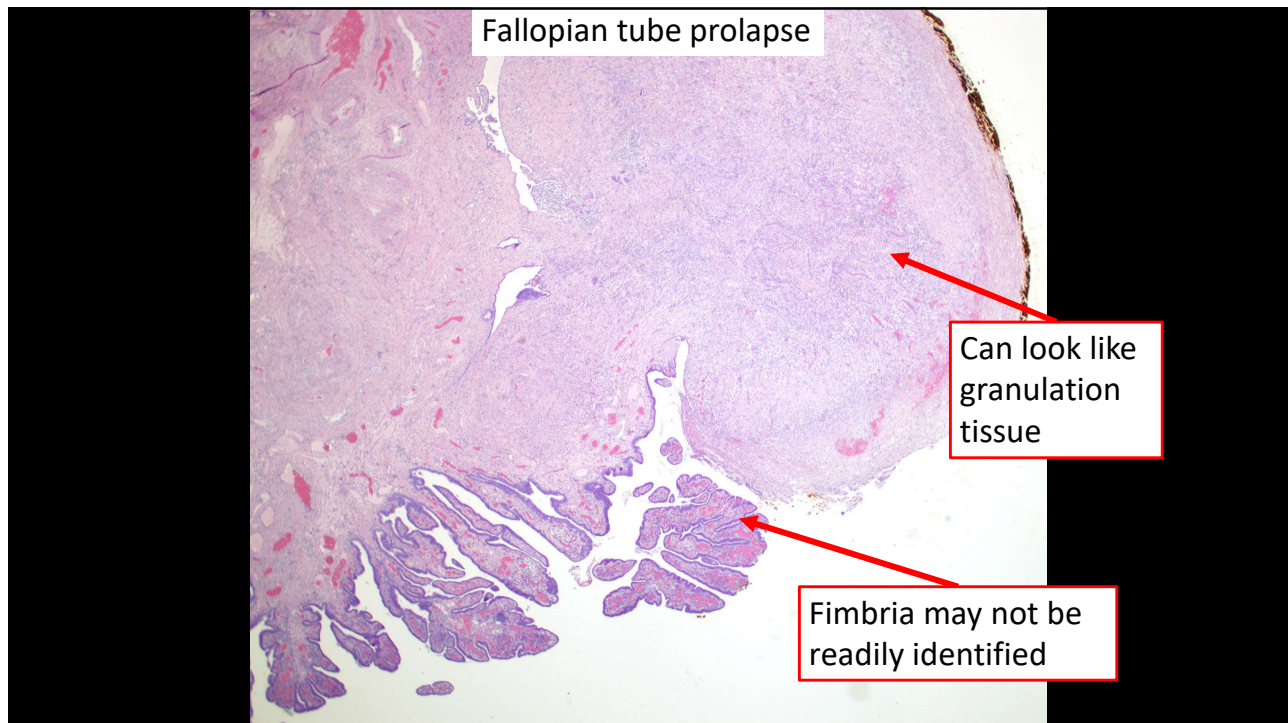
91



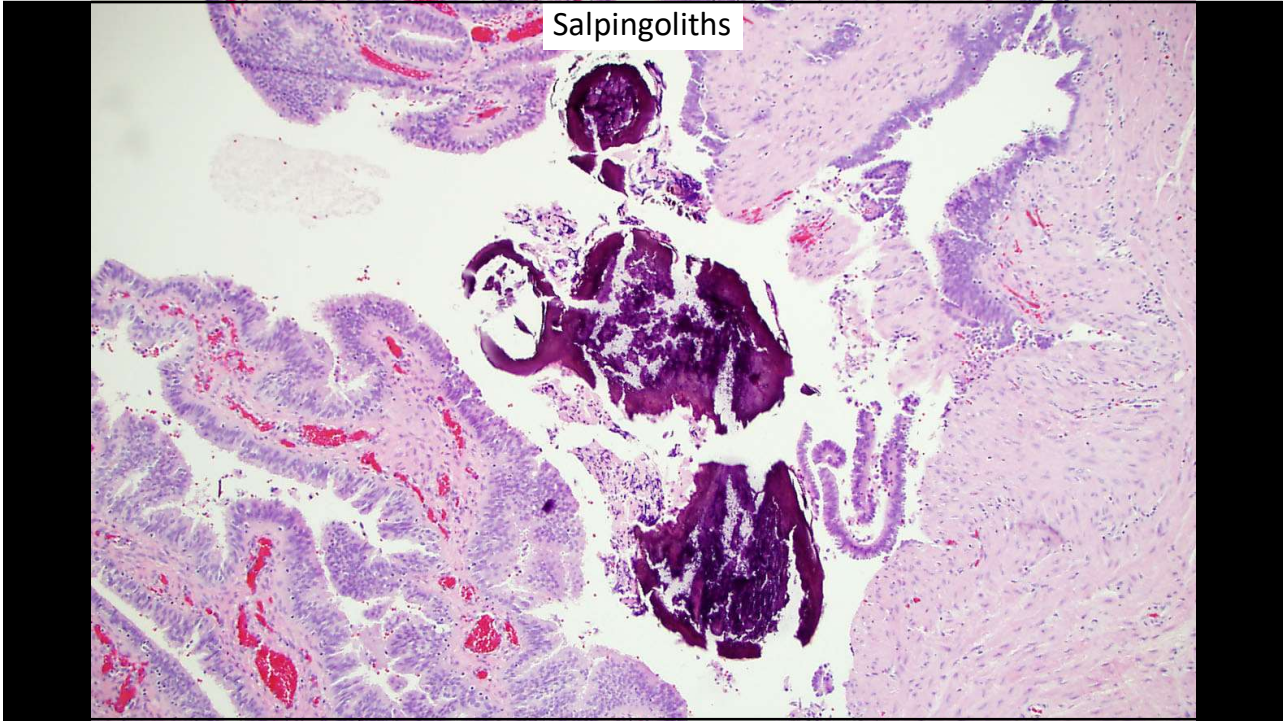
92



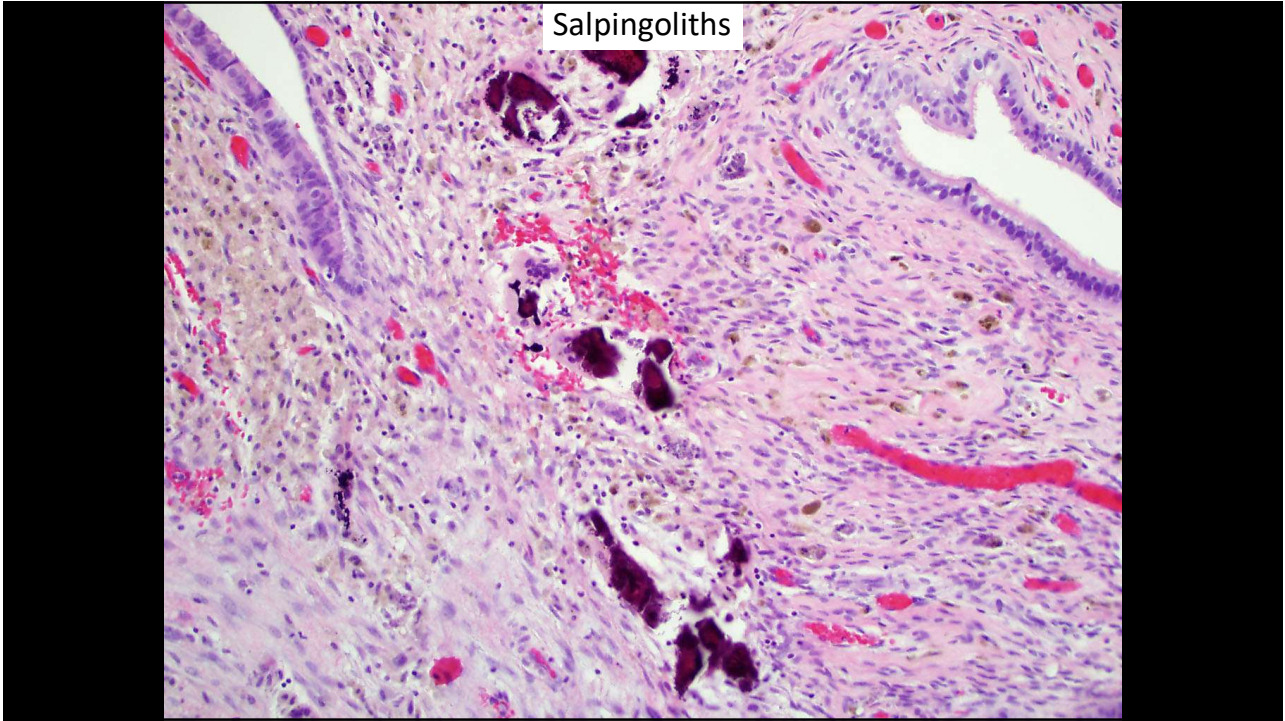
93



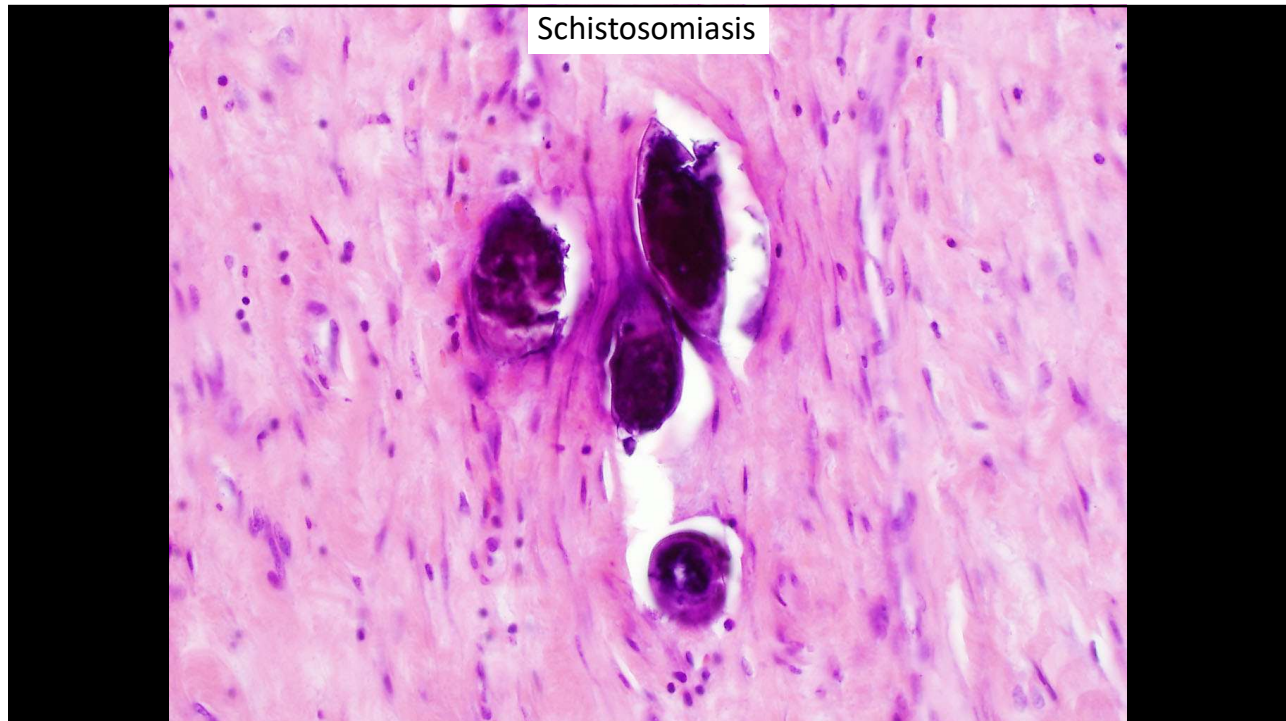
94



95



96

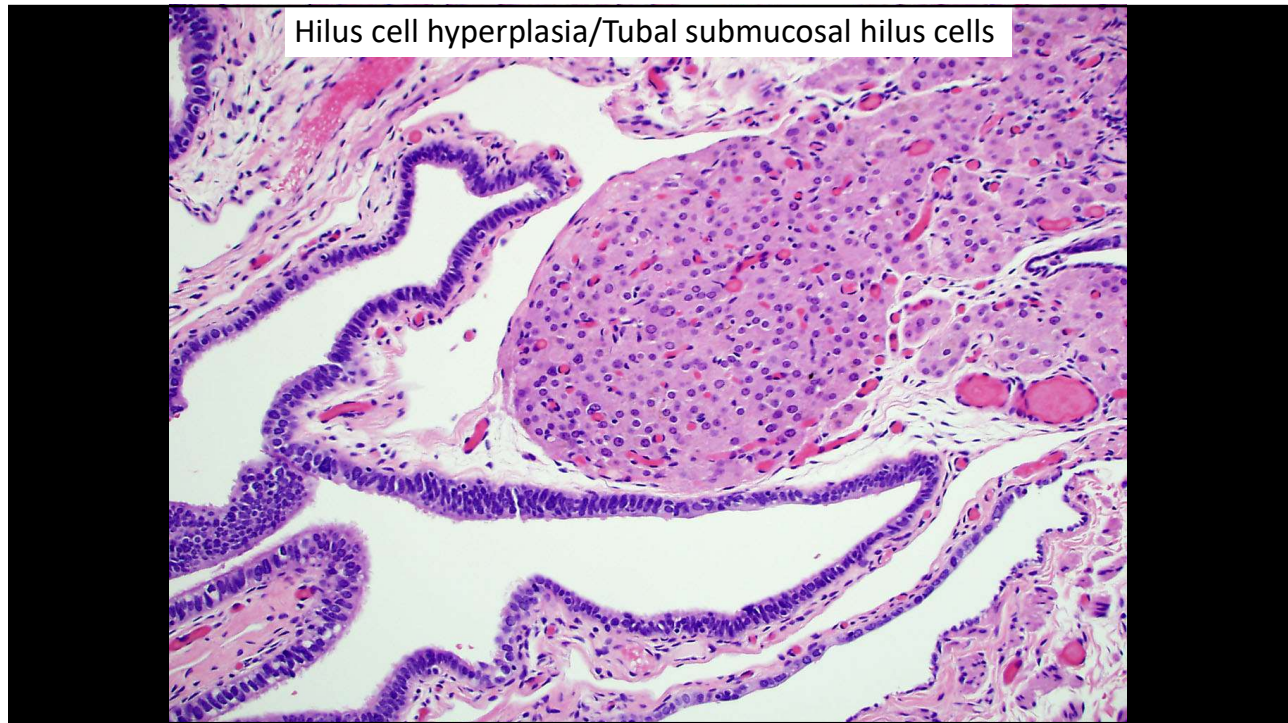


97

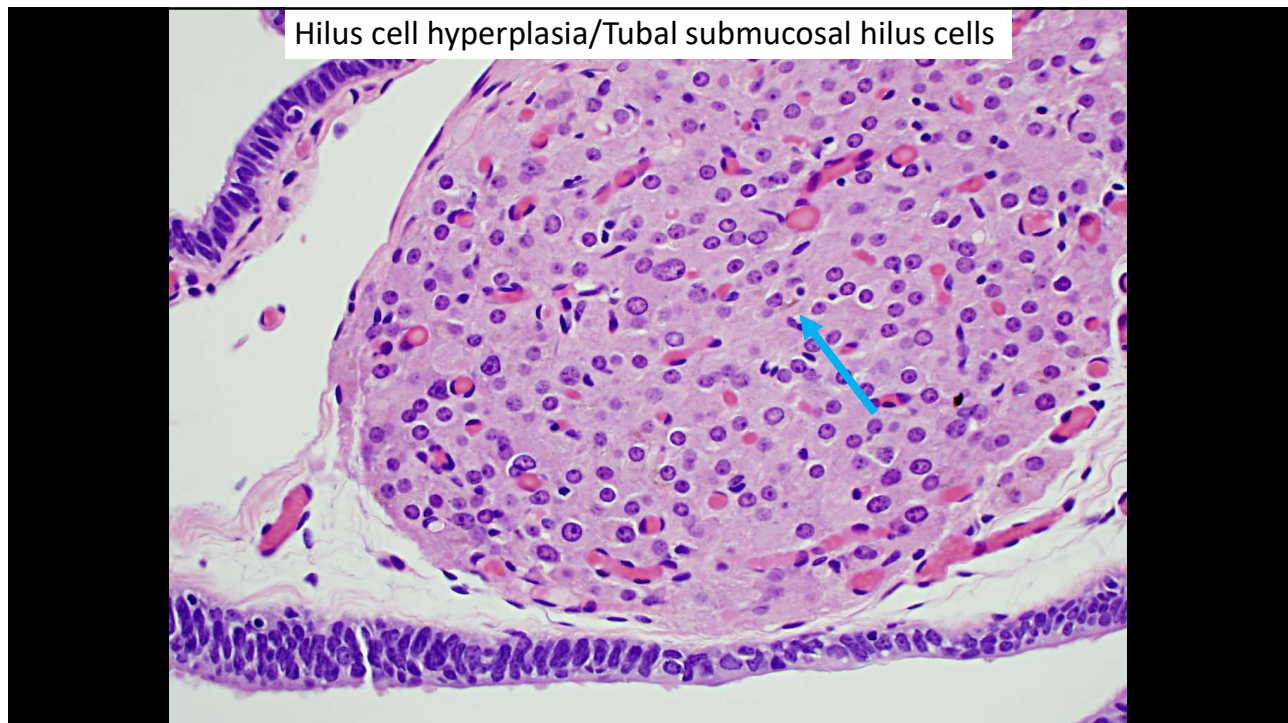
Sex-cord proliferations of the tube

- Submucosal Leydig/hilus cells
- Microscopic extraovarian sex cord proliferations

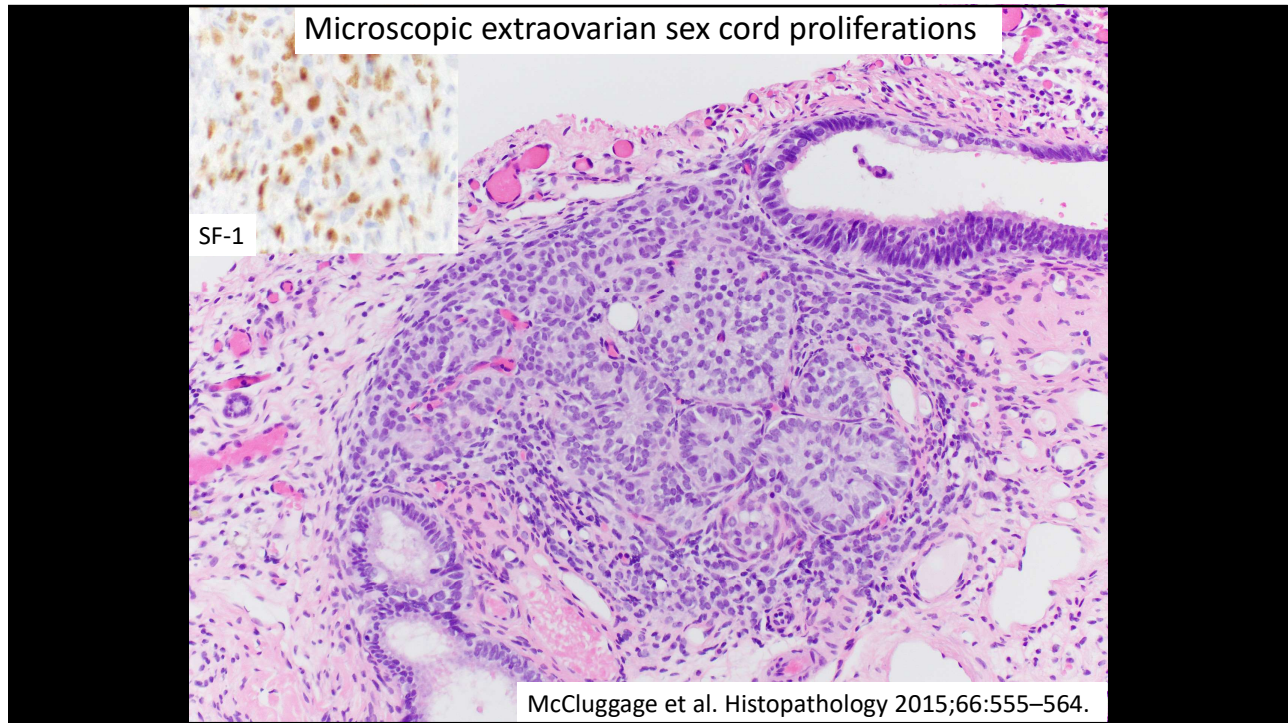
98



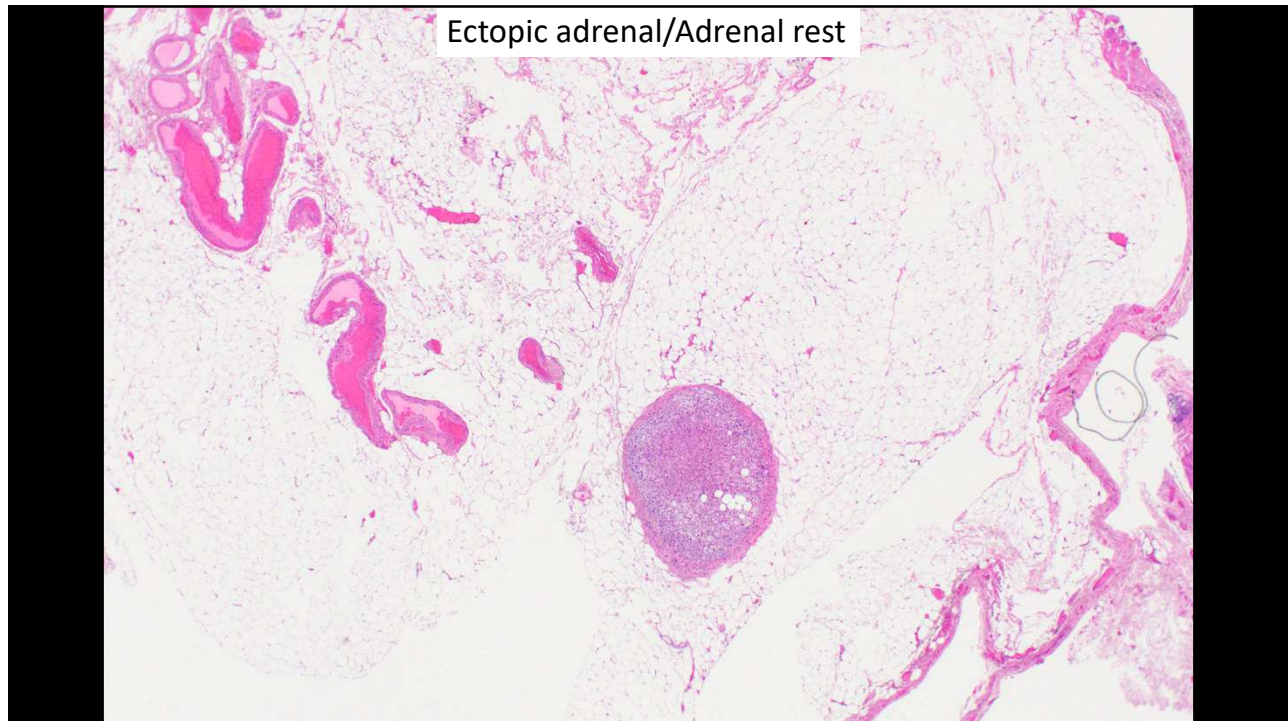
99



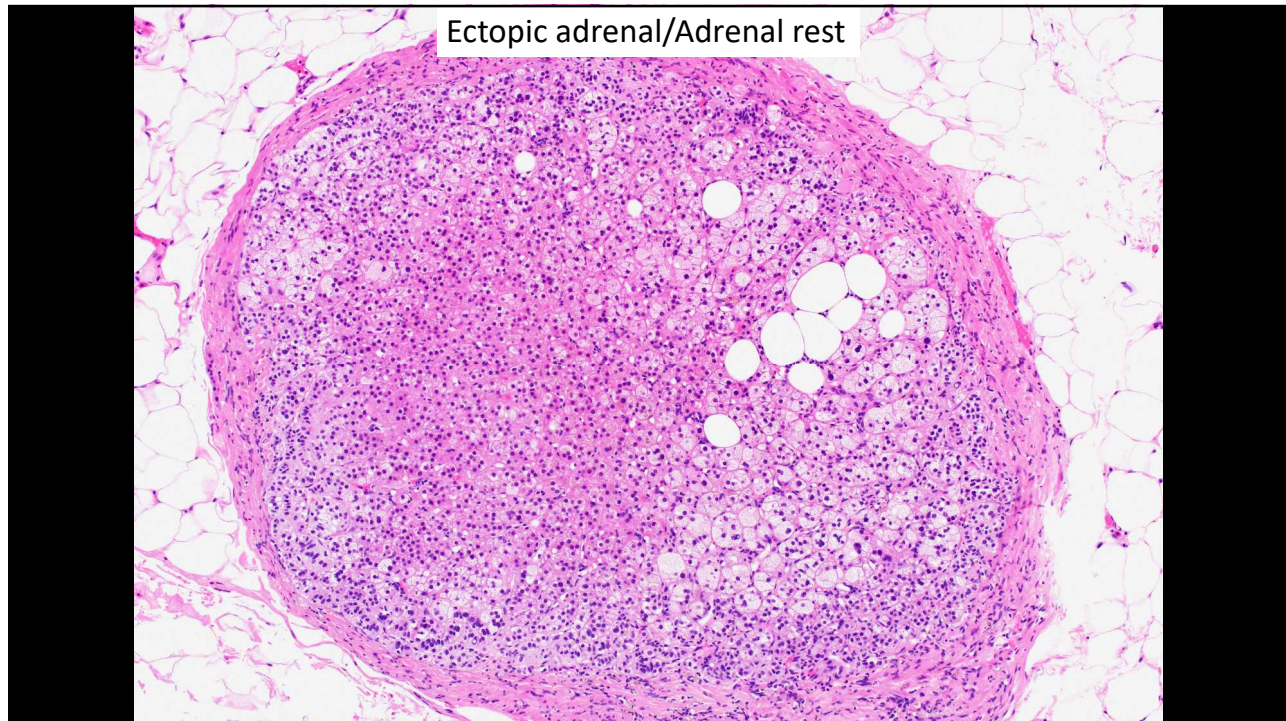
100



101



102



103


Take home points

- Carefully examine fallopian tubes using SEE-FIM protocol!
- Funny looking tubal proliferation?
 - p53 and MIB-1 IHC to exclude STIC
- Metastases can affect any part of the tube and mimic primary tumors
 - Keep it on your differential, especially if patient has a history of malignancy
- New entities
 - type II (endometrioid, β -catenin) SCOUTs... common if you look for them!
 - *STK11* adnexal tumors → Peutz-Jeghers in 50%

104

Questions?

dkolin@bwh.harvard.edu

 @DavidKolin